

ORIGINAL ARTICLE

Correlations of expressions of IMP3 and VEGF with stage of osteosarcoma, microvascular density and pulmonary metastasis

Xiangdi Kong¹, Lina Xu¹, Xiangxun Cao²

¹Department of Surgery, Linyi Central Hospital, Linyi, China. ²Department of Orthopedics, Linyi Central Hospital, Linyi, China.

Summary

Purpose: To detect protein expressions of insulin-like growth factor II messenger ribonucleic acid-binding protein 3 (IMP3) and vascular endothelial growth factor (VEGF) in osteosarcoma tissues and explore the relationships of protein expressions of IMP3 and VEGF with stage, microvessel density (MVD) and pulmonary metastasis of osteosarcoma patients.

Methods: Immunohistochemical staining was used to detect protein expressions of IMP3 and VEGF in 37 cases of osteosarcoma, and their correlations with stage, MVD and pulmonary metastasis of osteosarcoma patients were analyzed in combination with clinical data.

Results: Protein expressions of IMP3 and VEGF in osteosarcoma were significantly higher than those in normal tissues

adjacent to the tumor ($p < 0.05$, $p < 0.05$). The distribution of stage III in osteosarcoma patients with high protein expressions of IMP3 and VEGF increased. With the enhancement of protein expressions of IMP3 and VEGF, MVD elevated, the probability of pulmonary metastasis increased, and the survival time decreased markedly in osteosarcoma patients.

Conclusions: High expressions of IMP3 and VEGF are positively correlated with stage, MVD and pulmonary metastasis of osteosarcoma, and can be applied as potential indicators of the malignant degree of osteosarcoma and the prognosis of patients.

Key words: osteosarcoma; pulmonary metastasis; IMP3; VEGF

Introduction

As one of the most common primary malignant tumors that are prone to occur in people aged 10-30 years old, osteosarcoma is mainly detected in the metaphysis with active growth and characterized by relatively strong invasion and metastasis, which seriously endangers the health of the young population [1,2]. About 20% of osteosarcoma patients have pulmonary metastasis at presentation, and 85% die within 2 years after the diagnosis. The 5-year survival rate can reach 30-50% only after exposing to the most active treatment in time. Currently, there is no reliable and effective means of early diagnosis and treatment [3]. Therefore, finding out new reliable and effective treatment meth-

ods or approaches has always been an important subject in bone tumor studies.

Up to now, although chemotherapy drugs have been actively applied in clinic to delay or change the occurrence, location and time of metastasis, patients still have a 70-85% recurrence rate within one year. Studies have stated that metastasis is a biological characteristic of malignant tumors, which occurs in about 1/3 of osteosarcoma patients, with pulmonary metastasis being the most common one [4,5]. Moreover, for most patients with pulmonary metastasis, surgery is no longer applicable. Therefore, it is a pressing scientific challenge for researchers to explore the mecha-

Corresponding author: Xiangxun Cao, BM. Department of Orthopedics, Linyi Central Hospital, No. 17 Jiankang Rd, Yishui County, Linyi 276410, Shandong, China.
Tel: +86 0539-2250834, Email: toney203@126.com
Received: 15/09/2019; Accepted: 05/11/2019

nisms of occurrence, development, invasion and metastasis of osteosarcoma. With the progress of molecular biological technology, scholars in China and foreign countries have conducted some studies on osteosarcoma at the molecular level, however, further investigations are still needed due to the complex pathogenesis of osteosarcoma [6].

In recent years, it has been denoted in studies that insulin-like growth factor II messenger ribonucleic acid-binding protein 3 (IMP3) is largely involved in the regulation of tumor occurrence, development and other processes [7,8]. It is an insulin-like growth factor RNA binding protein located on human chromosome 7 and is transcribed and translated from IGF2BP3 gene. Recent studies have discovered that IMP3 is not expressed in healthy human tissues, but has a notably up-regulated expression in pancreatic cancer, bladder cancer and liver cancer, which indicates a poor prognosis. Yet, there are few reports on its role in osteosarcoma [9-11].

Another study result pointed out that angiogenesis changes abnormally in the occurrence and metastasis of tumors. Tumor cells enter the circulatory system along with new blood vessels and then transfer to other organs. The tumor will further deteriorate due to the nourishing effect of new blood vessels [12]. Among multiple factors promoting angiogenesis, vascular endothelial growth factor (VEGF) is the most crucial regulator with the most evident effect [13]. A study has proved that VEGF expression is an independent prognostic factor for malignant tumor patients, but there are few studies on the relationship of VEGF expression with microvessel density (MVD) and pulmonary metastasis [14].

As a result, this study collected tissue sections from 37 osteosarcoma patients in our hospital, and detected the protein expression levels of IMP3 and VEGF in osteosarcoma patients with and without pulmonary metastasis by immunohistochemical staining, to explore and determine the correlations of expressions of IMP3 and VEGF with stage, MVD and pulmonary metastasis of osteosarcoma. The report is as follows.

Methods

Specimen source and clinical data

Specimens were collected from 37 recorded cases of osteosarcoma in the oncology pathology department of our hospital from June 2013 to June 2016. Besides, 9 specimens of corresponding paraneoplastic tissues (over 5 cm away from the cutting edge of tumor tissues) were taken. Specimens excised during the surgery and confirmed by clinical pathology as osteosarcoma were immersed in 4% paraformaldehyde for fixation, conventionally embedded in paraffin and serially sectioned with a thickness of 5 μ m. All patients were never treated with

radiotherapy or chemotherapy, among whom 21 were male and 18 were female. The onset age was in the range of 9-65 years old, with an average age of (23.8 \pm 14.6) years old. Pulmonary metastasis occurred in 15 cases. The Ethics Committee of our hospital approved this project and all patients signed the informed consent.

Reagents and methods

Rabbit anti-IMP3 and VEGF antibodies were purchased from Beijing Bioss Biotech Co., Ltd. (Beijing, China). The universal streptomycin-biotin-peroxidase (SP) test kit was purchased from Beijing Solarbio Science and Technology Co., Ltd. (Beijing, China). SP immunohistochemical method was adopted to detect the expressions of IMP3 and VEGF in osteosarcoma and adjacent tissues. The working concentration of IMP3 and VEGF was 1: 100. According to the instructions, the slices were dehydrated in xylene and ethanol, endogenous enzymes were inactivated with the help of 3% H₂O₂ solution, confining liquid was added, IMP3 and VEGF primary antibodies were incubated respectively. After washing with phosphate buffer saline (PBS) solution, goat anti-rabbit IgG working solution was added, and incubation was carried out for 20 min. Then incubation with streptavidin-PDO working solution for 30 min and diaminobenzidine (DAB) coloration were performed, hematoxylin was added dropwise to dye the nuclei, and the staining was observed under a microscope.

Determination of immunohistochemical results

The results were assessed based on the staining intensity and the quantity of positive cells. Scoring according to the staining intensity of cells: colorless (0 point), weakly positive (1 point), moderately positive (2 points) and strongly positive (3 points). The number of positive cells in 10 high power fields was randomly observed and counted. Scoring based on the number of positive cells: <5% (0 point), 6-25% (1 point), 26-50% (2 points), 51-75% (3 points) and >75% (4 points). After reviewing the above two indicators, statistics and Σ pi scoring, the total score <2 points was regarded as negative and \geq 2 points as positive.

Follow-up

After treatment, all of the 37 patients received regular outpatient review or telephone contact to collect data, with a follow-up rate of 100%. The disease progression and survival time of patients were recorded in detail. The survival time (month) was from the date of diagnosis of osteosarcoma to the date of death or final follow-up.

Statistics

The correlation analysis of IMP3 and VEGF and clinicopathological features of osteosarcoma was conducted by χ^2 and Fisher exact test. The presence or absence of pulmonary metastasis and survival time of patients were estimated by Kaplan-Meier survival curves and tested by Log-rank. All data were analyzed by Statistical Product and Service Solutions (SPSS) 15.0 software (SPSS Inc., Chicago, IL, USA), and $p < 0.05$ suggested that the difference was statistically significant.

Results

Protein expressions of IMP3 and VEGF in osteosarcoma and adjacent tissues

The results of immunohistochemical staining method are shown in Figure 1A, 1B, the protein expressions of IMP3 and VEGF in osteosarcoma are located in the cytoplasm, and if IMP3 and VEGF are expressed, cytoplasm will be stained yellowish-brown. Statistics displayed that the expression of IMP3 in osteosarcoma tissues was higher than that in adjacent tissues ($p < 0.05$) (Table 1). Similarly, the protein expression of VEGF in osteosarcoma tissues was higher than that in adjacent tissues ($p < 0.05$) (Table 2).

Relationships of protein expressions of IMP3 and VEGF with the stage of osteosarcoma

In this study, Enneking surgical staging system used in bone tumors was chosen, 6 cases were in low-grade malignant stage (stage I) with the protein expression of IMP3 positive in 1 case and negative in 5 cases and that of VEGF positive in 5 cases and negative in 1 case, 21 cases were in high-grade malignant stage (stage II) with the pro-

tein expression of IMP3 positive in 19 cases and negative in 2 cases and that of VEGF positive in 20 cases and negative in 1 case, and 10 cases were in distant metastasis stage (stage III) with the protein expressions of IMP3 and VEGF positive in all of them. Chi-square partition results showed that there were statistical significances between stage II and stage III in terms of protein expressions of IMP3 and VEGF ($p < 0.05$, $p < 0.05$), as shown in Table 3 and Table 4. The above results indicate that high expressions of IMP3 and VEGF are closely related to the stage of osteosarcoma.

Relationships of protein expressions of IMP3 and VEGF with MVD

The number of microvessels in the vascular density areas under 5 high power fields was counted, and the average value was MVD. In 37 osteosarcoma tissue specimens, the protein expression of IMP3 was positive in 34 cases and negative in 3 cases, and the protein expression of VEGF was positive in 35 cases and negative in 2 cases. With the enhancement of MVD, the positive expression proportions of IMP3 and VEGF were remarkably elevated ($p < 0.05$, $p < 0.05$). The correlation analysis

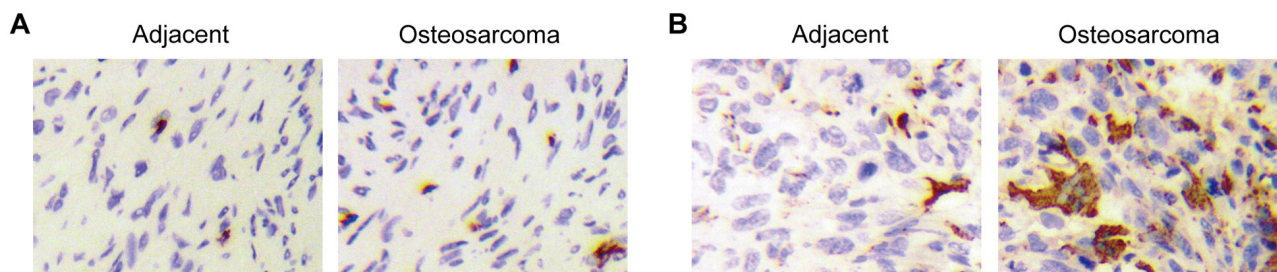


Figure 1. Staining results of IMP3 and VEGF in osteosarcoma and adjacent tissues (40 \times). **(A)** Expression of IMP3, **(B)** Expression of VEGF.

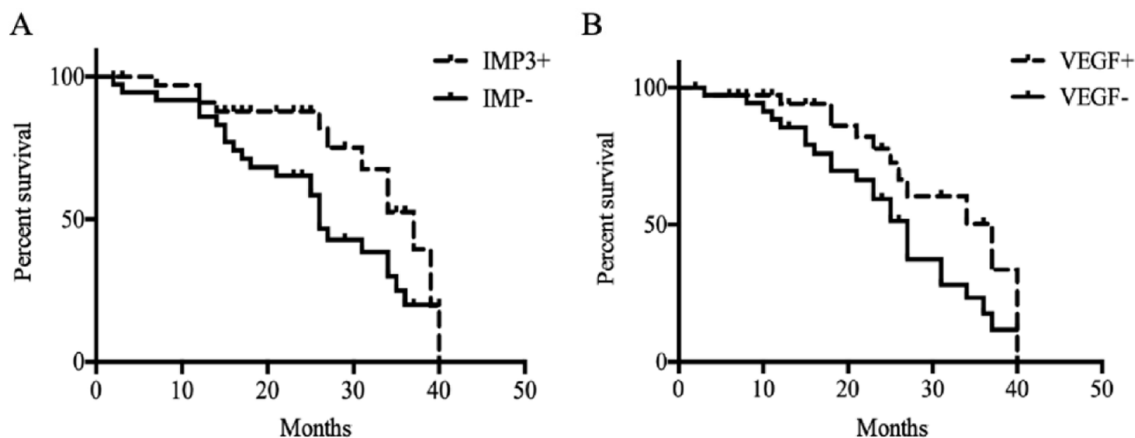


Figure 2. Relationships of protein expressions of IMP3 and VEGF with overall survival time of osteosarcoma patients. **(A)** The effect of expression of IMP3 on the survival time of osteosarcoma patients ($p > 0.05$). **(B)** The effect of expression of VEGF on the survival time of osteosarcoma patients ($p > 0.05$).

results are shown in Table 5 and Table 6, indicating that high expressions of IMP3 and VEGF are closely related to MVD.

Relationships of protein expressions of IMP3 and VEGF with pulmonary metastasis

Before the operation, the positive expression rates of IMP3 and VEGF were 76.92% and 72.72% respectively in patients with pulmonary metastasis, which were higher than those in patients without pulmonary metastasis (29.17% and 30.77%, respectively) ($p < 0.05$, $p < 0.05$). In the follow-up period, pulmonary metastasis occurred respectively in 5 cases with IMP3 expression and no pulmonary metastasis and 6 cases with VEGF expression and without pulmonary metastasis or before the operation. The pulmonary metastasis rate was respec-

tively 71.43% and 60.00%, which was higher than that of patients without pulmonary metastasis and without the expression of IMP3 or VEGF before operation (29.41% and 33.33%, respectively) ($p < 0.05$, $p < 0.05$) (Table 7).

Relationships of protein expressions of IMP3 and VEGF with overall survival time of osteosarcoma patients

The data of 37 patients were complete, and all patients were followed up. Kaplan-Meier survival curves exhibited that the 3-year survival rate of patients with IMP3 (+) [26.47% (9/34)] was significantly lower than that of patients with IMP3 (-) [66.67% (2/3)], ($p < 0.05$), as shown in Figure 2A. The 3-year survival rate of patients with VEGF (+) was significantly lower than that of patients with

Table 1. Expression of IMP3 in osteosarcoma and adjacent tissues

Group	Negative	Positive rate (%)	χ^2	p
Osteosarcoma tissues (n=37)	3	91.89	18.47	< 0.05
Adjacent tissues (n=9)	8	11.11		

Table 2. Expression of VEGF in osteosarcoma and adjacent tissues

Group	Positive	Negative	Positive rate (%)	χ^2	p
Osteosarcoma tissues (n=37)	35	2	94.59	16.38	< 0.05
Adjacent tissues (n=9)	2	7	22.22		

Table 3. Protein expression of IMP3 in osteosarcoma with different Enneking stages

Group	n	IMP3 (+)	IMP3 (-)	Positive rate	p
Osteosarcoma	37	34	3	91.89 %	
I	6	5	1	83.33 %	
II	21	19	2	90.48 %	
III	10	10	0	100.00 %	0.016

Table 4. Protein e of VEGF in osteosarcoma with different Enneking stages

Group	n	VEGF (+)	VEGF (-)	Positive rate	p
Osteosarcoma	37	35	2	94.59 %	
I	6	5	1	83.33 %	
II	21	20	1	95.24 %	
III	10	10	0	100.00 %	0.018

Table 5. Relationship between the protein expression of IMP3 and MVD in osteosarcoma

IPM3	n	MVD	r	p
Positive	34	57.34±6.98	0.243	<0.05
Negative	3	34.15±4.12		

Table 6. Relationship between the protein expression of VEGF and MVD in osteosarcoma

VEGF	n	MVD	r	p
Positive	35	63.71±7.04	0.213	<0.05
Negative	2	29.48±3.15		

Table 7. Relationships of protein expressions of IMP3 and VEGF with pulmonary metastasis in osteosarcoma

Group	n	IMP3 (+)	IMP3 (-)	n	VEGF (+)	VEGF (-)
Metastasis (-)	24	7	17	26	8	18
Metastasis (+)	13	10	3	11	8	3

VEGF (-) (22.86 % (8/35) vs. 100.00% (2/2), $p < 0.05$), as shown in Figure 2B. This indicates that IMP3 and VEGF are factors that affect the prognosis of osteosarcoma patients.

Discussion

Osteosarcoma is a highly metastatic malignant tumor with an extremely high recurrence rate and poor prognosis, accounting for 25% of bone tumors. Osteosarcoma is the most popular malignant tumor in pediatric orthopedics, with a proportion of nearly 5% of pediatric tumors. Its main pathological process is that osteoblast mesenchymal cells produce bone or bone-like tissues. Clinically, it majorly manifests as pain, local swelling, claudication caused by limb pain, amyotrophy and systemic deterioration due to metastasis in severe cases [15]. The main clinical diagnostic bases include clinical manifestations, imaging examination, tissue biopsy and so on. At present, the treatment methods for osteosarcoma are composed of surgical resection, adjuvant chemotherapy, interventional therapy, as well as cellular immunotherapy and gene therapy, but the clinical effects need to be further confirmed [16]. Recent years have witnessed an improvement in the treatment of osteosarcoma, but there are still some challenges. New approaches of prevention, diagnosis and treatment of osteosarcoma still require to be uncovered in order to provide the best-individualized treatment regimen for patients.

IMP3 protein is a K homologous protein that is considered to be overexpressed in cancer tissues, which is closely related to the occurrence and development of malignant tumors. A study suggested that IMP3 plays an important role in the proliferation, metastasis and invasion of tumor cells. Dahlem et al. [17] found that in gallbladder cancer, patients with high expression of IMP3 protein tend to have a poor prognosis. Hui et al. [18] pointed out that the expression of IMP3 is notably enhanced in 44 patients followed up in the study

of malignant peritoneal mesothelioma, suggesting that IMP3 can serve as a prognostic factor for patients with malignant peritoneal mesothelioma. Studies mentioned above have proven that IMP3 is vital to malignant tumors. Moreover, VEGF, the most important factor in angiogenesis, plays an irreplaceable role in angiogenesis. VEGF can promote the proliferation of endothelial cells, cause irreversible neovascularization in tumor tissues, and stimulate the continuous growth and metastasis of tumors. As the tumor volume enlarges, the density of peripheral blood vessels raises, greatly increasing the possibility of tumor metastasis. Liu et al. [19] discovered that the expressions of cysteine-rich protein 61 (Cyr61) and VEGF are remarkably up-regulated in 84 patients with osteosarcoma. The survival time turned out to be shortened if Cyr61 and VEGF are positively expressed, and the analysis indicates that Cyr61 and VEGF can be chosen as independent prognostic indicators. Yu et al. [20] analyzed the article on the relationship between VEGF and the survival of osteosarcoma patients, and it is pointed out that the overexpression of VEGF is not conducive to the survival of osteosarcoma patients, suggesting a poor prognosis of patients. The above studies have denoted that IMP3 and VEGF are highly expressed in osteosarcoma, but there are few reports on the correlations of IMP3 as well as VEGF with stage, pulmonary metastasis and other aspects of osteosarcoma.

Therefore, this study discussed the correlations of protein expressions of IMP3 and VEGF with stage, MVD and pulmonary metastasis of osteosarcoma in 37 osteosarcoma patients. First of all, the expressions of IMP3 and VEGF in osteosarcoma tissues and adjacent tissues were detected with the SP immunohistochemical method. The results revealed that the positive rate of IMP3 was 91.89%, and that of VEGF was 94.59%, indicating that expressions of IMP3 and VEGF in osteosarcoma tissues are significantly up-regulated. It was further found that overexpressions of IMP3 and

VEGF were accompanied by a significant increase in the positive rate of osteosarcoma patients in stage II and III, and the positive rate of patients in stage III was as high as 100.00%. In the study of MVD, it was found that the MVD of patients with high expressions of IMP3 and VEGF elevated markedly. In addition, the positive rates of IMP3 and VEGF were 76.92% and 72.72% respectively, which were higher than 29.17 % ($p < 0.05$) and 30.77 % ($p < 0.05$) of patients without pulmonary metastasis before the operation. The survival time decreased obviously, suggesting that expressions of IMP3 and VEGF are closely related to the physiological and pathological processes of osteosarcoma.

Conclusions

To sum up, the positive overexpression rates of IMP3 and VEGF in osteosarcoma patients in stage II and III are obviously increased, and the MVD is raised accordingly, and there is a greater probability of pulmonary metastasis, which shortens the survival period and indicates a poor prognosis of patients. It is revealed that IMP3 and VEGF can serve as potential excellent indicators for predicting the prognosis of osteosarcoma patients.

Conflict of interests

The authors declare no conflict of interests.

References

- Kansara M, Teng MW, Smyth MJ, Thomas DM. Translational biology of osteosarcoma. *Nat Rev Cancer* 2014;14:722-35.
- Zhang ZF, Li GR, Cao CN, Xu Q, Wang GD, Jiang XF. MicroRNA-1294 targets HOXA9 and has a tumor suppressive role in osteosarcoma. *Eur Rev Med Pharmacol Sci* 2018;22:8582-8.
- Chen Z, Zhao G, Zhang Y, Ma Y, Ding Y, Xu N. MiR-199b-5p promotes malignant progression of osteosarcoma by regulating HER2. *J BUON* 2018;23:1816-24.
- Li W, Zhang S. Survival of patients with primary osteosarcoma and lung metastases. *J BUON* 2018;23:1500-4.
- Gill J, Connolly P, Roth M et al. The effect of bone morphogenetic protein-2 on osteosarcoma metastasis. *PLoS One* 2017;12:e173322.
- Simpson E, Brown HL. Understanding osteosarcomas. *JAAPA* 2018;31:15-19.
- Huang X, Wei Q, Liu J, Niu H, Xiao G, Liu L. Analysis of IMP3 expression in primary tumor and stromal cells in patients with colorectal cancer. *Oncol Lett* 2017;14:7304-10.
- Zhu Q, Qu Y, Zhang Q et al. IMP3 is upregulated in primary ovarian mucinous carcinoma and promotes tumor progression. *Am J Transl Res* 2017;9:3387-98.
- Wang Q, Wang T, Wang Z, Zheng H. Diagnostic value of IMP3 in pancreatic cancer: a meta-analysis. *Int J Clin Exp Med* 2015;8:10603-10.
- Yang F, Zhou Q, Meng L, Xing N. IMP3 is a biomarker for non-muscle-invasive urothelial carcinoma of the bladder associated with an aggressive phenotype. *Medicine (Baltimore)* 2019;98:e16009.
- Gao Y, Yang M, Jiang Z et al. IMP3 expression is associated with poor outcome and epigenetic deregulation in intrahepatic cholangiocarcinoma. *Hum Pathol* 2014;45:1184-91.
- Zhang N, Chen J, Ferraro GB et al. Anti-VEGF treatment improves neurological function in tumors of the nervous system. *Exp Neurol* 2018;299:326-33.
- Autenshlyus AI, Arkhipov SA, Kunts TA et al. Cytokine profiles of tumor supernatants in invasive ductal cancer and fibroadenoma of the breast and its relationship with VEGF-A expression in the tumors. *Int J Immunopathol Pharmacol* 2017;30:83-8.
- Chekhonin VP, Shein SA, Korchagina AA, Gurina OI. VEGF in tumor progression and targeted therapy. *Curr Cancer Drug Targets* 2013;13:423-43.
- Hadley C, Gressot LV, Patel AJ et al. Osteosarcoma of the cranial vault and skull base in pediatric patients. *J Neurosurg Pediatr* 2014;13:380-7.
- Carrle D, Bielack SS. Current strategies of chemotherapy in osteosarcoma. *Int Orthop* 2006;30:445-51.
- Dong X, Li Y, Tang H et al. Insulin-like growth factor axis gene polymorphisms modify risk of pancreatic cancer. *Cancer Epidemiol* 2012;36:206-11.
- Hui S, Guo-Qi Z, Xiao-Zhong G, Chun-Rong L, Yu-Fei L, Dong-Liang Y. IMP3 as a prognostic biomarker in patients with malignant peritoneal mesothelioma. *Hum Pathol* 2018;81:138-47.
- Liu Y, Zhang F, Zhang Z et al. High expression levels of Cyr61 and VEGF are associated with poor prognosis in osteosarcoma. *Pathol Res Pract* 2017;213:895-9.
- Yu XW, Wu TY, Yi X et al. Prognostic significance of VEGF expression in osteosarcoma: a meta-analysis. *Tumour Biol* 2014;35:155-60.