

HISTORY OF ONCOLOGY

A historical overview of laryngeal carcinoma and the first total laryngectomies

Marianna Karamanou¹, Kostas Markatos², Maria Lymperi³, Emmanouil Agapitos⁴, George Androutsos⁵

¹University Institute of History of Medicine, Faculty of Medicine, Claude Bernard Lyon 1 University, Lyon, France; ²Henry Dunant Hospital, Athens, Greece; ³1st Propaedeutic Surgical Clinic, Hippokraton General Hospital, Medical School, National and Kapodistrian University of Athens, Athens, Greece; ⁴Department of Pathology, Medical School, National and Kapodistrian University of Athens, Athens, Greece; ⁵Biomedical Research Foundation, Academy of Athens, Athens, Greece

Summary

Laryngeal cancer was a well known entity since antiquity and its treatment evolved through several phases. The lack of knowledge in anatomy and pathology as well as the absence of anesthesia and proper instrumentation made the treatment almost impossible. Ancient physicians were performing laryngotomy or tracheotomy in an attempt to prevent the suffocation symptoms produced by tumoral masses. In 19th century the invention of laryngoscope and the advent of pa-

thology and anesthesiology encouraged surgeons to operate on man. In 1873 Theodor Billroth (1829-1894) performed the first laryngectomy followed by several other colleagues among which Enrico Bottini (1837-1903) and Themistocles Gluck (1853-1942). Thanks to their contribution a new era came in laryngeal cancer treatment: the conservation laryngeal surgery.

Key words: Billroth, history of oncology, cancer, laryngectomy, larynx

Introduction

Arising from the Greek word “karkinos” meaning crab, cancer was a well known entity since antiquity. The word “karkinos” was first mentioned around the 7th century BC and dates back to the priests of Asclepios (Asclepiads) to designate a specific disease entity which had two characteristics: the presence of a mass that could be ulcerated on its surface and the absence of spontaneous healing. As a therapeutic approach excision or external cautery was applied [1]. However, in cases of laryngeal cancer, laryngotomy or tracheotomy was proposed by ancient medical authors such as Asclepiades (c.124-40 BC) [2], Antyllus (2nd century AD) and Paul of Aegina (625-690), in an attempt to prevent the suffocation symptoms produced by tumoral masses [3].

Laryngeal growths in terms of warts were mentioned in the work of the Italian physician

Marcellus Donatus (1538-1602) “De medica historia mirabili” (On the medicine of miracles) and according to him were rare [4]. In the middle of the 18th century the French anatomist Joseph Lieutaud (1703-1780) in his manuscript “Essais Anatomiques” (Anatomical Essays) recorded two postmortem cases in which enlarged laryngeal polypi provoked death [5,6].

A crucial point in the history of laryngeal diseases occurred in the 19th century when mirror laryngoscopy enabled the visualization of the larynx. Attempts to visualize the larynx have been made by several physicians such as Philipp Bozzini (1773-1809) and the famous obstetrician André Levret (1703-1780) who used polished metals [6]. However, the credit for this discovery is given to the baritone Manuel Garcia (1805-1906) who saw his vocal cords with the aid of two mirrors and




Figure 1. Portrait of the almost centenarian baritone and inventor of laryngoscope Manuel Garcia (1805-1906).




Figure 2. A patient practising auto-laryngoscopy. (Source: Fournié E. Autolaryngoscopie - Etude pratique sur le laryngoscope et sur l'application des remèdes topiques dans les voies respiratoires. Paris, Delahaye, 1863).

reflected sunlight (Figure 1). Though not a physician, Garcia published in 1855 his observations in the *Proceedings of the Royal Society* and became known as the “father of laryngoscopy” [7]. Laryngoscopy helped physicians to visualize larynx and to recognize its affections while the progress of anesthesiology gave a new boost in the treatment of laryngeal neoplasms (Figure 2).

Laryngeal cancer: A new pathological classification and the first total laryngectomies

In 1871, the distinguished British physician and pioneer of laryngology, Sir Morell Mackenzie (1837-1892) published his essay on “Essay on growths in the larynx” and differentiated laryngeal growths into papillomata, benign epithelial growths, fibromata, fibrocellular or mucous polypi, myxomata, spindle-celled sarcomata, cystic tumors, adenomata, and angeiomata. Moreover, he described various intralaryngeal instruments of his own invention, among them his version of laryngeal forceps [8].

Thanks to the advent of pathology the last decades of the 19th century, laryngeal neoplasms classification changed and they were divided into sarcomas and carcinomas [9]. Sarcomas could arise in any part of the larynx and they were affecting more frequently adult males than females. They were looking like an irregular papillary or warty mass growing slowly and producing an extensive destruction of the larynx and its surrounding structures. Sarcomas could provoke death from suffocation and physicians were usually performing a life saving tracheotomy. Nevertheless, the cancerous lesions were not properly treated and most of the patients were dying after three years [9]. Carcinomas of the larynx were categorized as intrinsic and extrinsic. Intrinsic carcinomas were growing in vocal cords, thyroid angle and ventricles while extrinsic ones in epiglottis, aryepiglottic and interarytenoid folds [9].

Intrinsic carcinomas had initially the aspect of a warty growth and at that stage they could not easily be distinguishable from sarcomas. However, later they formed a distinct ulcerated tumour which infiltrated the subjacent structures and affected the entire organ, spreading also into the lymphatics producing thus secondary metastasis.

On the other hand extrinsic carcinomas spread rapidly into the larynx and its surrounding organs such as pharynx, tongue, tonsils, and palate [9]. Lymphatic glands were also affected and distant

metastasis may appear. The majority of the patients died within a year or eighteen months [9].

Still, the operation technique in the larynx was not well developed and as a result patients were mistreated. Laryngeal knife was used for their excision as well as the topical application with camel's hair brushes of caustic substances such as silver nitrate. In 1850, Charles-Henri Ehrmann (1792-1878), professor of anatomy and surgery in Strasbourg School of Medicine, published his treatise "Histoire des polypes de larynx" (History of laryngeal polyps) where he described the case of a 33-year-old woman who was diagnosed with laryngeal polyps and lost her voice. After a preliminary tracheotomy, Ehrmann divided the patient's thyroid and cricoid cartilage and became the first surgeon to excise a laryngeal tumor by a direct route. The patient recovered well but without a voice and died after seven months of typhoid fever [6,10]. Fifteen years later, in 1865, the American surgeon Henry Berton Sands (1830-1888) reported an external operation for laryngeal cancer which had been previously diagnosed by the newly introduced laryngoscope. The patient recovered from the operation and died within a year [6]. During the same period Sands reported eleven thyrotomies and thirty-nine intralaryngeal operations for laryngeal growths [11].

Soon afterwards, in 1869, the American laryngologist Jacob da Silva Solis Cohen (1838-1927) introduced the anterior laryngofissure for the management of laryngeal cancer. The patient recovered and lived 20 years after the operation [12].

The first total laryngectomy for cancer was performed on 31 December 1873, by Theodor Billroth (1829-1894), pioneer of modern surgery, head of the Second Surgical University Clinic at the "Allgemeine Krankenhaus" (Vienna General Hospital) [13] (Figure 3). The patient was a 36-year-old theology teacher, who was suffering by a chronic hoarseness. A subglottic tumor had been diagnosed by the laryngologist Carl Stoerk (1832-1899) and was histologically confirmed as an epithelioma [12]. Initially the patient was treated with silver nitrate, cautery and intraleisional injections of liquor ferri (solution of perchloride of iron). A partial removal was also attempted but it failed to arrest the growth. On 27th November 1873, Billroth tried to remove the tumor by laryngofissure. A preliminary tracheotomy was performed through the first tracheal ring by an incision which divided the cricoid cartilage in the midline and the thyroid cartilage just to the left of the midline. The larynx was opened, the tu-

© Académie nationale de médecine



Figure 3. The pioneer of laryngectomy Theodor Billroth (1829-1894) in young age.

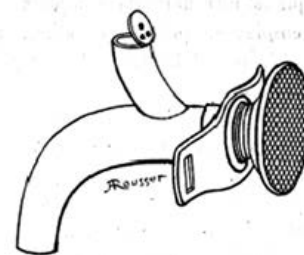


Fig. 429. - Larynx artificiel de Gussenbauer.

Figure 4. Gussenbauer's artificial larynx.

mor was excised, preserving the right vocal fold, and the wound was irrigated and closed. During the operation they inserted Trendelenburg's tampon cannula, used for preventing patients from swallowing blood during operations of the larynx, although patient aspirated blood [12]. Two weeks postoperatively, the patient was able to speak with a hoarse voice. However, during the night of 29th December, he became increasingly

breathless and the original tracheotomy wound was reopened with dilators and a cannula was inserted into the trachea. A further laryngofissure was recommended on 31 December and it was found that the tumor had recurred and was infiltrating the perichondrium of the thyroid cartilage. Intraoperatively, the anesthetic dose was diminished, the patient woke up and was informed of the findings. Surgeons advised him that the only suitable operation was laryngectomy; the patient consented and was re-anesthetized (!). The larynx was mobilized on each side and the superior thyroid arteries were ligated. Due to an excessive bleeding at this stage, the patient repeatedly woke from the anesthetic and coughed blood from the trachea. Then, Billroth transected the trachea from the larynx and inserted the anesthetic into the trachea. The lower part of the cricoid cartilage was separated from the anterior wall of the esophagus and the hypo pharynx was separated from the thyroid cartilage. Lastly, the thyroid ligament was cut and the base of the epiglottis and the upper two tracheal rings were removed. The edges of the trachea and the pharyngeal mucosa were sutured to skin. It was actually a bloody and large ablative operation which lasted almost 13 hours [12]. The patient wake up and initially he was receiving liquid food but after eighteen days he ate solid food. Furthermore, Billroth's assistant Carl Gussenbauer (1842-1903), who reported the operation in 1874 in the Third Congress of the German Society of Surgeons, designed a T-shaped tube named "artificial larynx" [14] (Figure 4). Artificial larynx was consisted by three cannulas (tracheal, pharyngeal and phonation) and an artificial epiglottis. Phonation was produced by a vibratory metal platelet located in the phonation cannula [12,14]. It was said that the patient developed a loud voice and left the hospital on 3rd May 1874. Seven months after the operation he died from a fatal recurrence [12]. It's worth mentioning that before Billroth's laryngectomy, attempts had been

made by several physicians in animals or corpses such as the experiment of Vincenz Czerny (1842-1916), who in 1870 carried out total laryngectomies on dogs without success, discouraging repetition of the operation on man [15]. Billroth paved the way for the total ablation of the larynx and he was followed by the Italian surgeon Enrico Bottini (1837-1903) who performed the first completely successful laryngectomy in 1875. The patient was diagnosed with a laryngeal sarcoma and survived 10 years after surgery [16].

The operative or early postoperative mortality rates were approximately 50% and patients were developing haemorrhage, fistula, pneumonia and sepsis. For the above mentioned reasons, total laryngectomy was successful if the patient's life had been extended by at least twelve months [12].

Conclusion

For centuries, the lack of knowledge in anatomy and pathology as well as the absence of anaesthesia and instruments made the treatment of laryngeal cancer impossible [17]. After the first attempts of laryngectomy at the end of 19th century, the Romanian born, German surgeon Themistocles Gluck (1853-1942) reported in 1908, 128 total laryngectomies among which 20 patients were alive and free from recurrence at the end of three years. Actually Gluck along with his collaborator Johannes Soerensen (1862-1939), made two important steps to standardise the technique by performing the operation in two stages, separating the airway from the digestive tract and by creating as a routine procedure the tracheostoma [12]. Thanks to their contribution a new era came in laryngeal cancer treatment. The conservation laryngeal surgery which was consisting of a variety of partial laryngectomy procedures provided to the patient a better quality of life, avoiding stoma dependence and permanent aphonia [17].

References

1. Karamanou M, Diamadis A, Androutsos G. The first cases of cancer in antiquity. *JBUON* 2008;13:601-608.
2. Green RM (transl). *Asclepiades. His Life and Writings: Antonio Cocchi's Life of Asclepiades and Christian Gottlieb Gumpert's Fragments from Asclepiades*. New Haven, Licht, 1955.
3. Adams F (Ed). *The Seven Books of Paulus Aegineta*. Vol. 2, London, Sydenham Society, 1846, pp 300-303.
4. Donatus M. *De medica historia mirabili*. Mantua, 1586.
5. Lieutaud J. *Essais Anatomiques*. Paris, Huart, 1742.
6. Wright J. *A History of Laryngology and Rhinology*. Philadelphia, Lea and Febinger, 1914.
7. Garcia M. Observations on the Human Voice. *Proc R Soc Lond* 1854;7:399-410.
8. Mackenzie M. *Essay on Growths in the Larynx*. London, Churchill, 1871, pp 45-53.
9. Butlin HT. *On the Operative Surgery of Malignant Disease*. London, Churchill, 1900, pp 187-190.

10. Ehrmann CH. Histoire des polypes de larynx. Strasbourg, Berger-Levrault, 1850.
11. Sands HB. Case of cancer of the larynx, successfully removed by laryngotomy with an analysis of 50 cases of tumors of the larynx, treated by operation. New York Medical Journal 1865;1:110-126.
12. Weir N. Otolaryngology-An Illustrated History. Butterworths, London University Press, 1990.
13. Miehke A. Theodor Billroth, 1829-1894. Arch Otolaryngol 1966;84:354-358.
14. Billroth CAT, Gussenbauer C. Über die erste durch Th. Billroth am Menschen Ausgeführte Kehlkopf Extirpation und die Anwendung eines künstlichen Kehlkopfes. Archiv für klinische Chirurgie 1874;17:343-356.
15. Czerny V. Versuche über Kehlkopf-Extirpation. Med Wschr 1870;27:559.
16. Bottini E. Estirpazione totale di laringe umana: seguita de esito felice. Comunicazione letta innanzi la Royal Academia di Medicina di Torino. 1875;414-434.
17. Genden EM, Ferlito A, Silver CE et al. Evolution of the management of laryngeal cancer. Oral Oncol 2007;43:431-439.