

LETTERS TO THE EDITOR

The emerging antineoplastic effects of nitidine chloride

Dear Editor,

We read with great interest the recent article by Kang et al.[1] published in JBUON identifying that nitidine chloride can inhibit proliferation and induce apoptosis of nasopharyngeal carcinoma cells with upregulation of p53 gene in a time- and dose-dependent manner. Interestingly, recent data suggests that nitidine chloride may exert antineoplastic effects in a number of other systemic malignancies.

For instance, nitidine chloride shows an inhibitory effect on tumor growth in renal carcinomas. It mediates these effects via suppressing the ERK signaling pathway [2]. Subsequently, nitidine chloride decreases the phosphorylation of ERK and Akt. Increased levels of Bax are observed within the tumor cells. Simultaneously, the level of Bcl-2 is downregulated, thus inducing apoptosis of cancer cells. Interestingly, the pro-apoptotic effects of PD98059, a specific inhibitor, is markedly accentuated secondary to the administration of nitidine chloride. Besides, nitidine chloride can also show anti-metastatic activity in renal cell carcinomas by mediating the AKT signaling pathway [3]. The phosphorylation of AKT is seen within the tumor cells, and the downregulation of MMP-2 and MMP-9 accompanies the above changes. When treating cancer cells by nitidine chloride combined with AKT inhibitors such as LY294002, a synergistic anti-metastatic effect is observed.

A similar impact has also been seen in hepatocellular carcinomas [4]. Nitidine chloride acts by blocking the activation of JAK1 and STAT3 signaling pathway. As a result, it decreases the tumor volume and weight. The expression of cyclin D1, CDK4 and Bcl-2 is downregulated while the levels of p21 and Bax are upregulated within the tumor cells. Similarly, nitidine chloride has a negative impact on mammary carcinomas [5]. It mediates the tumor cells migration and invasion by attenuating the c-Src/FAK signal-

ing pathway. It decreases PDGF-induced phosphorylation of c-Src, FAK and MAPKs. And activation of RhoA, Rac1 and AP-1 transcriptional activity is also seen following the above changes.

The above examples clearly illustrate the significant antineoplastic effects of nitidine chloride and the need for further studies.

References

1. Kang M, Ou H, Wang R et al. The effect of nitidine chloride on the proliferation and apoptosis of nasopharyngeal carcinoma cells. J BUON 2014;19:130-136.
2. Fang Z, Tang Y, Jiao W et al. Nitidine chloride induces apoptosis and inhibits tumor cell proliferation via suppressing ERK signaling pathway in renal cancer. Food Chem Toxicol 2014;66:210-216.
3. Fang Z, Tang Y, Jiao W et al. Nitidine chloride inhibits renal cancer cell metastasis via suppressing AKT signaling pathway. Food Chem Toxicol 2013;60:246-251.
4. Liao J, Xu T, Zheng JX et al. Nitidine chloride inhibits hepatocellular carcinoma cell growth in vivo through the suppression of the JAK1/STAT3 signaling pathway. Int J Mol Med 2013;32:79-84.
5. Pan X, Han H, Wang L et al. Nitidine chloride inhibits breast cancer cells migration and invasion by suppressing c-Src/FAK associated signaling pathway. Cancer Lett 2011;313:181-191.

Ji-Liang Xu, Rong Xia

Dept of Stomatology, the Second Hospital of Anhui Medical University, Hefei, China.

Correspondence to: Ji-Liang Xu, Rong Xia

E-mail: xujiliang20122547@gmail.com; xiarongqh@gmail.com

Recurrent parathyroid carcinoma with spinal metastases unresponsive to cinacalcet therapy

Dear Editor,

Parathyroid carcinoma is a rare cause of primary hyperparathyroidism, and its incidence is no more than 0.5 - 3% of parathyroid neoplasms. It is slow-growing,

and distant metastases occur late in the course of the disease. Death is commonly attributed to the metabolic complications of recurrent or persistent primary hyperparathyroidism rather than to tumor growth. Because external beam radiation and chemotherapy are general-

ly ineffective for the treatment of recurrent or persistent parathyroid carcinoma, reoperation is often recommended to relieve symptoms and to eradicate residual disease. Calcimimetic therapy was firstly proposed in 1998 as an alternative option to control hypercalcemia in refractory parathyroid carcinoma. Then the first and single multicenter clinical trial revealed the efficacy of cinacalcet in parathyroid carcinoma [1,2]. We present herein a case of recurrent parathyroid carcinoma with spinal column metastases unresponsive to cinacalcet therapy.

A 45-year-old woman with a history of parathyroid carcinoma 11 years ago was admitted to our clinic with hypercalcemia (PTH:494 pg/ml, Ca:11.6 mg/dl). ^{99m}Tc -MIBI and neck MRI scans demonstrated no recurrence of parathyroid glands or a mass. Thoracoabdominal CT and spinal MRI scans were normal. For hypercalcemia, pamidronate treatment was administered once a month. Despite bisphosphonate treatment, the patient's PTH levels increased to 992 pg/ml and Ca levels to 13.0 mg/dl. The patient was then given cinacalcet 90 mg/day. Due to refractory hypercalcemia, the patient was put on hemodialysis with low calcium dialysate every day. The dose of cinacalcet was increased up to 270 mg (three times 90 mg p.o.), but the PTH and Ca levels did not decrease on the 35th day of cinacalcet treatment. At the end of 35th day of treatment, cinacalcet therapy was halted, and bisphosphonate treatment was continued. The calcium (16.7 mg/dl) and PTH (1373 pg/ml) levels continued to increase. Four months after admission, the patient developed severe backache and paresthesia in her lower extremities. MRI scan of the lumbar spine demonstrated a metastatic lesion 5 cm in width in the right lateral region of L3 vertebral corpus (Figure 1). ^{99m}Tc -MIBI scan and neck MRI scan demonstrated no recurrence of parathyroid carcinoma or a mass. Tru-cut biopsy from the L3 was reported as metastatic parathyroid carcinoma. Spinal surgery was planned; however, before surgery the patient's medical condition deteriorated, and she died due to progressive hypercalcemia and renal failure.

Parathyroid carcinoma is a tumor with low malignant potential and tends to recur locally. Distant metastases occur late in the course of the disease via both lymphatic and hematogeneous routes. Cervical nodes (30%) and lung (40%) are involved commonly, followed by liver (10%). Local and/or distant metastases of parathyroid carcinoma are usually presented as persistent hypercalcemia following the initial surgery for neck disease [3]. Occasionally, detection of these metastatic foci might not be possible.

In patients with primary hyperparathyroidism, cinacalcet therapy has resulted in decreased serum calcium concentrations for as long as 3 years [4,5]. Silverberg et al. demonstrated that cinacalcet effectively reduces hypercalcemia in two-thirds of patients with inoperable parathyroid carcinoma and greatest reductions in serum calcium were observed in patients with particularly high calcium levels [2].

Although not curative, resection of distant metasta-

ses palliates and prolongs life for a number of years by relieving the symptoms and improving the metabolic disturbances. Patients who achieved a favorable response from metastectomy are more likely to have a peripherally situated single lesion. Patients with multiple lesions are more likely to undergo major surgery, but complications secondary to hyperparathyroidism develop like in our patient.

References

1. Lee PK, Jarosek SL, Virnig BA et al. Trends in the incidence and treatment of parathyroid cancer in the United States. *Cancer* 2007;109:1736-1741.
2. Silverberg SJ, Rubin MR, Faiman C et al. Cinacalcet hydrochloride reduces the serum calcium concentration in inoperable parathyroid carcinoma. *J Clin Endocrinol Metab* 2007;92:3803-3808.
3. Koea JB, Shaw JH. Parathyroid cancer: biology and management. *Surg Oncol* 1999; 8:155-165.
4. Joy MS, Kshirsagar AV, Franceschini N. Calcimimetics and the treatment of primary and secondary hyperparathyroidism. *Ann Pharmacother* 2004;38:1871-1880.
5. Szmuiłowicz ED, Utiger RD. A case of parathyroid carcinoma with hypercalcemia responsive to cinacalcet therapy. *Natl Clin Pract Endocrinol Metab* 2006;2:291-296; quiz 297.

Mehmet A.N. Sendur¹, Selcuk Dagdelen², Osman Abbasoglu³, Belkis Erbas⁴, Cenk Sokmensuer⁵, Ibrahim Ziyal⁶, Tomris Erbas².

¹Ankara Numune Education and Research Hospital, Department of Medical Oncology, Ankara; Hacettepe University Faculty of Medicine, Departments of Endocrinology & Metabolism², General Surgery³, Nuclear Medicine⁴, Pathology⁵ and Neurosurgery⁶, Ankara, Turkey

Correspondence to: Mehmet Ali Nahit Sendur, MD.
E-mail: masendur@yahoo.com.tr

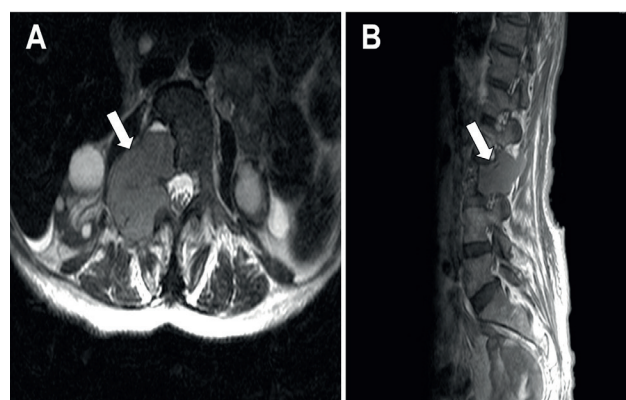


Figure 1. MRI scan of lumbar spine demonstrates a metastatic lesion (arrows) in the right lateral region of L3 vertebral corpus (A: axial and B: sagittal sections).

Does cetuximab cause small bowel perforation?

Dear Editor,

Some types of solid tumors overexpress epithelial growth factor receptor (EGFR), which activates cellular signalling, migration and proliferation. Cetuximab is a human/mouse monoclonal antibody that inhibits EGFR [1]. It has been approved for the treatment of metastatic k-ras wild type colorectal cancers and head neck cancers [1,2]. Rash and diarrhea are the more frequent side effects of this agent [1]. Herein we report a case of bowel perforation which might be associated with the cetuximab-containing chemotherapy for the treatment of metastatic adenocarcinoma of sigmoid colon.

A 65-year-old male patient with metastatic sigmoid adenocarcinoma was admitted to the emergency service with the major complaint of abdominal pain and constipation. The patient had received one cycle of irinotecan and cetuximab combination regimen (one cycle consists of 4 weekly doses of irinotecan and cetuximab) 4 weeks ago and the second cycle was delayed due to significant weight loss. The patient's vital signs and physical examination were normal except abdominal tenderness on deep palpation. The patient was hospitalized with suspected ileus. Oral intake was stopped. The general status of the patient improved after 2 days of supportive treatment and the second cycle of irinotecan and cetuximab started. Abdominal pain reappeared and hypotension was noticed after the completion of cetuximab infusion. An allergic reaction due to cetuximab was suspected and 1 mg/kg methylprednisolone and 10 mg chlorphenoxamine hydrochloride were administered parenterally, while a consultation with the Department of General Surgery led to urgent laparotomy for acute abdomen, during which small bowel perforation was observed. Partial small bowel resection and drainage were carried out. The patient deceased 12 days after the operation due to sepsis.

Cetuximab is a monoclonal antibody that inhibits EGFR competitively and therefore blocks cancer cell growth, induces apoptosis and decreases the production of vascular endothelial growth factor (VEGF) [3]. Cetuxi-

mab may cause perforation via antitumor activity, reduction of VEGF levels or by causing mucositis. EGFR inhibitors may also prolong wound healing time [4] and this may cause perforation due to a pre-existing ulcer. As of 2014, to our knowledge, there is only one case of bowel perforation after cetuximab administration in the English literature [5]. We claim that bowel perforation should be considered in the differential diagnosis of patients with abdominal pain receiving cetuximab.

References

1. Van Cutsem E, Köhne CH, Hitre E et al. Cetuximab and chemotherapy as initial treatment for metastatic colorectal cancer. *N Engl J Med* 2009;360:1408-1417.
2. Vermorken JB, Mesia R, Rivera F et al. Platinum-based chemotherapy plus cetuximab in head and neck cancer. *N Engl J Med* 2008;359:1116-1127.
3. Bruns CJ, Harbison MT, Davis DW et al. Epidermal growth factor receptor blockade with C225 plus gemcitabine results in regression of human pancreatic carcinoma growing orthotopically in nude mice by antiangiogenic mechanisms. *Clin Cancer Res* 2000;6:1936-1948.
4. Kaftan H, Reuther L, Miede B, Hosemann W, Herzog M. The influence of inhibition of the epidermal growth factor receptor on tympanic membrane wound healing in rats. *Growth Factors* 2010;28:286-292.
5. Clemente G, Chiarla C, Giovannini I et al. Gas in portal circulation and pneumatosis cystoides intestinalis during chemotherapy for advanced rectal cancer. *Curr Med Res Opin* 2010;26:707-711.

Mehmet Akif Ozturk¹, Orhan Onder Eren², Basak Oyan²

¹Department of Internal Medicine, ²Department of Internal Medicine, Medical Oncology Section, Yeditepe University Hospital, Istanbul, Turkey

Correspondence to: Mehmet Akif Ozturk, MD.
E-mail: akifozturk@hotmail.com