

ORIGINAL ARTICLE

Efficacy of stereotactic radiotherapy as salvage treatment for recurrent malignant gliomas

Kemal Ekici¹, Naciye Ozseker², Alpaslan Mayadagli², Mihriban Erdogan Kocak³, Ali Olmezoglu³

¹Inonu University School of Medicine, Turgut Ozal Medical Center, Radiation Oncology, Malatya; ²Dr.Lutfi Kirdar Kartal Education and Research Hospital, Department of Radiation Oncology, Istanbul; ³Izmir Atatürk Training and Research Hospital, Department of Radiation Oncology, Izmir, Turkey

Summary

Purpose: To evaluate the efficacy and toxicity of CyberKnife stereotactic radiotherapy (SRT) for recurrent glial tumors previously treated with high-dose radiotherapy.

Methods: CyberKnife SRT was performed in 37 patients with recurrent glial tumors who presented to our hospital between January 2007 and March 2012. The patients were subjected to a dose ranging from 20 to 28 Gy using the CyberKnife system with an average of two fractions. The median follow-up duration after SRT was 14 months (range 1.8–57).

Results: The median survival time of the patients after

recurrence was 22.3 months (95% confidence interval/95% CI 12.5–32). The median survival times of the high- and low-grade patients were 29 and 19 months, respectively. No significant toxicity due to radiation was noticed during the follow-up period. No factor influencing mortality was found in either the univariate or multivariate analysis.

Conclusion: SRT using CyberKnife is an effective and safe treatment choice for recurrent glial tumors. SRT achieves a more favorable outcome in the treatment of recurrent tumors, particularly in high-grade ones

Key words: CyberKnife, glial tumors, recurrence, stereotactic radiosurgery

Introduction

Glial tumors develop from glial cells in the brain and are categorized as astrocytomas or oligodendrogliomas. The incidence of malignant glial tumors in the United States is 2.96/100,000 individuals [1,2]. Treatment choices for recurrent glial tumors include resection, radiotherapy, chemotherapy and other investigational treatment modalities. The life span associated with glial tumors usually varies among studies. Using these treatment modalities, the life span ranges from 8 months to 2 years [3,4]. Recurrence generally occurs within 2-cm margin with an 80% probability. Despite the current treatments available for recurrent patients, the median survival is between 3 and 6 months [5-8].

Repeat radiotherapy for recurrent glial tumors

is controversial because of the risk of necrosis caused by the radiation. Because it results in less damage to the surrounding tissue, SRT/stereotactic radiosurgery (SRS) is applicable. The efficacy of SRT for recurrent glial tumors has been reported in some case series and retrospective studies in the literature. In those studies, SRT was shown to be more effective in the treatment of glioblastoma multiforme than in glial tumors [9].

The term SRS was first used in 1951 with the application of high-dose radiotherapy in a single fraction to small and critically situated lesions. CyberKnife (Accuray Inc., Sunnyvale, CA, USA) is a frameless radiosurgery system developed approximately 20 years ago for SRT delivery. The machine can deliver radiation using a linear accelerator delivering 6 MV of X-ray energy mounted on a six-jointed robotic arm [10-12]. In the present

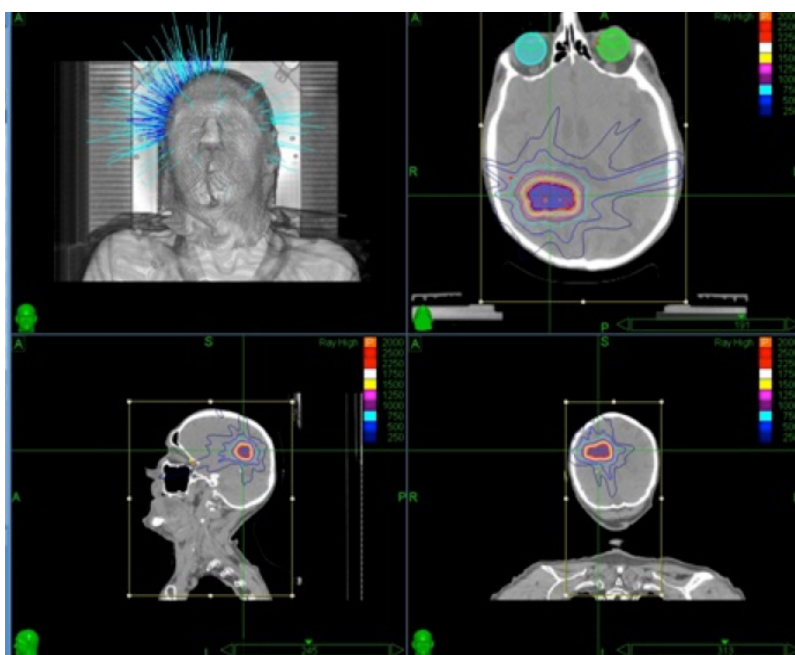


Figure 1. SRT treatment planning in a single patient.

study, we aimed to evaluate the efficacy and toxicity of CyberKnife radiosurgery for recurrent glial tumors.

Methods

Patients

Thirty-seven patients with recurrent glial tumors who were treated using SRS/SRT between March 2008 and January 2012 were evaluated. Their lesions, which absorbed contrast material during magnetic resonance imaging (MRI), were treated with SRT. Their medical records were examined for Karnofsky performance status (KPS), age at diagnosis, recursive partitioning analysis (RPA) classification, grade and volume of tumors, dosage of radiotherapy and time to recurrence.

All patients underwent surgery, radiotherapy or chemotherapy as initial treatment. When recurrence occurred, operable patients underwent further surgery. Fifteen patients were administered temozolomide after salvage treatment. The drug was given at a dose of 150–200 mg/m² daily for 5 days every 28 days until disease progression. No patient was subjected to concomitant chemotherapy during SRS or SRT treatment.

Therapy

Patients were treated using the CyberKnife system and immobilized using thermoplastic head and neck masks. Simulation computed tomography (CT) (GE Healthcare, Waukesha, WI, USA) was performed using 1.25-mm thick slices by administering intravenous contrast material. CT and MR images were transferred to the planning system of the CyberKnife computer. An individualized treatment plan was created for each pa-

tient. To better identify the target volume, CT and MR images were fused by superimposing. Fusion of MR images was performed using gadolinium-dependent, T1-weighted slices, which showed better contrast absorption in tumors and also better imaging quality. Using MRI and CT scan images, the gross tumor volume (GTV) and critical organs were sketched. The term “critical organs” included the eyes, lenses, optic nerves, chiasm and brain stem. The planning target volume (PTV) was defined by adding a 2-mm margin to the GTV. In evaluating the selected treatment plan, factors such as the homogeneity index and conformity index were considered (Figure 1).

These tumors were administered a median dose of 20 Gy (range 18–28). The tumor was prescribed between 70 and 90% of the dose. In the second radiation treatment, the prescribed dose was calculated by considering the previous radiotherapy dose, treatment volume and time between the treatments. Other SRT parameters are presented in Table 1. To prevent the development of edema, the patients were administered steroid therapy on the first day of treatment. The 6D_SKULL tracking system was used as a follow-up meth-

Table 1. Parameters of stereotactic radiotherapy

Parameters	Mean	Maximum	Minimum
Tumor volume (cm ³)	34.973	186.369	1.432
No. of radiation beams	194	343	103
Dose (Gy)	2,275	2,800	2,000
D-max	2,802	3,589	2,173
D-min	2,042	2,701	1,527
Monitor unit	23,628	45,679	2,631
Isodose	81	93	70
Fraction	3	7	2

od. If the radiation treatment was fractionated, a 24-h interval was applied between treatments. To verify that the patients received treatment in the appropriate position, portal scans were taken prior to treatment [13,14]. MRI was performed during the follow-up visits, starting 2 months after treatment and once every 3 months thereafter. The treatment responses were classified as complete response, partial response, disease progression or stable disease according to the Response Evaluation Criteria In Solid Tumors (RECIST). Local control was defined as lack of progression in the treatment field in MRI scans.

Statistics

The primary end point was overall survival (OS) after recurrence. OS was defined as the time between the date of starting SRT to the date of death or lost to follow-up. The relationships among age, tumor volume, KPS, dose and survival were calculated using univariate and multivariate analyses. The Kaplan–Meier method was used to calculate survival and differences in survival between two groups were assessed by the log-rank test. A p value less than 0.05 was deemed to indicate statistical significance. SPSS software, version 17.0.0 was used for the statistical analyses (SPSS Inc., Chicago, Ill, USA).

Results

Among the 37 patients, 21 (57%) were males and 16 (43%) females. The median age at diagnosis was 45 years (range 19–71). The RPA stage was defined at the time of SRT, and 11 (30%), 18 (48%), and 8 (22%) patients were at RPA stages I–II stages, III–IV, and V–VI, respectively. Initially, total resection was performed in 21 (57%) patients subtotal resection in 13 (35%) patients and biopsy in 3 (8%) patients. At the time of diagnosis, 15 (40%) patients had low-grade (1–2) disease, and 22 (60%) had high-grade (3–4) disease. Radiotherapy at a 60 Gy dose was delivered to 25 (67%) patients and a 54 Gy dose to 12 (33%) patients after surgery. Five patients with low-grade disease initially advanced to high-grade disease status before SRT treatment. Thus, at the time of SRT, 10 (27%) patients had low-grade and 27 (73%) patients high-grade disease. The location of the recurrence was in the frontal lobe in 15 (40%) patients, in the parietal lobe in 11 (30%), in the temporal lobe in 9 (24%) and in other lobes in 2 (6%). Fifteen (40%) patients were administered temozolomide after SRT. No significant toxicity due to radiation was found during the follow-up period. The patient characteristics according to tumor grade after SRT are shown in Table 2.

The median follow-up period from the time

Table 2. Characteristics of patients according to disease grade after SRT

Characteristics	Grade 1-2	Grade 3-4	Total
	N (%)	N (%)	N (%)
Age, years			
<50	9 (25)	15 (41)	24 (65)
>51	1 (1)	12 (33)	13 (34)
KPS			
70–80	2 (4)	9 (25)	11 (29)
90–100	8 (22)	18 (49)	26 (71)
Tumor volume (cm ³)			
<40	7 (19)	17 (46)	24 (65)
>40	3 (8)	10 (27)	13 (35)
Interval in hours			
0–24	1 (1)	17 (46)	18 (28)
>24	9 (25)	10 (27)	19 (52)

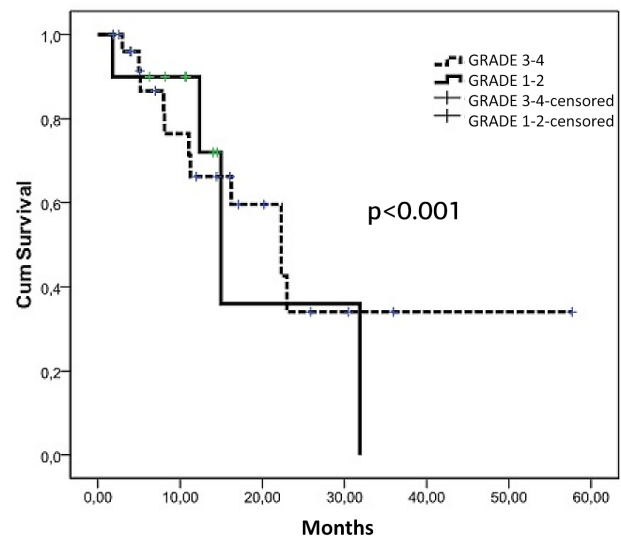


Figure 2. Kaplan-Meier survival curve according to disease grade after recurrence.

of diagnosis was 53 months (range 9–261). The median OS was 66 months (range 69–157), the 2-year survival was 87%, and the 5-year survival was 50%. The median OS survival was 53 months (range 40–66) in high-grade patients and 124 months (range 66–182) in low-grade patients ($p<0.001$). The median follow-up period after SRT was 14 months (range 1.8–57). The median OS after SRT was 22.3 months (range 12.5–32). The 1- and 2-year survival rates were 73% and 36%, respectively. OS after SRT was 29 months in high-grade patients and 19 months in low-grade patients ($p<0.001$) (Figure 2).

In univariate and multivariate analyses, age, time to recurrence, tumor volume, KPS, and grade of recurrence were evaluated to identify the factors influencing survival, but no statistical significance was noticed. Our analyses of the tumor vol-

ume effect showed that low-grade tumor volume of $\geq 6.000 \text{ cm}^3$ showed poor prognosis ($p=0.003$).

Discussion

In glial tumors, mortality is primarily influenced by the size of the tumor excised during the primary treatment. Patients with wide resection have a more favorable outcome than those with limited resection or biopsy only. Wide excision has two important advantages. First, it prevents neurologic deficits by causing internal decompression. Second, the application of maximal cytoreduction allows better efficacy of radiotherapy and chemotherapy in patients. Life spans after these treatment modalities vary between 8 months and 2 years with high-grade glial tumors, although different results have been reported among studies.

Despite the lack of a standard treatment modality for recurrent glial tumors, possible choices include new surgical resection, repeat radiation and chemotherapy.

While not suitable for every recurrent glial tumor, surgical resection is beneficial for selected patients with good performance and without any critical involvement. The median survival after resection of recurrent grade 3 or 4 tumors is between 36 and 88 weeks. However, the rate of complication is high with a morbidity of 5.7% and a mortality of 4.3% [15].

The effect of chemotherapy on recurrent glial tumors is uncertain. Studies have demonstrated a median survival of 3-7 months using temozolomide, teniposide and nitrosureas [16,17]. In a phase 2 study using temozolomide for the treatment of recurrent glioblastoma multiforme, the survival was prolonged by 7 months [18].

Several targeted treatments using bevacizumab and gefitinib combined with SRT have been attempted. In previous studies, bevacizumab, an antibody inhibiting vascular endothelial growth factor (VEGF), showed superior OS and progression-free survival (PFS) in patients with glioblastoma multiforme when used in combination with SRT. Bevacizumab was found to decrease the rate of radiation necrosis via improved circulation [19-21].

In a phase 3 study in which SRT was used as the primary treatment, no survival advantage was found [22].

Many studies have shown that SRS or SRT is effective in patients with recurrent glial tumors who have undergone external radiotherapy in curative doses. SRT is now becoming more popular

in patients unsuitable for surgical resection because of its low rate of side effects. No randomized controlled study to date has compared SRT with surgery for recurrent glial tumors [23].

A major prospective cohort trial [9] was conducted, in which SRT was applied to 114 patients with recurrent glial tumors. In that study, grade 4 glioblastoma multiforme showed a survival advantage. In another study [24], 172 patients showed good tolerance to a 36-Gy SRT dose in two fractions. In that study, patients with low-grade and small-volume ($<10 \text{ cm}^3$) glial tumors showed better prognoses. Prognostic factors showed variations among different studies. Important prognostic factors, in a study using multivariate analysis, were found to be KPS and low disease grade and, in another study, to be small tumor volume, young age, single focality, low disease grade and KPS [25].

It is generally reported that after SRT in recurrent glial tumors, several adverse effects can be encountered, such as headache, nausea, vomiting, and chronic radiation necrosis. Some studies have found no acute or chronic side effects, whereas others have reported a radiation necrosis rate up to 30%. In a study performing craniotomy in 7 cases that later developed radiation necrosis, 4 cases developed recurrence, 2 developed radiation necrosis, and one developed both recurrence and necrosis [26]. In a similar study [27], among 10 cases that underwent craniotomy for suspected radiation necrosis, 2 cases had recurrence, 2 had radiation necrosis, and 6 had both recurrence and necrosis. To differentially diagnose radiation necrosis and recurrence, metabolic-based positron emission tomography (PET) scan, MR spectroscopy and perfusion, diffusion and functional MRI were performed [27,28]. In our study, no patient developed acute or chronic side effects.

No consensus exists on the treatment of patients who develop recurrence after primary therapy. Grosu et al. [28] performed a study comprising 44 patients and showed that the most important factor influencing survival after repeat radiation in recurrent glial tumors was the time between initial diagnosis and recurrence. However, after a 10-year follow up, survival did not depend on the time interval between initial diagnosis and recurrence. In our study, no factor influencing survival was found in either the univariate or multivariate analysis in terms of the time lapse between initial diagnosis and recurrence.

Overall, death from recurrent glial tumors generally occurs as a result of local infection.

SRT using CyberKnife is a preferable treatment choice with a tolerable side effect profile, favorable local tumor control and a survival advantage.

CyberKnife is thought to be more effective, particularly in patients with small tumor volumes, high-grade tumors, and better performance status.

References

- Jemal A, Siegel R, Ward E et al. Cancer statistics, 2006. *CA Cancer J Clin* 2006;56:106-130.
- Louis DN, Ohgaki H, Wiestler OD et al. The 2007 WHO classification of tumours of the central nervous system. *Acta Neuropathol* 2007;114:97-109.
- Stupp R, Hegi ME, Mason WP et al; European Organisation for Research and Treatment of Cancer Brain Tumor and Radiation Oncology Groups; National Cancer Institute of Canada Clinical Trials Group. Effects of radiotherapy with concomitant and adjuvant temozolomide versus radiotherapy alone on survival in glioblastoma in a randomised phase III study: 5-year analysis of the EORTC-NCIC trial. *Lancet Oncol* 2009;10:459-466.
- Attar A, Ugur HC, Arasil E et al. Nüks malin gliomalarda reoperasyon kriterleri (Reoperation criteria for recurrent malignant gliomas). *J Ankara University Faculty Med* 1998;51:163-167 (in Turkish).
- Biswas T, Okunieff P, Schell MC et al. Stereotactic radiosurgery for glioblastoma: retrospective analysis. *Radiat Oncol* 2009;4:11.
- Lamborn KR, Yung WK, Chang SM et al; North American Brain Tumor Consortium. Progression-free survival: an important end point in evaluating therapy for recurrent high-grade gliomas. *Neuro Oncol* 2008;10:162-170.
- Wong ET, Hess KR, Gleason MJ et al. Outcomes and prognostic factors in recurrent glioma patients enrolled onto phase II clinical trials. *J Clin Oncol* 1999;17:2572-2578.
- Wallner KE, Galicich JH, Krol G, Arbit E, Malkin MG. Patterns of failure following treatment for glioblastoma multiforme and anaplastic astrocytoma. *Int J Radiat Oncol Biol Phys* 1989;61:405-409.
- Kong DK, Lee J, Park K, Kim JH, Lim DH, Nam DH. Efficacy of stereotactic radiosurgery as a salvage treatment for recurrent malignant gliomas. *Cancer* 2008;112:2046-2051.
- Andrews DA, Bednarz G, Evans JJ, Downes B. A review of 3 current radiosurgery systems. *Surg Neurol* 2006;66:559-564.
- Barnett GH, Linskey ME, Adler JR et al; American Association of Neurological Surgeons; Congress of Neurological Surgeons Washington Committee Stereotactic Radiosurgery Task Force. Stereotactic radiosurgery - an organized neurosurgery -sanctioned definition. *J Neurosurg* 2007;106:1-5.
- Levivier M, Gaevart T, Negretti L. Gamma Knife, CyberKnife, TomoTherapy: Gadgets or useful tools? *Curr Opin Neurol* 2011;24:616-625.
- Collins SP, Coppa ND, Zhang Y, Collins BT, McRae DA, Jean WC. CyberKnife radiosurgery in the treatment of complex skull base tumors: analysis of treatment planning parameters. *Radiat Oncol* 2006;1:46.
- Yu C, Jozsef G, Apuzzo ML, Petrovich Z. Dosimetric comparison of CyberKnife with other radiosurgical modalities for an ellipsoidal target. *Neurosurgery* 2003;53:1155-1162.
- Harsh GR, Levin VA, Gutin PH, Seager M, Silver P, Wilson CB. Reoperation for recurrent glioblastoma and anaplastic astrocytoma. *Neurosurgery* 1987;21:615-617.
- Mack F, Schäfer N, Kebir S et al. Carmustine (BCNU) plus Teniposide (VM26) in recurrent malignant glioma. *Oncology* 2014;86:369-372.
- Figueiredo EG, Faria JW, Teixeira MJ. Treatment of recurrent glioblastoma with intra-arterial BCNU [1,3-bis (2-chloroethyl)-1-nitrosourea]. *Arq Neuropsiquiatr* 2010;68:778-782.
- Schönekaes K, Mücke R, Panke J, Rama B, Wagner W. Combined radiotherapy and temozolomide in patients with recurrent high grade glioma. *Tumori* 2002;88:28-31.
- Vredenburgh JJ, Desjardins A, Herndon JE 2nd et al. Bevacizumab plus irinotecan in recurrent glioblastoma multiforme. *J Clin Oncol* 2007;25:4722-4729.
- Gonzalez J, Kumar AJ, Conrad CA, Levin VA. Effect of bevacizumab on radiation necrosis of the brain. *Int J Radiat Oncol Biol Phys* 2007;67:323-327.
- Schwer AL, Damek DM, Kavanagh BD et al. A phase I dose-escalation study of fractionated stereotactic radiosurgery in combination with gefitinib in patients with recurrent malignant gliomas. *Int J Radiat Oncol Biol Phys* 2008;15:70:993-1001.
- Binello E, Green S, Germano IM. Radiosurgery for high-grade glioma. *Surg Neurol Int* 2012;3:118.
- Fogh SE, Andrews DW, Glass J, Curran W, Glass C, Champ C. Hypofractionated Stereotactic Radiation Therapy: An Effective Therapy for Recurrent High-Grade Gliomas. *J Clin Oncol* 2010;28:3048-3053.
- Combs SE, Thilmann C, Edler L, Debus J, Schulz-Ertner D. Efficacy of fractionated stereotactic reirradiation in recurrent gliomas: Long-term results in 172 patients treated in a single institution. *J Clin Oncol* 2005;23:8863-8869.
- Carson KA, Grossman SA, Fisher JD, Shaw EG. Prognostic factors for survival in adult patients with recurrent glioma enrolled onto the new approaches to brain tumor therapy CNS consortium phase I and II clinical trials. *J Clin Oncol* 2007;25:2601-2606.

26. Hall WA, Djalilian HR, Sperduto PW et al. Stereotactic radiosurgery for recurrent malignant gliomas. *J Clin Oncol* 1995;13:1642-168.
27. Alexiou GA, Tsiouris S, Kyritsis AP, Voulgaris S, Argyropoulou MI, Fotopoulos AD. Glioma recurrence versus radiation necrosis: accuracy of current imaging modalities. *J Neurooncol* 2009;95:1-11.
28. Grosu AL, Weber WA, Franz M et al. Reirradiation of recurrent high-grade gliomas using amino acid PET (SPECT)/CT/MRI image fusion to determine gross tumor volume for stereotactic fractionated radiotherapy. *Int J Radiat Oncol Biol Phys* 2005;63:511-519.