

SHORT REPORT

Bleomycin-induced pneumonitis in three patients treated with chemotherapy for primary advanced seminoma

Moshe E. Stein¹, Jamal Zidan², Tomer Charas¹, Anthony Gershuny³, Rahamim Ben-Yosef¹

¹Northern Israel Oncology Center, Rambam Health Care Campus, and Faculty of Medicine, Technion-Israel Institute of Technology, Haifa, Israel; ²Department of Oncology, Safed Medical Center, and Faculty of Medicine in the Galilee, Bar-Ilan University, Safed, Israel; ³Department of Clinical Oncology & Radiation Therapy, Queen's Hospital, Romford-Essex, UK

Summary

Purpose: Bleomycin, etoposide and cisplatin (BEP) comprise the most common regimen in the treatment of advanced testicular tumors, including seminoma. Common side effects are of hematologic, renal, and cardiovascular origin. One of the most prominent side effects is pulmonary toxicity attributed to bleomycin. We describe three patients who developed bleomycin-induced pneumonitis (BIP) with full recovery.

Methods: Pre- and post-treatment clinical, biochemical (including specific tumor markers) and radiological response assessment of 26 patients with primary advanced seminoma (AS) who were referred to our hospital for platinum-based chemotherapy between 1989-2010 are described.

Results: All patients were assessable for evaluation and all achieved long-term complete remission. Side effects were mild and manageable. Three patients developed bleomycin pulmonary toxicity after reaching cumulative doses of 180-240 units. All three patients presented with classical symptoms of non-productive cough, exertional dyspnea,

and low-grade fever. Radiologically, the patients presented in the first months following completion of chemotherapy with initial bilateral interstitial and alveolar infiltrates, which worsened and progressed into consolidation and then regressed until total disappearance. All patients were treated with high-dose steroids and broad-spectrum antibiotics.

Conclusion: AS is a very chemotherapy-responsive and sensitive disease, and approximately 90% of the patients enjoy complete regression of tumor masses and durable and sustained long-term survival with no evidence of disease. BIP may be a dangerous acute and chronic side effect, even in doses lower than 360 units. Considering the favorable clinical outcome of our patients, prompt diagnosis should be made and rapid medical intervention should be implemented.

Key words: bleomycin, chemotherapy, pulmonary toxicity, seminoma

Introduction

Bleomycin is an antitumor antibiotic that has been used successfully to treat a variety of malignancies, including squamous cell carcinoma of the head and neck, cervical carcinoma, lymphoma, and germ cell tumors [1]. In advanced seminomatous and non-seminomatous germ cell tumors, it is introduced with platinum-analogues and etoposide [2]. Its most reported side effects are of dermatological and gastrointestinal nature. Acute

febrile and anaphylactoid reactions and Raynaud's phenomenon have also been reported.

Up to 10% of the patients receiving the drug develop a life-threatening pulmonary toxicity, including subacute pulmonary fibrosis, hypersensitivity pneumonitis, and organizing pneumonia [3]. Most patients developing BIP had received doses of 360 units or more but, in the standard regimen for advanced germ cell tumors which

contains a cumulative bleomycin dose of 270-360 units, fatal pulmonary toxicity rates have been in the range of 1-3%. Fatal BIP has been reported in 1-2% of patients receiving 4 cycles of BEP (cumulative bleomycin dose 360 units) and less than 1% with 3 BEP cycles (cumulative bleomycin dose 270 units) [3-5].

In our retrospective study, we describe three AS patients who developed BIP following a cumulative dose of 270 units and showed full recovery. Epidemiological and risk factors, clinical presentation, diagnostic measures, radiological evaluation, and treatment are briefly discussed.

Methods

Twenty-six patients with primary AS treated at our cancer center with cisplatin/bleomycin/etoposide (BEP) between 1989 and 2010 were analyzed. All patients were staged clinically, biochemically, and radiographically with computerized tomography (CT) scan. Response was determined by the modified Sloan-Kettering Cancer Center (MSKCC) criteria [6].

Results

The mean patient age with AS at presentation was 39.5 years (range 17-66). Presenting symptoms were painless testicular enlargement, swelling, and a palpable mass within the affected testicular sac. Initially, all patients were referred to our center following orchiectomy. Twenty-four patients had T1 disease (confined to testis) and two patients had T3 disease (spermatic cord invasion). All patients presented with abdominal and

/ or pelvic pain and palpable abdominal and/or pelvic tumor masses. Tumor markers were taken from all patients. Elevated serum levels of β -human chorionic gonadotropin (β -HCG) were detected in 12 patients and lactate dehydrogenase (LDH) in 8, which decreased gradually after orchiectomy alone and normalized totally after chemotherapy upon entering complete remission, never to rise again during follow-up. All radiological measures, mainly CT scan, exhibited retroperitoneal and /or pelvic lymphadenopathy (stage IIB and IIC disease).

All patients were treated with platinum-based chemotherapy, mainly BEP regimen, for 3 to 4 cycles. All achieved complete remission of their disease, based on disappearance of symptoms and palpable masses, normalization of b-HGG and LDH in 12 and 8 patients, respectively and complete radiological complete regression of lymphadenopathy. Side effects were mild and did not affect continuation of treatment. Symptoms included neutropenic fever (4 patients), mild peripheral neuropathy (2 patients), grade II mucositis (2 patients), temporary partial hearing loss (1 patient), tinnitus (1 patient), and herpes zoster (1 patient). Clinical characteristics of the three patients who developed BIP are demonstrated in Table 1. All these patients presented after reaching their cumulative bleomycin dose with non-productive, disturbing cough, exertional dyspnea, and fever ranging from 37.8°C to 38.3°C, with no signs of sepsis. Medical history was unremarkable. Physical examination demonstrated decreased performance status and, on auscultation, there were

Table 1. Clinical characteristics of the three patients who developed bleomycin-induced pneumonitis

Pt. No.	Age (years)	Radiological presentation of disease	Stage	Chemotherapy	Cumulative bleomycin (units)	Interval from chemotherapy (months) ¹	Radiological findings of BIP	Outcome	Latest status
1.	47	Massive retroperitoneal pelvic lymphadenopathy	IIC ²	BEP x 3 ³ EP x 1 ⁴	180	4	Bilateral, diffuse ground-glass opacities in lower lung lobe	Full recovery	Alive with NED
2.	36	Massive retroperitoneal lymphadenopathy, comprising left renal vein and 3 rd duodenal part; Encasement of the renal artery; Crossing the midline	IIC	BEP x 3	240	2	Bilateral, subpleural infiltrates in the lower parts of both lobes	Full recovery	Alive with NED
3.	34	Left retroperitoneal mass	IIB ⁵	BEP x 3	240	2	Fig. 1 (A-C)	Full recovery	Alive with NED

¹Interval between completion of chemotherapy and 1st radiological presentation of BIP, ²IIC : lymphadenopathy, larger than 5 cm, ³BEP : bleomycin / etoposide/cisplatin, ⁴EP : etoposide /cisplatin, ⁵IIB : abdominal lymphadenopathy, between 2-5 cm

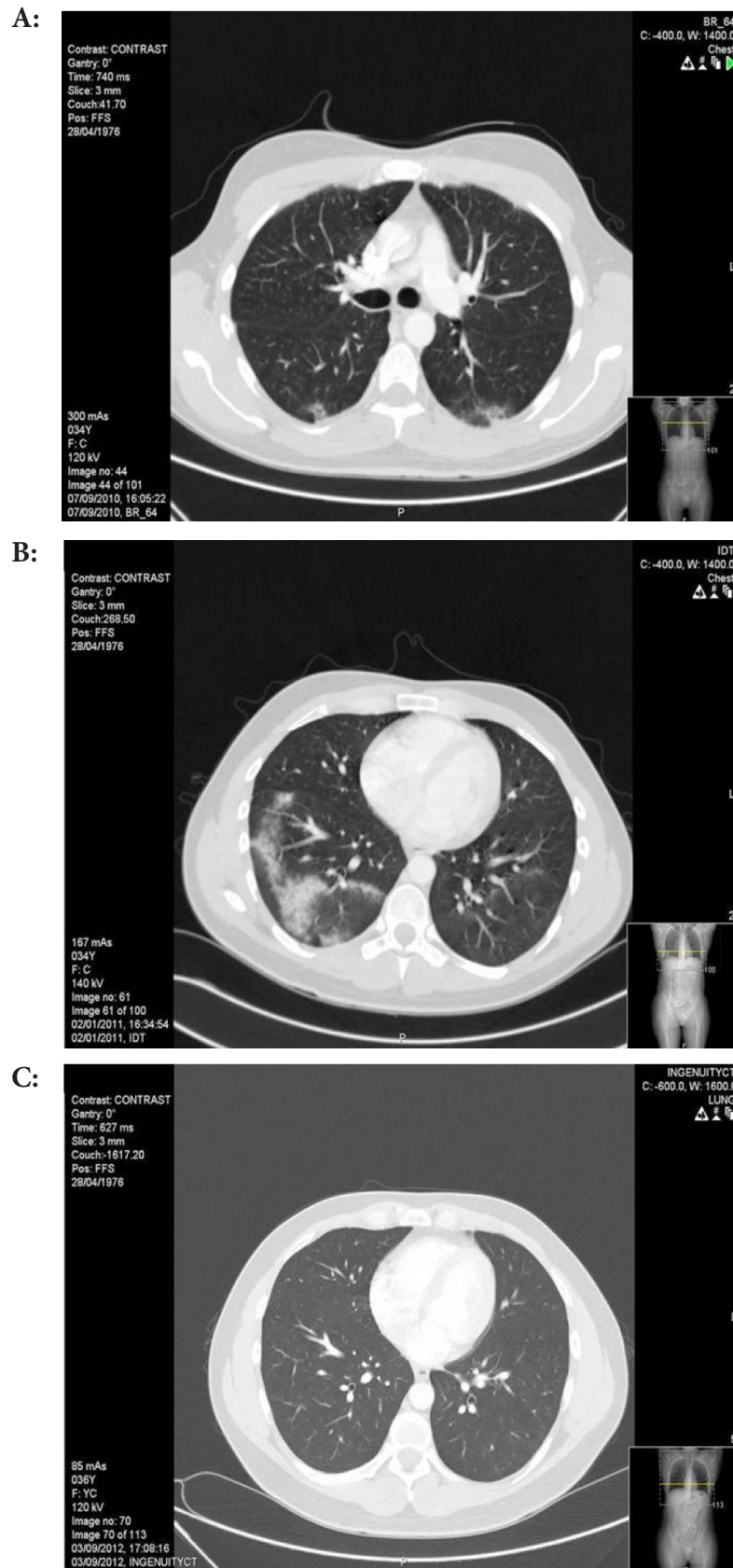


Figure 1. (Patient No. 3): Following completion of BEP regimen (cumulative bleomycin dose 240 units): **A:** 2 months: Interstitial alveolar infiltrates in the posterior, hanging parts of the right and left lower lobes. **B:** 5 months: Alveolar shadows in various sizes confined to both lung bases, more on the right side but also on the left side - clear worsening compared to 1A. **C:** 10 months: Clear regression and improvement in the right lower and right middle lobes.

crackles and crepitations across the lower and middle lung fields. Chest radiographs demonstrated bilateral, bibasilar infiltrates, which developed later into lung consolidation and regressed totally (Figures 1A, 1B, 1C). The three patients were treated with broad-spectrum antibiotics and high-dose steroids, and responded within 3-4 months with disappearance of symptoms and normalization of chest radiographs.

Discussion

Our long-term results, in comparison with other studies [7,8], show that AS is highly sensitive to platinum-based chemotherapy, with as many as 85-100% of the patients showing durable complete remission and survival rates greater than 90% in 10 years [2,8,9]. Toxicity was mild and manageable in most of the studies, apart from increasing reports about late second primaries, either solid or hematological in nature [10,11], which can be a significant challenge in chemo-radiotherapy-treated and cured patients.

Bleomycin is an important component of the BEP regimen, usually given weekly intravenously in 30 units (days 2, 9, 16) in 3-4 cycles for a cumulative doses of 270-360 units [1,2], which might cause the feared and sometimes fatal BIP. Three of our patients developed classical clinical and radiological symptoms of BIP, recovered uneventfully, and are alive and well with no evidence of disease after a median follow-up of 100 months.

BIP may occur in 20-40% of the patients treated with bleomycin, with mortality up to 3%, depending on the total dose and risk factors [12]. A central pathological event in the pathogenesis of BIP is endothelial damage of the lung vasculature, mediated through cytokines and free radicals, which contribute to endothelial cell damage and to subsequent infiltration of inflammatory cells into the irreversible process of widespread, lethal fibrosis [12,13].

Clinical symptoms are non-productive cough, fever between 37.4-38 °C, dyspnea and tachypnea, sometimes pleuritic and /or substernal pain, and auscultatory fine crackles. Symptoms occur usually 1-6 months after completion of chemotherapy [3]. Radiological signs start with bilateral bibasilar (interstitial / alveolar) infiltrates, which may progress into lobar consolidation and diffuse end-stage lung fibrosis [12-15]. Non-treatment or unresponsiveness to treatment ends in lethal respiratory failure. Evaluation of BIP consists of

clinical and radiological signs, pulmonary function tests (decreased diffusion capacity of carbon monoxide), and broncho-alveolar lavage (to exclude infection or malignancy). In extreme cases, a lung biopsy should be performed. Histopathology generally shows non-specific features ranging from squamous metaplasia to diffuse alveolar damage and fibro-proliferative changes, resulting in excess collagen production [3,12].

Generally recognized risk factors of BIP are as follows: age (mainly over 40-50 years); administration route (continuous infusion vs bolus; intramuscular vs intravenous); smoking; decreased renal function tests (approximately 80% of the bleomycin is rapidly eliminated by the kidneys); previous thoracic irradiation; simultaneous exposure to high concentrations of inspired oxygen; concomitant use of colony stimulating factors (conflicting data); high cumulative dose of cisplatin administered together with bleomycin and cumulative bleomycin dose [3,5,16,17]. O'Sullivan et al. [18] concluded that the three main factors predicting the highest probability of BIP are a glomerular filtration rate less than 80ml/min, a cumulative dose greater than 300 units, and age over 40. Lowering the bleomycin cumulative dose from 360 to 270 units or even lower, without omitting bleomycin altogether, was recommended [5,18].

There is no specific treatment for BIP. Steroids are recommended for symptomatic patients, though optimal dosing and duration of treatment are not known. Good results could be achieved with initial prednisone therapy of 0.75-1mg/kg up to 100 mg daily for 4-8 weeks and gradual tapering over an additional 4-6 months. In severe hypoxemia, supplementary oxygen is administered sparingly to maintain oxygen saturation. The value of broad-spectrum antibiotics has been called into doubt. Drugs that have demonstrated efficacy in animal models include pirfenidone (a novel antifibrotic agent), pentoxifylline, the cytokine relaxin, imatinib mesylate (a specific receptor tyrosine kinase inhibitor used against chronic myeloid leukemia and gastrointestinal stromal tumors), and augmentation of the enzyme bleomycin hydrolase [13,14,19].

In conclusion, the diagnosis of BIP is challenging and depends on clinical, radiological, and cytological/histopathological findings. Apart from steroids, there are no other well-known efficient and accepted drugs, and additional studies are warranted.

References

1. Umezawa H, Meaeda K, Takenuchi T, Okami Y. New antibiotics, bleomycin A and B. *J Antibiot Ser A* 1966;19:200-205.
2. Stein ME, Kuten A, Drumea K et al. Cisplatin-based chemotherapy in advanced seminoma: Experience of the Northern Israel Oncology Center (1981-1994). *J Surg Oncol* 1997;64:331-335.
3. Sleijfer S. Bleomycin-induced pneumonitis. *Chest* 2001;120:617-624.
4. Bauer KA, Skarin AT, Balikian JP, Garnick MB, Rosenthal DS, Canellos GP. Pulmonary complications associated with combination chemotherapy programs containing bleomycin. *Am J Med* 1983;74:557-563.
5. Parvinen LM, Kilku P, Maerkinen E, Liukko M, Groenroo S. Factors affecting the pulmonary toxicity of bleomycin. *Acta Radiol* 1983;22:417-422.
6. Horwich A, Dearnaley DP. Treatment of seminoma. *Semin Oncol* 1992;19:171-180.
7. Zagars GK, Ballo MT, Lee AK, Strom SS. Mortality after cure of testicular seminoma. *J Clin Oncol* 2004;22:640-647.
8. Mencil PJ, Motzer RJ, Mazumdar M, Vlamis V, Bajorin DF, Bosl GJ. Advanced seminoma: treatment results, survival, and prognostic factors in 142 patients. *J Clin Oncol* 1994;12:120-126.
9. Friedman EL, Garnick MB, Stomper PC, Mauch PM, Harrington DP, Richie JP. Therapeutic guidelines and results in advanced seminoma. *J Clin Oncol* 1985;3:1325-1332.
10. Bachaud JM, Berthier F, Soulie M et al. Second non-germ cell malignancies in patients treated for stage I-II testicular seminoma. *Radiother Oncol* 1999;50:191-197.
11. Travis LB, Fossa SD, Schonfeld SJ et al. Second cancers among 40,576 testicular cancer patients: Focus on long-term survivors. *J Natl Cancer Inst* 2005;97:1354-1365.
12. White DA, Stover DE. Severe bleomycin-induced pneumonitis. Clinical features and response to corticosteroids. *Chest* 1984;86:723-728.
13. Delanian S, Balla-Mekias S, Lefaix JL. Striking regression of chronic radiotherapy damage in a clinical trial of combined pentoxifylline and tocopherol. *J Clin Oncol* 1999;17:3283-3290.
14. Entzian P, Zähringer U, Schlaak M, Gerlach C, Galle J, Zabel P. Comparative study on effects of pentoxifylline, prednisolone and colchicine in experimental alveolitis. *Int J Immunopharmacol* 1998;20:723-735.
15. Miller KD, Loehrer PJ, Gonin R, Einhorn LH. Salvage chemotherapy with vinblastine, ifosfamide, and cisplatin in recurrent seminoma. *J Clin Oncol* 1997;15:1427-1431.
16. Comis RL. Bleomycin pulmonary toxicity: current status and future directions. *Semin Oncol* 1992;19 (Suppl 5):64-70.
17. Couderc LJ, Stelianides S, Frachon I et al. Pulmonary toxicity of chemotherapy and G/GM-CSF: a report of five cases. *Respir Med* 1999;93:65-68.
18. O'Sullivan JM, Huddart RA, Norman AR, Nicholls J, Dearnaley DP, Horwich A. Predicting the risk of bleomycin lung toxicity in patients with germ-cell tumours. *Ann Oncol* 2003;14:91-96.
19. Carnevale-Schianca F, Gallo S, Rota-Scalabrini D et al. Complete resolution of life-threatening bleomycin-induced pneumonitis after treatment with imatinib mesylate in a patient with Hodgkin's lymphoma: Hope for severe chemotherapy-induced toxicity? *J Clin Oncol* 2011;29:e691-e693.