

ORIGINAL ARTICLE

Evaluation of c-kit (CD 117) expression as a prognostic factor in testicular germ cell tumors: an Izmir Oncology Group (IZOG) study

Tarik Salman¹, Elif Yildiz², Ibrahim Yildiz¹, Dilek Yavuzer³, Mehtat Unlu⁴, Umut Varol¹, Murat Akyol¹, Yasar Yildiz¹, Vedat Bayoglu¹, Yksel Kucukzeybek¹, Ahmet Alacacioglu¹

¹Izmir Katip Celebi University, Ataturk Research and Training Hospital, Department of Medical Oncology, Izmir; ²Istanbul Umraniye Research and Training Hospital, Department of Internal Medicine, Istanbul; ³Istanbul Kartal Research and Training Hospital, Department of Pathology, Istanbul; ⁴Dokuz Eylul University Medicine Faculty, Department of Pathology, Izmir, Turkey

Summary

Purpose: Despite the successful use of targeted and molecular therapies in other cancers, little progress has been made in the management of testicular germ cell tumors (TGCTs). c-kit (CD 117) is a good target for cancer treatment and possesses an impressive role in the current oncological practice. We aimed to evaluate c-kit expression in early stage TGCTs as a prognostic factor.

Methods: Patients with TGCTs who were referred to the Medical Oncology Clinic and underwent curative surgical operation were included in our study before starting chemotherapy. Immunohistochemistry was performed on formalin-fixed and paraffin-embedded three-micrometer thick sections with CD 117 Rabbit Anti c-kit in vitro gene kit. Biochemically, we utilized AFP and β -HCG Immunlite 2000 device with solid phase chemiluminescent immunometric method, and LDH Roche models with the DP-standardized UV method. AFP 0-15 ng/ml, β -HCG < 0.1 mlu/ml and LDH 240-480 mg/dl were considered as normal values.

Results: Sixty-five patients were included in our study. Forty-one (63%) patients had non-seminoma tumors (NSGCTs) and 24 (37%) had seminoma. Statistically significant c-kit expression was found in patients with seminoma ($p < 0.0001$). There was no difference between negative

or positive c-kit expression in terms of clinicopathological characteristics, including preoperative serum levels of AFP, β -HCG, LDH, lymph node involvement, distant metastasis, and IGCCCG risk classification. No correlation was found between these parameters and 5-year progression free survival (PFS) rate except for tumor stage, presence of lymph node metastasis and IGCCCG score ($p = 0.001$, $p = 0.04$, and $p = 0.0001$, respectively). Five-year PFS rate of patients with positive CD 117 was 72.2% (95% CI, 54.6-89.8), and 56.6% (95% CI, 31.2-82.1) for those without CD 117 expression involvement ($p = 0.12$).

Conclusion: So far, there has been no significant breakthrough in the treatment of cisplatin- refractory TGCTs in the era of targeted therapies. No prognostic importance of c-kit expression has been found in our study. However, we believe that c-kit expression, in numerical terms, can be considered as a good prognostic factor for patients with TGCTs. The fact that all seminoma cases displayed positive c-kit expression is what we think has driven this result.

Key words: carcinogenesis, CD 117, c-Kit, embryogenesis, germ cell tumors, testicular cancer

Introduction

TGCTs, the most common malignancy in males aged 15-40 years, represent a major cause of cancer-related mortality in this age group [1,2].

TGCTs account for 1-1.5% of male neoplasms and 5% of urological tumors in general [3]. TGCTs can be subdivided into seminoma and NSGCTs, in-

cluding embryonal carcinoma, choriocarcinoma, yolk sac tumor and teratoma. Neoplasms containing more than one tumor cell component are referred to as mixed germ cell tumors (GCTs). Seminomas and NSGCTs present distinctive clinical features with significant differences in prognosis and therapeutic approach [4]. Most of the GCTs can be cured by chemotherapy, and in some cases by surgery alone. With a simple addition of cisplatin to bleomycin and vinblastine in the 1970s [5] the 5-year survival rates of GCT patients increased drastically, from 25 to 95% in 2008 [6]. Approximately 80% of patients with testicular cancer with metastatic disease can be cured with cisplatin-based chemotherapy. However, patients with poor risk disease remain a therapeutic challenge with no more than 60% survival rate in 5 years [7,8]. Patients with treatment failure after first-line chemotherapy display poor prognosis. The cure rate is 50% for patients treated with second-line chemotherapy and 15% for those with high-dose chemotherapy followed by autologous stem cell transplantation [9]. Despite the successful use of targeted and molecular therapies in other cancers, little progress has been made in the management of TGCTs.

The c-kit receptor (CD 117) is a transmembrane protein with tyrosine kinase activity encoded by the c-kit oncogene. The ligand for c-kit is the stem cell factor (SCF), a hematopoietic cytokine, which plays an important role in maintaining the survival of hematopoietic cells, promoting hematopoietic cell proliferation and differentiation, and regulating growth and development of hematopoietic cells [10]. c-kit activates downstream signal transduction and then regulates a variety of cells' biological behavior, such as normal cell proliferation and differentiation, tumorigenesis, cancer growth, migration and recurrence [11]. The c-kit as a target for tumor treatment is currently a hot topic. The c-kit protooncogene, located on the chromosome segment 4q11, encodes a type III transmembrane receptor tyrosine kinase [12,13]. The loss of functional mutations has demonstrated the crucial role of c-kit in normal growth and/or differentiation of several cell types. Overexpressed c-kit has been implicated in a number of human neoplasms including gastrointestinal stromal tumors, ovarian cancer, testicular germ cell tumors, small and non-small lung cancers, acute myeloblastic leukemia and malignant melanoma, suggesting a role for the c-kit and its mutant forms in carcinogenesis [14]. The tyrosine kinase receptor KIT is required for the survival

and proliferation of primordial germ cells (PGCs), and is then downregulated both in fetal oocytes undergoing meiosis and in male gonocytes, which stop proliferating after germ cell sex determination [15]. c-kit is also expressed in Leydig cells which, via SCF, are stimulated by Sertoli cells to produce testosterone [16].

The role of c-kit has been demonstrated in many types of tumors, and it has now secured its position among current treatments being administered. On the other hand, the role of c-kit in carcinogenesis and tumor progression has not yet been unraveled. The purpose of our study was to investigate the relationship between c-kit expression in seminoma and non-seminoma patients and the clinicopathological characteristics of demonstrated prognostic importance.

Methods

Patient selection

Sixty-five patients with TGCTs who were referred to the Medical Oncology Clinic and who had undergone orchiectomy were included in this study. Patients were staged according to the TNM staging system using proper radiological imaging methods and relevant biochemical parameters. Based on the patient clinicopathological characteristics, post-orchiectomy chemotherapy was or was not administered.

The primary endpoints of this study were PFS and overall survival (OS) in relation to CD 117 expression.

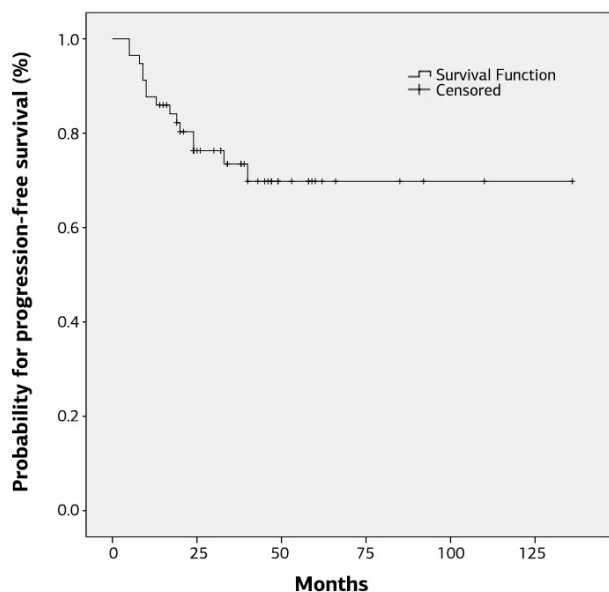
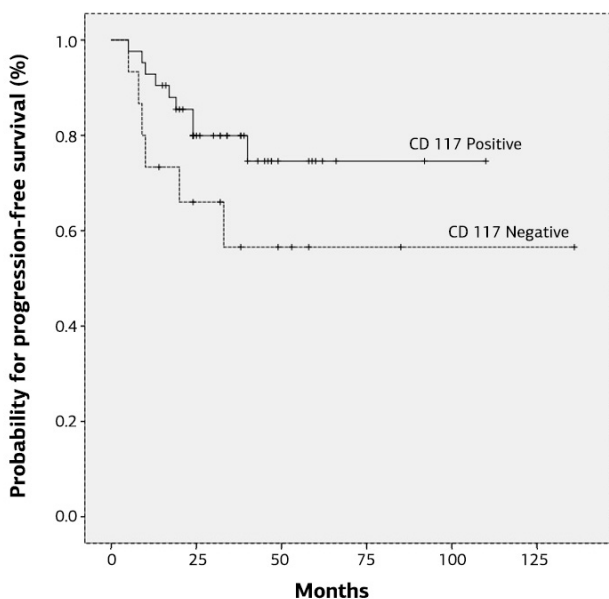
Pathological methods

We performed immunohistochemical (IHC) staining on formalin-fixed and paraffin-embedded three-micrometer thick sections. IHC staining was performed via rabbit polyclonal c-kit antibody (Dako Co. Ontario, Canada), which is a primary antibody. The tissue sections were fixed at 37°C for 24 hrs on poly-L-lysine coated slides prepared as per the manufacturer's instructions. After 24 hrs, they were deparaffinized in xylene and then rehydrated in decreasing ethanol series. Next, we washed the tissue sections in Tris-buffered saline (TBS, pH 7.6) and incubated them with normal saline for 10 min. Finally, an assessment was performed based on cytoplasmic and membranous stained tumor cell ratio, and the cells not stained with CD 117 were deemed negative.

Biochemically, we utilized AFP (Sigma-Aldrich, St. Louis, USA, alpha fetoprotein (AFP) human ELISA kit) and β -HCG (Sigma-Aldrich, St. Louis, USA, beta human chorionic gonadotropin (β -HCG) ELISA kit) immunite 2000 device with solid phase chemiluminescent immunometric method and lactate dehydrogenase (LDH) (Roche-Diagnostics, Basel, Switzerland) models with the DP-standardized UV method. AFP 0-15 ng/ml,

Table 1. Pathologic subgroups of testicular germ cell tumors and results of c-kit staining

Pathologic subgroups	N	Negative (-)	Weak (+)	Intermediate (++)	Strong (+++)
Pure germ cell tumors					
Seminoma	24	0	3	4	17
Embryonal	7	7	0	0	0
Yolk sack	3	1	1	1	0
Teratoma	5	1	2	1	1
Mixed germ cell tumors	26	7	8	6	5

**Figure 1.** Progression-free survival for all patients.**Figure 2.** Progression-free survival for patients based on CD117 expression (positive vs negative, $p=0.12$)

β -HCG less than 0.1 mlu/ml and LDH 240-480 mg/dl were considered normal values.

Statistics

The patient demographic characteristics were analyzed using descriptive statistics. Patient and tumor characteristics were compared between negative and positive c-kit expression groups using chi-square test or Fisher's exact test. PFS curves were generated according to the Kaplan-Meier method and compared using the log-rank test. Each variable was assessed using univariate analysis for PFS. Multivariate analysis was not performed because of the limited sample size and the low number of events. PFS was defined as the time from diagnosis to the last follow-up or by the time from the diagnosis to the first evidence of relapse. OS was defined as the time from diagnosis to death from any cause. All p values were 2-sided and p values <0.05 were considered significant. Statistical analyses were carried out with SPSS 16 (SPSS Inc., Chicago, Ill, USA).

Results

Sixty-five patients were included in our study. Forty-one (63%) patients were diagnosed with non-seminoma while 24 (37%) were diagnosed with seminoma. Pathologic subgroups and results of c-kit staining are summarized in Table 1 c-kit expression was negative in all patients with embryonal carcinoma. Patient characteristics stratified according to the presence or absence of c-kit expression are summarized in Table 2. Relapse rate was 25%. We found statistically significant c-kit expression in patients with seminoma ($p<0.0001$).

Patients with no c-kit expression had a median age of 27 years (range 18-41), while it was 34 years (range 17-75) for patients displaying c-kit positive expression ($p>0.05$).

There was no difference between negative or positive patients and c-kit expression in terms of clinicopathological characteristics, including pre-operative serum levels of AFP, β -HCG and LDH, lymph node involvement, distant metastasis, and

Table 2. CD 117 (c-kit) expression and patient/tumor characteristics

Characteristics	CD117 - Negative	CD117 - Positive	All patients	p value
	N=48 N (%)	N=17 N (%)	N=65 N (%)	
Age, years				
Median	27	34		
Range	18-41	17-75		0.44
Histology				
Seminoma	0 (0)	24(100)	24 (37)	<0.0001
Non-seminoma	17 (41)	24 (59)	41 (63)	
Preop. markers				
Normal				
High	9 (24)	28 (76)	37 (57)	0.70
LDH				
Normal	14 (31)	31 (69)	45 (70)	0.21
High	3 (16)	16 (84)	19 (30)	
Lymph node metastasis				
Negative	8 (20)	33 (80)	41 (63)	0.10
Positive	9 (38)	15 (62)	24 (37)	
Distant metastasis				
No	12 (24)	39 (76)	51 (78)	0.36
Yes	5 (36)	9 (64)	14 (22)	
IGCCCG risk status				
Good	11 (24)	35 (76)	46 (71)	0.21
Intermediate	3 (21)	11 (79)	14 (21)	
Poor	3 (60)	2 (40)	5 (8)	
Relapsing				
No	11 (22)	38 (78)	49 (75)	0.23
Yes	6 (38)	10 (62)	16 (25)	

LDH: Lactate dehydrogenase, IGCCCG: International Germ Cell Cancer Collaborative Group

IGCCCG risk classification. Univariate analysis of patients with TGCTs for PFS according to clinico-pathological characteristics is summarized in Table 3.

Univariate analysis for PFS was performed for histology (seminoma or non-seminoma), AFP and β -HCG (normal or high), LDH (normal or high), tumor stage (Ia or Ib), lymph node metastasis (present or absent), IGCCCG score (good or intermediate or poor) and CD 117 expression (present or absent). Five-year PFS rate was significantly correlated with tumor stage, presence of lymph node metastasis and IGCCCG score ($p=0.001$, $p=0.04$, and $p=0.0001$, respectively; Figure 1). Five-year PFS of patients with

positive c-kit was 72.2% (95% CI, 54.6-89.8), and 56.6% (95% CI, 31.2-82.1) for those with negative c-kit expression ($p=0.12$; Figure 2).

Discussion

So far, there has been no significant breakthrough in the treatment of cisplatin-refractory TGCTs in the era of targeted therapies. Only few of the recently developed molecules have been studied in TGCTs patients, which failed to yield the intended results. Along with c-kit, studies targeting all-trans retinoic acid (ATRA), epidermal growth factor receptor (EGFR), platelet-de-

Table 3. Univariate analysis of patients with TGCTs for progression-free survival according to clinicopathological characteristics

Characteristics	No. of patients	No. of events	5-year PFS rate (%) (months)	p value
All patients	61	15	76.5	
Histology				
Non-seminoma	38	12	70	
Seminoma	23	3	91	0.07
Markers				
Normal	27	4	87	
High	34	11	67	0.08
Tumor stage				
Ia	30	3	93	
Ib	31	12	67	0.01
Lymph node metastasis				
Absent	37	6	85	
Present	24	9	63	0.04
LDH				
Normal	42	9	82	
High	18	6	72	0.33
IGCCCG score:				
Good	43	6	90	
Intermediate	13	4	70	
Poor	5	4	20	0.0001
CD 117				
Negative	15	6	57	
Positive	46	9	83	0.12

LDH: Lactate dehydrogenase, IGCCCG: International Germ Cell Cancer Collaborative Group, PFS: progression-free survival

rived growth factor receptor (PDGFR), vascular endothelial growth factor (VEGF), RET, MET, cyclin-dependent kinase 4/6, and CD30 are rather predominant [17-26]. It seems that only sunitinib, tivantinib and pazopanib showed some promising results [27-29].

Downregulated c-kit expression plays a significant role in oocytes' transition to meiosis as well as the determination of male gonocytes, and this process is required for the survival and proliferation of germ cells [15].

c-kit (CD 117 protooncogene) is expressed in higher levels in seminoma in comparison to non-seminoma cases. Our study determined positive c-kit expression in 100% of seminoma pa-

tients whereas this ratio was 59% for non-seminoma patients. Such values are consistent with those reported by other studies in the literature [15,29,30]. However, we still do not know what accounts for the difference. Examination of NSGCT patients revealed no c-kit expression in any of the 7 embryonal carcinoma cases, which was also consistent with the literature [30]. c-kit expression may enable correct identification for TGCTs patients who often pose challenges for making molecular and histopathological distinctions. Imatinib is a small inhibitor molecule that is highly selective for c-kit and PDFGR tyrosine kinases. Its effectiveness has been proven for the treatment of Philadelphia chromosome-positive chronic myelogenous leukemia

and gastrointestinal stromal tumors (GISTs) [31,32]. Phase II studies, which investigated the effectiveness of imatinib in TGCTs patients, have failed to provide positive results [33,34]. The effectiveness of imatinib is associated with c-kit mutation. While exon 11 mutation is associated with good response to imatinib, treatment fails in the case of exon 17 mutation. Among patients with TGCTs, those with seminoma in particular display exon 17 mutation, which is considered to be the most important reason for the failure of studies employing imatinib [35,36]. Only two case reports reported seminoma with c-kit expression responding fully to imatinib [37,38]. Therefore, including patients according to c-kit exon mutation in studies planned for patients with TGCTs may reveal the effectiveness of imatinib.

The prognostic importance of c-kit expression has not been found statistically significant in our study. However, we believe that c-kit expression, in numerical terms, can be considered as a good prognostic factor for patients with TGCTs. The fact that all seminoma cases displayed positive c-kit expression is what we think to have driven the present results.

Although 5-year PFS rate was statistically higher for patients with good prognosis according to IGCCCG risk classification, c-kit expression was

not statistically significant among the patients categorized according to this classification. The limited patient population in our study was considered to be an important factor in this regard. Patients with seminoma have better prognosis and respond better to cisplatin-based regimens. Imatinib could be a good choice for first line therapy for suitable patients with seminoma or in case of relapse, offering an effective treatment and protecting patients against the detrimental effects of chemotherapy.

Conclusion

TGCTs are malignant tumors with distinct molecular characteristics and clinical behavior. Established new biologic targets contribute to the cancer treatment in molecular therapy era. So far, no useful molecular prognostic or predictive factor has been determined for the treatment and risk stratification of TGCTs. Such factors are required for individualized treatment approach, and given the prevalence of TGCTs among young individuals, they could decrease morbidity and prevent complications from late side-effects of chemotherapy. In the age of targeted therapies, the treatment of GCTs needs further development, which calls for well-designed and organized clinical trials.

References

- Oosterhuis JW, Looijenga LH. Testicular germ-cell tumors in a broader perspective. *Nat Rev Cancer* 2005;5:210-222.
- Chieffi P. Molecular targets for the treatment of testicular germ cell tumors. *Mini- Rev Med Chem* 2007;7:755-759.
- Curado MP, Edwards B, Shin R et al. (Eds): *Cancer Incidence in Five Continents*. Vol IX. IARC Scientific Publication 2007, No.160.
- Chieffi P, Franco R, Portella G. Molecular and cell biology of testicular tumors. *Int Rev Cell Mol Biol* 2009;278:277-308.
- Einhorn LH, Donohue J. Cis-diamminedichloroplatinum, vinblastine, and bleomycin combination chemotherapy in disseminated testicular cancer. *Ann Intern Med* 1977;87:293-298.
- Feldman DR, Bosl GJ, Sheinfeld J, Motzer RJ. Medical treatment of advanced testicular cancer. *JAMA* 2008;299:672-684.
- International Germ Cell Consensus Classification: a prognostic factor-based staging system for metastatic germ cell cancers. *International Germ Cell Cancer Collaborative Group. J Clin Oncol* 1997;15:594-603.
- Van Dijk MR, Steyerberg EW, Habbema JD. Survival of non-seminomatous germ cell cancer patients according to the IGCC classification: an update base meta-analysis. *Eur J Cancer* 2006;42:820-826.
- Veenstra CM, Vaughn DJ. Third-line chemotherapy and novel agents for metastatic germ cell tumors. *Hematol Oncol Clin N Am* 2011;25:577-591.
- Chen SQ, Xiong AQ. The progress and implication of stem cell factor. *Basic Med Sci Clin* 2002;22:385-390.
- Philo JS, Wen J, Wypych J et al. Human Stem Cell Factor Dimer Forms a Complex with Two Molecules of the Extracellular Domain of Its Receptor, Kit. *J Biol Chem* 1996;271:6895-6902.
- Jeng YM, Lin CY, Hsu HC. Expression of the c-kit protein associated with certain subtypes of salivary gland carcinoma. *Cancer Lett* 2000;154:107-111.
- Yarden Y, Kuang WJ, Yang-Feng T et al. Human proto-oncogene c-kit: A new cell surface receptor tyrosine kinase for an unidentified ligand. *EMBO J* 1987;6:3341-3351.
- Lennartsson J, Rönstrand L. Stem cell factor recep-

- tor/c-Kit: from basic science to clinical implications. *Physiol Rev* 2012;92:1619-1649.
15. Sette C, Dolci S, Geremia R, Rossi P. The role of stem cell factor and of alternative c-kit gene products in the establishment, maintenance and function of germ cells. *Int J Dev Biol* 2000;44:599-608.
 16. Mauduit C, Hamamah S, Benahmed M. Stem cell factor/c-kit system in spermatogenesis. *Hum Reprod Update* 1999;5:535-545.
 17. Moasser MM, Motzer RJ, Khoo KS et al. All-transretinoic acid for treating germ cell tumors. In vitro activity and results of a phase II trial. *Cancer* 1995;76:680-686.
 18. Moroni M, Veronese S, Schiavo R et al. Epidermal growth factor receptor expression and activation in non seminomatous germ cell tumors. *Clin Cancer Res* 2001;7:2770-2775.
 19. Kollmannsberger C, Pressler H, Mayer F, Kanz L, Bokemeyer C. Cisplatin- refractory, HER2/neu-expressing germ cell cancer: induction of remission by the monoclonal antibody trastuzumab. *Ann Oncol* 1999;10:1393-1394.
 20. Oechsle K, Honecker F, Cheng T et al. Preclinical and clinical activity of sunitinib in patients with cisplatin-refractory or multiply relapsed germ cell tumors: a Canadian Urologic Oncology Group/German Testicular Cancer Study Group Cooperative Study. *Ann Oncol* 2011;22:2654-2660.
 21. Voigt W, Kegel T, Maher G, Jordan K, Muller L, Schmoll HJ. Bevacizumab plus high-dose ifosfamide, etoposide and carboplatin (HD-ICE) as third-line salvage chemotherapy induced an unexpected dramatic response in highly platinum refractory germ-cell cancer. *Ann Oncol* 2006;17:531-533.
 22. Jain A, Brames MJ, Vaughn DJ, Einhorn LH. Phase II clinical trial of oxaliplatin and bevacizumab in refractory germ cell tumors. *Am J Clin Oncol* 2014;37:450-453.
 23. Chevalier N, Barlier A, Roche C et al. RET gene mutations are not involved in the origin of human testicular seminoma. *Int J Androl* 2010;33:848-852.
 24. Ricci G, Catizone A. Pleiotropic Activities of HGF/c-Met System in Testicular Physiology: Paracrine and Endocrine Implications. *Front Endocrinol (Lausanne)* 2014;5:38 (Review).
 25. Vaughn DJ, Gallagher M, Lal P et al. Interim results of phase II trial of the cyclin- dependent kinase 4/6 inhibitor PD-0332991 in refractory retinoblastoma protein positive germ cell tumors. *J Clin Oncol* 2012;30:(Suppl):abstr 4596.
 26. Albany C, Feldman DR, Garbo LE et al. Antitumor activity of brentuximab in CD30 positive refractory germ cell tumors. *J Clin Oncol* 2013;31:(Suppl):abstr 327.
 27. Feldman DR, Turkula S, Ginsberg MS et al. Phase II trial of sunitinib in patients with relapsed/refractory germ cell tumors. *Invest New Drugs* 2010;28:523-528.
 28. Feldman DR, Einhorn LH, Quinn DI et al. A phase 2 multicenter study of tivantinib (ARQ197) monotherapy in patients with relapsed or refractory germ cell tumors. *Invest New Drugs* 2013;31:1016-1022.
 29. Madani A, Kemmer K, Sweeney C et al. Expression of KIT and epidermal growth factor receptor in chemotherapy refractory non-seminomatous gem-cell tumors. *Ann Oncol* 2003;14:873-880.
 30. Lau SK, Weiss LM, Chu PG. D2-40 immunohistochemistry in the differential diagnosis of seminoma and embryonal carcinoma : a comparative immunohistochemical study with KIT (CD117) and CD30. *Mod Pathol* 2007;20:320-325.
 31. Druker BJ, Talpaz M, Resta DJ et al. Efficacy and safety of a specific inhibitor of the BCR-ABL tyrosine kinase in chronic myeloid leukemia. *N Engl J Med* 2001;344:1031-1037.
 32. DeMetri GD, vonMehren M, Blanke CD et al. Efficacy and safety of imatinib mesylate in advanced gastrointestinal stromal tumors. *N Engl J Med* 2002;347:472-480.
 33. Einhorn LH, Brames MJ, Heinrich MC, Corless CL, Madani A. Phase II study of imatinib mesylate in chemotherapy refractory germ cell tumors expressing KIT. *Am J Clin Oncol* 2006;29:12-15.
 34. Piulats JM, Garcíadel Muro X, Huddart R. Phase II multicenter study of imatinib in patients with refractory germ cell tumors that express c-kit. *Proc Am Assoc Cancer Res* 2007;48:2648.
 35. Kemmer K, Corless CL, Fletche JA et al. KIT mutations are common in testicular seminomas. *Am J Pathol* 2004;164:305-313.
 36. Kollmannsberger C, Mayer F, Pressler H et al. Absence of c-kit and members of the epidermal growth factor receptor family in refractory germ cell cancer. *Cancer* 2002;95:301-308.
 37. Pedersini R, Vattemi E, Mazzoleni G, Graiff C. Complete response after treatment with imatinib in pre-treated disseminated testicular seminoma with overexpression of c-kit. *Lancet Oncol* 2007;8:1039-1040.
 38. Pectasides D, Nikolaou M, Pectasides E, Koumariou A, Valavanis C, Economopoulos T. Complete response after imatinib mesylate administration in a patient with chemoresistant stage IV seminoma. *Anticancer Res* 2008;28:2317-2320.