

ORIGINAL ARTICLE

Predictors determining the status of axilla in breast cancer: Where is PET/CT on that?

Huseyin Ozgur Aytac¹, Tamer Colacoglu¹, Gul Niha¹ Nursal², Tarik Zafer Nursal¹, Filiz Aka Bolat³, Hakan Yabanoglu¹, Sedat Yildirim¹, Gokhan Moray¹

¹Department of General Surgery, ²Department of Nuclear Medicine, ³Department of Pathology, Baskent University Faculty of Medicine, Ankara, Turkey

Summary

Purpose: 18 F-FDG PET/CT has an acceptable specificity but a low sensitivity on the prediction of axillary lymph node (ALN) metastasis in breast cancer. We analyzed the factors that could possibly affect this prediction.

Methods: The records of 270 patients with T1-2 invasive breast cancer who underwent surgery, 116 of whom had been evaluated by preoperative 18 F-FDG PET/CT were reviewed. Prediction of ALN status by PET/CT according to tumor stage, estrogen receptor (ER), progesterone receptor (PgR) and HER2 status, histology, age and sentinel node properties was assessed.

Results: ALN metastasis was present in 62 of 131 T1 (43.7%) and 106 of 142 T2 tumors (74.6%), 20 of 46

(43.5%) ER(-) and 146 of 222 (65.8%) ER(+) tumors, 38 of 71 (53.5%) PgR(-) and 127 of 200 (63.5%) PgR(+) tumors. On multivariate analysis only the tumor size (>2 cm) independently correlated with ALN metastasis (Odds ratio/OR=3.1). None of the other parameters had statistical significance in terms of ALN prediction on FDG-PET/CT.

Conclusion: Though T2 tumors showed increased tendency to metastasize to the axilla, prediction of ALN metastasis in preoperative FDG-PET/CT was not associated with any of the predictive factors.

Key words: axillary nodes, breast cancer, CT, FDG, PET, sentinel

Introduction

One of the most reliable predictive factors for recurrence and survival in breast cancer patients is the presence of ALN metastasis [1,2]. Despite its almost 100% diagnostic accuracy, axillary lymph node dissection (ALND) has a substantial rate of arm morbidity [3]. Hence, new developments paved the way to downsize the operations for axilla in breast cancer patients. In order to determine the status of the axilla in a less invasive manner, the technique of sentinel lymph node biopsy (SLNB) was implemented [4]. Thus, it is believed that unnecessary ALND can be avoided when sentinel node (SN) is negative in patients with clinically negative

axilla [5]. Recently, studies have shown that addition of ALND to any surgical procedure done for breast cancer does not affect overall survival and even local disease control [5-7]. Some authors point to the needlessness of ALND for local control even when the axilla is positive on the basis of effective radiotherapy [8,9]. Therefore, reliable information about the axillary status obtained prior to surgery may determine the decision of performing ALND and even SNLB.

Efforts for predicting the axillary status are warranted and still ongoing. For breast cancer, such a heterogeneous disease in terms of harboring cells with different biologic and molecu-

lar markers, the potential of ALN metastasis has been investigated in several studies regarding its relation with many possible predictive factors.

One of the promising imaging techniques used for staging breast cancer is Fluorine-18-labeled 2fluoro-2-deoxy-D-glucose positron emission tomography with computerized tomography (FDG-PET/CT) that provides valuable information about extra-axillary nodal status and the presence of distant metastases [10]. Although FDG-PET/CT is not an imaging technique designed for lymph node investigation, it may give considerable information about the regional nodal status when interpreted correctly. Additionally, if FDG-PET/CT can accurately and noninvasively stage the axilla, as well as the currently unevaluated internal mammary and supraclavicular nodes, it could essentially change the management of many patients with breast cancer.

There are numerous studies analyzing the relationship between axillary nodal status and FDG-PET/CT findings [11,12]. Some papers investigate the diagnostic value of FDG-PET/CT by comparing breast tumor images with prognostic criteria such as tumor size, histopathological findings and hormonal status [13]. Ekmekcioglu et al. demonstrated that high maximum standardized uptake values (SUVmax) of tumors on FDG-PET/CT images correlate with other risk factors and serve as a predictive indicator [14]. Yet, it is still questionable whether prognostic factors regarding the tumor affect the accuracy of FDG-PET/CT in predicting axillary metastases in terms of SUVmax of the axilla as no available study exists to investigate the relationship between the prognostic factors and SUVmax of the axilla. Thus, studies demonstrating the relationship between risk factors and FDG-PET/CT findings regarding the axilla are needed.

The purpose of this study was to demonstrate the role of preoperative FDG-PET/CT imaging on predicting axillary metastasis according to SUVmax of the axilla and prognostic factors influencing this prediction. Therefore, we performed a retrospective analysis to assess the acuity of FDG-PET/CT as a technique for ALN staging comparing with the pathologic findings of ALNs as the reference standard, as well as demonstrating independent predictive factors for ALN metastasis.

Methods

Data of patients who underwent surgery for invasive breast cancer within the last three years at Baskent University Adana Training and Research Hospital were

examined retrospectively. This study was designed and executed after the approval of Baskent University Clinical Researches and Ethics Committee with the project number KA13/188.

Patients operated on for T1 and T2 tumors according to the Cancer Staging Manual of the American Joint Committee on Cancer [15] were enrolled in the study. Patients having had neoadjuvant hormone therapy or chemotherapy and who were currently pregnant were excluded. From May 2011 to June 2014, 270 patients with T1 (≤ 20 mm) or T2 (>20 but ≤ 50 mm) tumors were operated on for breast cancer, 3 of whom had been operated on for bilateral breast cancers, creating 273 individual cases. Data were first classified into two main patient groups: those with SLNB (and ALND if necessary) and those with ALND (without SLNB) (Figure 1). Data were combined in a united group for the assessment of sentinel and non-sentinel ALN metastasis eventually. All the patient data contained pathological breast cancer diagnosis obtained preoperatively by core biopsies.

The SLNB procedure was performed using either blue dye or both ^{99m}Tc sulfur colloid and blue dye.

All blue and/or radioactive lymph nodes were considered as SLN. Simultaneous ALND was performed when metastases were detected in SLNs.

Pathological examinations were done by a specialist team for all cases. SLNs were sliced for touch imprint and for frozen section examination and then fixed in formalin and embedded in paraffin for hematoxylin & eosin (H&E) staining and examination. Non-sentinel nodes were fixed in formalin and embedded in paraffin also for H&E examination. Immunohistochemistry using cytokeratin antibody was performed to the samples negative in the H&E examination. Metastatic lymph nodes were classified according to the size of metastatic deposit as macrometastases (tumor deposits ≥ 2 mm in diameter) or micrometastases (0.2-2 mm in diameter) or cell clusters or isolated tumor cells (<0.2 mm in diameter). ER and PgR staining was scored as positive or negative with a cut-off of 10 % nuclear immunostaining. HER2 was evaluated according to the American Society of Clinical Oncology guidelines [16].

Statistics

Effects of clinicopathological factors like tumor size, ER, PgR and HER2 status, age and histologic subtype, SN labeling method, number of SNs excised and mean diameter of SN on predicting ALN metastasis and estimation of nodal involvement by FDG-PET/CT imaging according to SUVmax of the axilla were assessed using chi-square and Fisher exact tests in the univariate analysis. Mann-Whitney U test was used to compare data lacking normal distribution. Statistically significant predictive factors for ALN metastasis in the univariate analysis were included in a multivariate analysis using logistic regression model. The relation between age and ALN status was assessed by ROC curve

analysis and no statistical significance was observed when age was evaluated either as a continuous or a categorical variable. Therefore, patients were evaluated in two groups according to their age, whether younger or older than the median age value. The most suitable SUVmax cut-off for axillary positivity was assessed by ROC curve analysis. Also a second SUVmax cut-off, which has been commonly accepted in the literature was also subjected to logistic regression analysis [17]. All tests of significance were two-sided and a p value <0.05 was considered statistically significant. Sensitivity and specificity values with AUC for FDG-PET CT and SLNB were calculated. SPSS software (version 20.0, SPSS, Chicago, IL, USA) was used for analyses.

Results

The clinicopathological characteristics of 143 cases with clinically negative axilla treated by SLNB and consequent ALND if necessary (SLNB group) and 130 cases treated by ALND without SLNB due to clinically positive axilla (ALND group) are summarized in Table 1. Regardless of the type of axillary approach, surgical modalities selected were lumpectomy or mastectomy with or without immediate reconstruction.

Axillary metastasis (sentinel or non-sentinel) was observed in 61.5% of the cases either by SLNB, ALND or both.

The mean tumor size was 20±11 mm (range, 2-50) in the SLNB group and 20±10.5 mm (range 9-50) in the ALND group. Both SN and non-SN positivity were more frequent in patients with T2 tumors in SLNB and ALND groups and in a third group that included all the SLNB and ALND groups (united group) (Table 2).

Univariate analysis demonstrated that ER positivity was correlated with nodal positivity in the SLNB group and the united group but not in ALND group. PgR positivity was correlated with nodal positivity only in the united group but not in SLNB or ALND groups. HER2 status was not correlated with nodal positivity in either of the groups (Table 2).

The frequencies of histologic types were similar in both SNLB and ALND groups (Table 1). Actually, there were only 5 patients with pure lobular carcinomas, 2 in SLNB group and 3 in ALND group. Because of the inadequacy for statistical analysis, these 5 cases with lobular histology were analyzed within the rest 24 cases with mixed ductal and lobular histology (generating the term “carcinomas with lobular components”). The likelihood of SN positivity in the SLNB group was higher for carcinomas with

Table 1. Patient demographics and tumor characteristics according to SLNB and ALND groups

Characteristics	SLNB group	ALND group
Total cases	143	130
Age (years)		
Median (range)	49 (24-85)	50.6 (30-75)
Tumor stage, N (%)		
T1	69 (48.3)	62 (47.7)
T2	74 (51.7)	68 (52.3)
Histologic type of cancer, N (%)		
Infiltrating ductal	126 (88.1)	118 (90.8)
Infiltrating lobular	2 (1.4)	3 (2.3)
Mixed infiltrating	15 (10.5)	9 (6.9)
Maximum tumor size (mm)		
Median (range)	20 (2-50)	20 (9-50)
Hormone receptor status, N (%)		
ER-	26 (18.2)	20 (16)
ER+	117 (81.8)	105 (84)
PgR-	36 (26.3)	35 (28.2)
PgR+	101 (73.7)	89 (71.8)
HER2-	30 (22.1)	30 (24.4)
HER2+	106 (77.9)	93 (75.6)

lobular components and the ALN positivity in the ALND group was higher for ductal carcinomas. No difference was seen in terms of nodal positivity among histologic types in the united group (Table 2). The median age was similar in both SLNB and ALND groups (Table 1). Axillary involvement was more frequent in younger individuals (less than 50 years) in the ALND group but not in the SLNB and the united group (Table 2).

Blue dye and ^{99m}Tc sulfur colloid were used in combination for SN labeling in 15 (10%) patients.

Analysis did not show any significant differ-

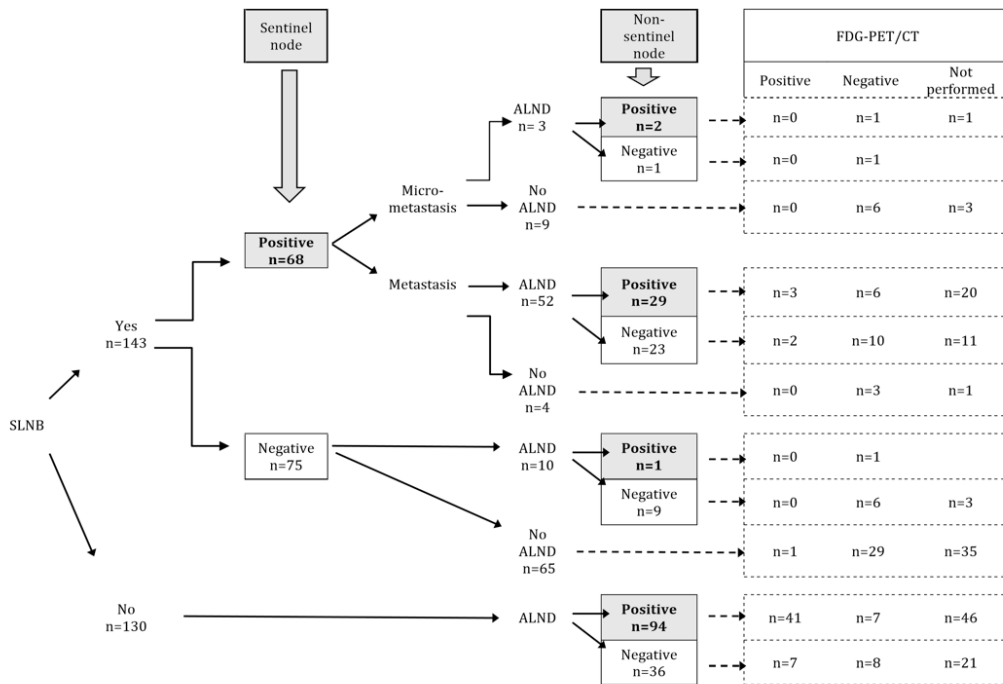


Figure 1. Diagram showing evaluation of cases according to SLNB and ALND and their relation with PET/CT FDG uptake (SUVmax>2.5 is considered as positive).

ence in SN positivity with either labeling method (Table 2). The mean number of SNs harvested was 3 and the mean diameter was 15.3 mm; both parameters were shown not to affect ALN positivity.

SN metastasis was observed in 68 (47.5%) of 143 patients. Axillary dissection was performed in 55 of the latter 68 patients with positive SNs and in 10 of the 75 patients with negative SNs. Among these 10 patients who were subjected to axillary dissection despite negative SNs, one (1.3%) had metastatic node in her axilla, which was not detected by FDG-PET/CT. Among 31 (56.3%) patients without SN metastasis despite positive SNs (2 cases with micrometastasis), FDG-PET/CT was performed in 10 cases. FDG-PET/CT detected metastasis in 3 out of 10. Among 24 patients with positive SNs but negative non-sentinel ALNs (one micrometastasis and 23 metastases) FDG-PET/CT was performed in 13 patients an metastasis was detected in 2 of them (Figure 1).

SNs of 13 patients were reported as negative by frozen section and corrected as positive after definite pathological studies, hence these patients were deprived of axillary dissec-

tion. Nine (69%) of the latter 13 patients with false-negative SN results were demonstrated to have micrometastasis and 4 (31%) to have macrometastasis on definite studies. The false negative ratio of frozen section was calculated as 13% for micrometastasis and 5.8% for macrometastasis with an overall ratio of 9% and negative predictive value of 85%. Among the 68 patients with positive SNs 12 (22%) had micrometastatic and 56 (88%) had macrometastatic SNs. ALN dissection was carried out in 3 of these 12 patients (false-negative result in the rest 9) with micrometastatic SNs, of which 2 (67%) had non-sentinel axillary macrometastasis. Pathologic precision of frozen examination for SNs has a sensitivity of 79% and a specificity of 100% with 90% accuracy. SLNB procedure correctly predicted non-sentinel axillary status in 40 of 55 (72.7%) patients to whom ALND was performed. The mean number of ALNs dissected was 20 and the mean number of metastatic ALNs obtained was 8.7 in the ALND group. ALN metastasis was observed in 94 of 130 (72%) patients in the ALND group, of which FDG-PET/CT determined 41 out of 46 (Figure 1).

One hundred and sixteen cases were ex-

Table 2. Relation of tumor characteristics and sentinel and non-sentinel axillary nodal status according to univariate and multivariate logistic regression analysis (variables in the equation)

	Any axillary node (sentinel or non-sentinel) in SLNB group		p	Axillary node in ALND group		p	Any axillary node (sentinel or non-sentinel) in United group		p	Multivariate logistic regression parameters		p
	Negative	Positive		Negative	Positive		Negative	Positive		B	Exp(B)	
Tumor stage												
T1	48	21		21	41		69	62		-1.276	0.279	0.016
T2	27	47	<0.001	9	59	<0.001	36	106	<0.001			
Hormone receptor status												
ER -	19	7		7	13		26	20				
ER +	56	61	0.02	20	85	0.112	76	146	0.005	-1.160	0.514	0.176
PgR -	22	14		11	24		33	38				
PgR +	48	53	0.16	15	74	0.073	63	127	0.047	-0.524	0.723	0.674
HER2 -	18	12		5	25		23	37				
HER2 +	51	55	0.25	20	73	0.567	71	128	0.7	-0.288	0.750	0.626
Histologic type												
Infiltrating ductal carcinomas	70	56		23	95		93	151				
Infiltrating carcinomas with lobular component	5	12	0.043	7	5	0.006	12	17	0.7	0.319	1.376	0.7
Age (y)												
< 50	48	35		10	62		58	97				
≥ 50	27	33	0.089	20	38	0.006	47	71	0.6	0.098	1.103	0.845
SUVmax value of axillary nodes on FDG-PET/CT												
< 1	15	20		6	3		21	22				
≥ 1	10	8	0.380	9	46	<0.001	19	54	0.013	-0.491	0.612	0.361
< 2.5	24	23		12	19		36	42				
≥ 2.5	1	5	0.112	3	29	0.006	4	34	<0.001	-2.431	0.088	0.005
SN labeling method												
Blue dye	68	59										
Blue dye + ^{99m} Tc	7	8	0.614									
Mean number of SN excised	2.97	3.15	0.219									
Mean diameter of the maximum SN (mm)	15	15.61	0.555									

amined with FDG-PET/CT. ROC curve analysis determined the best SUVmax cut-off of axillary nodes as 1.6, with a sensitivity of 56% and specificity of 83%. When SUVmax cut-off was estimated as 2.5, sensitivity and specificity were 42% and 90%, respectively (AUC 0.715).

Axillary nodal status according to tumor size, age, histologic subtype, diameter of largest node on FDG-PET/CT, ER, PgR and HER2 status are summarized in Table 2. Larger tumor size ($p < 0.001$), ER positivity ($p = 0.005$) and PgR positivity ($p = 0.047$) were shown to be proportional with axillary nodal positivity, whereas age, HER2 status and histologic type were not (Table 2). Multivariate logistic regression analysis demonstrated that only large tumor size was independently correlated with presence of ALN metastasis with an OR of 3.1 (95% CI 1.1-8.3). However, none of the above mentioned parameters had statistical significance in terms of axillary nodal prediction on FDGPET/CT with either SUVmax cut-off. Yet, logistic regression analysis also showed that, when SUVmax value of ALNs on FDG-PET/CT was above 2.5, the probability of axillary (SN or non-SN) metastasis increased significantly with an OR of 14 (95% CI 2.8-70.1) (Table 2).

Discussion

Presence of metastasis in ALNs is one of the most important determinants for prognosis of breast cancer. This makes information about the axillary status critical for treatment planning. Tumor size, hormone receptors and HER2 status and histologic type are the other known prognostic factors in breast cancer [2]. FDG-PET/CT is an imaging method often used for preoperative staging. Our aim was to demonstrate the diagnostic value of preoperative FDG-PET/CT on axillary status, considering also the effects of the accompanying prognostic factors in terms of their predictive value.

In this retrospective study, we showed that more than half of the women with early breast cancer have axillary metastasis at the time of diagnosis. We also demonstrated that breast cancer tends to metastasize to the axilla when the tumor is larger than 2 cm in diameter regardless of its histologic type, ER, PgR and HER2 status, patient age and diameter of the axillary lymph nodes. Our data also suggested that FDG-PET/CT imaging on predicting axillary metastasis has a low sensitivity (56%) but high speci-

ficity (90%) and none of the prognostic factors mentioned above affects this prediction. Tumor characteristics other than tumor size and HER2 status had different influences on ALN positivity in SNLB, ALND or united groups in univariate but not in multivariate analysis in our study. Confirming other studies, we found that the most significant predictive indicator of axillary lymph node involvement for patients with breast cancer is the tumor size [18-22]. However, we noticed that, in contrast with our results, there are some studies showing non-correlation between the primary tumor size and axillary status [23-26].

In some previous studies dealing with the relation between hormonal and SN status, ER and PgR negative status was shown to be associated with low risk of ALN metastasis [21,27]. Positive expressions of ER and PgR have been previously shown to be significantly correlated with histological grade, mitotic score and nuclear pleomorphism [28]. This can explain why ER and PgR positive tumors tend to metastasize to the axilla more frequently. In contrast, there are articles mentioning disproportion of ER and PgR status with axillary metastasis [26,29-32], while some authors demonstrated an inverse relationship, reporting that ER and PgR positive tumors metastasize less frequently to the axilla [27]. Our results also confirmed that ALN positivity was not related with ER or PgR status.

HER2 overexpressing breast cancers are known to be more aggressive with an increased locoregional recurrence rate unless treated with trastuzumab [33]. Crabb et al. specified HER2 as an independent predictor of nodal involvement in a retrospective analysis of 3,441 early-stage breast cancer cases [34]. Gulben et al. published a similar result in a study where they investigated cases according to pathologic subtypes [21]. On the contrary, confirming many of the studies in the literature, we showed that HER2 status is not a predictor of axillary metastasis [30,35,36]. To clarify this conflict it may be speculated that HER2-positive breast cancers, known to be more aggressive, perhaps tend to metastasize via the hematogenous route rather than lymphatic.

Currently, there is a bit compromise over the effect of histologic type of breast cancer on ALN status in the literature. For instance, Aitken et al. demonstrated that lobular and mixed breast cancers are much prone to axillary metastasis [30], Tan et al. showed that ductal can-

cers are more likely to have positive ALNs [37]. This may be because of the fact that nodal metastases are more commonly overlooked in lobular cancers [38]. No correlation between nodal status and histologic type was noticed in our study. Nonetheless, our results comparing histologic type and axillary status may not evoke trust as lobular carcinomas were evaluated in the same group with mixed carcinomas.

Younger age was shown to be a risk factor for axillary metastasis in some previous studies [33,39]. On the contrary, in a study with 3553 cases, Purushotham et al. pointed out that older patients have much tendency to distant metastasis [40]. We demonstrated a disproportion of axillary metastasis and patient age.

No statistical difference was observed in terms of ALN positivity between SN labeling techniques in this study. This result seems to correlate with previous studies [41]. The number and size of the SN excised were also shown not to affect ALN positivity.

We demonstrated that FDG-PET/CT has low sensitivity but high specificity in predicting the ALN status, similar with other authors [42].

There are papers in the literature claiming direct correlation between the tumor size and ALN positivity on FDG-PET/CT [12,43,44]. In a study of the Ontario Oncology Group, tumor size was found to be a predictive factor, affecting the sensitivity of FDG-PET/CT in the axillary status [45]. Metabolic correlation of molecular subtypes according to hormonal status of breast cancer with tumor SUV on FDG-PET/CT has been demonstrated in several studies [46,47]. Kim et al. recently showed that subgrouping breast cancer patients according to hormone

and HER types may affect the correlation of tumor SUV with ALN metastasis [48]. We couldn't find any studies designed to assess the effect of ER, PgR and HER2 status or histology of breast cancer on the predictive value of FDG-PET/CT regarding the SUVmax of the axilla, to compare with our results. We observed that prediction of ALN status on FDG-PET/CT is not influenced by tumor size, axillary node diameter or any other predictive risk factors mentioned above.

Because of the retrospective nature of this study with a lack of completion ALND in all SLNB cases, we could not compare the efficacy of SLNB procedure and preoperative FDG-PET/CT on estimating the axillary status. Nevertheless, we can state that despite its valuable place in diagnosing nonaxillary nodes and distant metastases, as well as accompanying second malignancies, FDG-PET/CT has a low value for predicting axillary status regardless of concomitant predictive factors of breast cancer. FDG-PET/CT may help identify patients with high ALN involvement in order to canalize directly to ALND, omitting the SLNB step. However, FDG-PET/CT cannot replace SLNB or ALND due to its insufficient sensitivity. To our knowledge, this is the first study to investigate the role of almost all common predictive risk factors of breast cancer together in the diagnostic capacity of FDG-PET/CT in the prediction of axillary status according to SUVmax of axillary nodes.

Acknowledgement

We would like to thank Mrs Cagla Sariturk for her support in the assessment of the statistical analysis of our study.

References

- Carter CL, Allen C, Henson DE. Relation of tumor size, lymph node status, and survival in 24,740 breast cancer cases. *Cancer* 1989;63:181-187.
- Cianfrocca M, Goldstein LJ. Prognostic and predictive factors in early-stage breast cancer. *The Oncologist* 2004;9:606-616.
- Kwan W, Jackson J, Weir LM, Dingee C, McGregor G, Olivotto IA. Chronic arm morbidity after curative breast cancer treatment: prevalence and impact on quality of life. *J Clin Oncol* 2002;20:4242-4248.
- Chao C, McMasters K. The current status of sentinel lymph node biopsy for breast cancer. *Adv Surg* 2002;36:167-192.
- Krag DN, Anderson SJ, Julian TB et al. Sentinel-lymph-node resection compared with conventional axillary-lymph-node dissection in clinically node-negative patients with breast cancer: overall survival findings from the NSABP B-32 randomised phase 3 trial. *Lancet Oncol* 2010;11:927-933.
- Crawford JD, Ansteth M, Barnett J, Glissmeyer M, Johnson NG. Routine completion axillary lymph node dissection for positive sentinel nodes in patients undergoing mastectomy is not associated with improved local control. *Am J Surg* 2013;205:581-584; discussion 584.
- Giuliano AE, Hunt KK, Ballman KV et al. Axillary dissection vs no axillary dissection in women with invasive breast cancer and sentinel node metastasis: a randomized clinical trial. *JAMA* 2011;305:569-575.
- Offersen BV, Nielsen HM, Overgaard M, Overgaard J. Is regional nodes radiotherapy an alternative to surgery? *Breast* 2013;22 (Suppl 2):S118-128.
- Ahmed M, Douek M. What is the future of axillary surgery for breast cancer? *E cancer medical science* 2013;7:319.
- Liu Y. Role of FDG PET-CT in evaluation of locoregional nodal disease for initial staging of breast cancer. *World J Clin Oncol* 2014;5:982-989.
- Wahl RL, Siegel BA, Coleman RE, Gatsonis CG, Group PETS. Prospective multicenter study of axillary nodal staging by positron emission tomography in breast cancer: a report of the staging breast cancer with PET Study Group. *J Clin Oncol* 2004;22:277-285.
- Fuster D, Duch J, Paredes P, et al. Preoperative staging of large primary breast cancer with [18F]fluorodeoxyglucose positron emission tomography/computed tomography compared with conventional imaging procedures. *J Clin Oncol* 2008;26:4746-4751.
- Sanli Y, Kuyumcu S, Ozkan ZG et al. Increased FDG uptake in breast cancer is associated with prognostic factors. *Ann Nucl Med* 2012;26:345-350.
- Ekmekcioglu O, Aliyev A, Yilmaz S et al. Correlation of 18F-fluorodeoxyglucose uptake with histopathological prognostic factors in breast carcinoma. *Nucl Med Commun* 2013;34:1055-1067.
- Edge SB, Compton CC. The American Joint Committee on Cancer: the 7th edition of the AJCC cancer staging manual and the future of TNM. *Ann Surg Oncol* 2010;17:1471-1474.
- Wolff AC, Hammond ME, Schwartz JN et al. American Society of Clinical Oncology/College of American Pathologists guideline recommendations for human epidermal growth factor receptor 2 testing in breast cancer. *J Clin Oncol* 2007;25:118-145.
- Straver ME, Aukema TS, Olmos RA et al. Feasibility of FDG PET/CT to monitor the response of axillary lymph node metastases to neoadjuvant chemotherapy in breast cancer patients. *Eur J Nucl Med Mol Imaging* 2010;37:1069-1076.
- Houvenaeghel G, Nos C, Mignotte H et al. Micrometastases in sentinel lymph node in a multicentric study: predictive factors of nonsentinel lymph node involvement--Groupe des Chirurgiens de la Federation des Centres de Lutte Contre le Cancer. *J Clin Oncol* 2006;24:1814-1822.
- Cox CE, Bass SS, McCann CR et al. Lymphatic mapping and sentinel lymph node biopsy in patients with breast cancer. *Annu Rev Med* 2000;51:525-542.
- Cox CE, Kiluk JV, Riker AI et al. Significance of sentinel lymph node micrometastases in human breast cancer. *J Am Coll Surg* 2008;206:261-268.
- Gulben K, Berberoglu U, Aydogan O, Kinas V. Subtype is a predictive factor of nonsentinel lymph node involvement in sentinel node-positive breast cancer patients. *J Breast Cancer* 2014;17:370-375.
- Yoshihara E, Smeets A, Laenen A et al. Predictors of axillary lymph node metastases in early breast cancer and their applicability in clinical practice. *Breast* 2013;22:357-361.
- Gutierrez J, Dunn D, Bretzke M et al. Pathologic evaluation of axillary dissection specimens following unexpected identification of tumor within sentinel lymph nodes. *Arch Pathol Lab Med* 2011;135:131-134.
- Viale G, Maiorano E, Pruneri G et al. Predicting the risk for additional axillary metastases in patients with breast carcinoma and positive sentinel lymph node biopsy. *Ann Surg* 2005;241:319-325.
- Rahusen FD, Torrenga H, van Diest PJ et al. Predictive factors for metastatic involvement of nonsentinel nodes in patients with breast cancer. *Arch Surg* 2001;136:1059-1063.
- Ashturkar AV, Pathak GS, Deshmukh SD, Pandave HT. Factors predicting the axillary lymph node metastasis in breast cancer: is axillary node clearance indicated in every breast cancer patient?: factors predicting the axillary lymph node metastases in breast cancer. *Indian J Surg* 2011;73:331-335.
- Viale G, Zurrida S, Maiorano E et al. Predicting the status of axillary sentinel lymph nodes in 4351 patients with invasive breast carcinoma treated in a single institution. *Cancer* 2005;103:492-500.
- Thike AA, Chng MJ, Fook-Chong S, Tan PH. Immunohistochemical expression of hormone receptors in invasive breast carcinoma: correlation of results of H-score with pathological parameters. *Pathology* 2001;33:21-25.

29. Ahlgren J, Stal O, Westman G, Arnesson LG. Prediction of axillary lymph node metastases in a screened breast cancer population. South-East Sweden Breast Cancer Group. *Acta Oncol* 1994;33:603-608.
30. Aitken E, Osman M. Factors affecting nodal status in invasive breast cancer: a retrospective analysis of 623 patients. *Breast J* 2010;16:271-278.
31. Chua B, Ung O, Taylor R, Boyages J. Frequency and predictors of axillary lymph node metastases in invasive breast cancer. *ANZ J Surg* 2001;71:723-728.
32. Bevilacqua J, Cody H, 3rd, MacDonald KA, Tan LK, Borgen PI, Van Zee KJ. A prospective validated model for predicting axillary node metastases based on 2,000 sentinel node procedures: the role of tumour location [corrected]. *Eur J Surg Oncol* 2002;28:490-500.
33. Lowery AJ, Kell MR, Glynn RW, Kerin MJ, Sweeney KJ. Locoregional recurrence after breast cancer surgery: a systematic review by receptor phenotype. *Breast Cancer Res Treat* 2012;133:831-841.
34. Crabb SJ, Cheang MC, Leung S et al. Basal breast cancer molecular subtype predicts for lower incidence of axillary lymph node metastases in primary breast cancer. *Clin Breast Cancer* 2008;8:249-256.
35. Gangi A, Mirocha J, Leong T, Giuliano AE. Triple-negative breast cancer is not associated with increased likelihood of nodal metastases. *Ann Surg Oncol* 2014;21:4098-4103.
36. Ugras S, Stempel M, Patil S, Morrow M. Estrogen receptor, progesterone receptor, and HER2 status predict lymphovascular invasion and lymph node involvement. *Ann Surg Oncol* 2014;21:3780-3786.
37. Tan LG, Tan YY, Heng D, Chan MY. Predictors of axillary lymph node metastases in women with early breast cancer in Singapore. *Singapore Med J* 2005;46:693-697.
38. Skinner KA, Silberman H, Sposto R, Silverstein MJ. Palpable breast cancers are inherently different from nonpalpable breast cancers. *Ann Surg Oncol* 2001;8:705-710.
39. Lee HB, Han W. Unique features of young age breast cancer and its management. *J Breast Cancer* 2014;17:301-307.
40. Purushotham A, Shamil E, Cariati M et al. Age at diagnosis and distant metastasis in breast cancer--a surprising inverse relationship. *Eur J Cancer* 2014;50:1697-1705.
41. Jung SY, Kim SK, Kim SW et al. Comparison of sentinel lymph node biopsy guided by the multimodal method of indocyanine green fluorescence, radioisotope, and blue dye versus the radioisotope method in breast cancer: a randomized controlled trial. *Ann Surg Oncol* 2014;21:1254-1259.
42. Ueda S, Tsuda H, Asakawa H et al. Utility of 18F-fluoro-deoxyglucose emission tomography/computed tomography fusion imaging (18F-FDG PET/CT) in combination with ultrasonography for axillary staging in primary breast cancer. *BMC Cancer* 2008;8:165.
43. Bellevre D, Blanc Fournier C, Switers O et al. Staging the axilla in breast cancer patients with (1)(8)F-FDG PET: how small are the metastases that we can detect with new generation clinical PET systems? *Eur J Nucl Med Mol Imaging* 2014;41:1103-1112.
44. Bernsdorf M, Berthelsen AK, Wielenga VT et al. Preoperative PET/CT in early-stage breast cancer. *Ann Oncol* 2012;23:2277-2282.
45. Pritchard KI, Julian JA, Holloway CM et al. Prospective study of 2-[(1)(8)F]fluorodeoxyglucose positron emission tomography in the assessment of regional nodal spread of disease in patients with breast cancer: an Ontario clinical oncology group study. *J Clin Oncol* 2012;30:1274-1279.
46. Garcia Vicente AM, Soriano Castrejon A, Leon Martin A et al. Molecular subtypes of breast cancer: metabolic correlation with (1)(8)F-FDG PET/CT. *Eur J Nucl Med Mol Imaging* 2013;40:1304-1311.
47. Koo HR, Park JS, Kang KW et al. 18F-FDG uptake in breast cancer correlates with immunohistochemically defined subtypes. *Eur Radiol* 2014;24:610-618.
48. Kim JY, Lee SH, Kim S, Kang T, Bae YT. Tumour 18 F-FDG Uptake on preoperative PET/CT may predict axillary lymph node metastasis in ER-positive/HER2-negative and HER2-positive breast cancer subtypes. *Eur Radiol* 2014;25:1172-1181.