

## SPECIAL ARTICLE

---

# From Fungus haematodes to Retinoblastoma

Marilita M. Moschos

1<sup>st</sup> Department of Ophthalmology, Medical School, University of Athens, Athens; Biomedical Research Foundation, Academy of Athens, Athens, Greece

### Summary

*Retinoblastoma is probably the only disease which received 40 different names until its official terminology which was adopted by the medical community in 1926. The official record of retinoblastoma was reported in 1597 by Petrus Pawius (ca. 1564-1617). The development of pathology during the 19th century gave to opportunity to clarify the his-*

*tological characteristics of the disease. Although in the past retinoblastoma was considered a fatal disease, nowadays with modern treatment the prognosis is better.*

**Key words:** amaurotic cat's eye, fungus haematodes, glioma, ocular cancer, retinoblastoma

### Introduction

Retinoblastoma (Figure 1) is probably the only disease which received 40 different names until its official terminology [1]. This fact describes the difficulties faced by the physicians to understand and define the special characteristics of this disease. Ancient Greek physicians were the first to describe malignant tumors and also introduced the term 'cancer' for these conditions [2]. But one should have in mind that the physicians in antiquity believed that cancer was a disease provoked by excess black bile which leads to the presence of tumors with or without ulcers and most of the times fatal, in every organ of the human body. The modern concept of cancer was determined only during 19<sup>th</sup> century after the studies of Rudolf Ludwig Carl Virchow (1821-1902) who described the irregular proliferation of cells in cancer [3,4]. The ancient perception for cancer allows us today to believe that only a part of the cancers described in antiquity were actually malignant tumors according

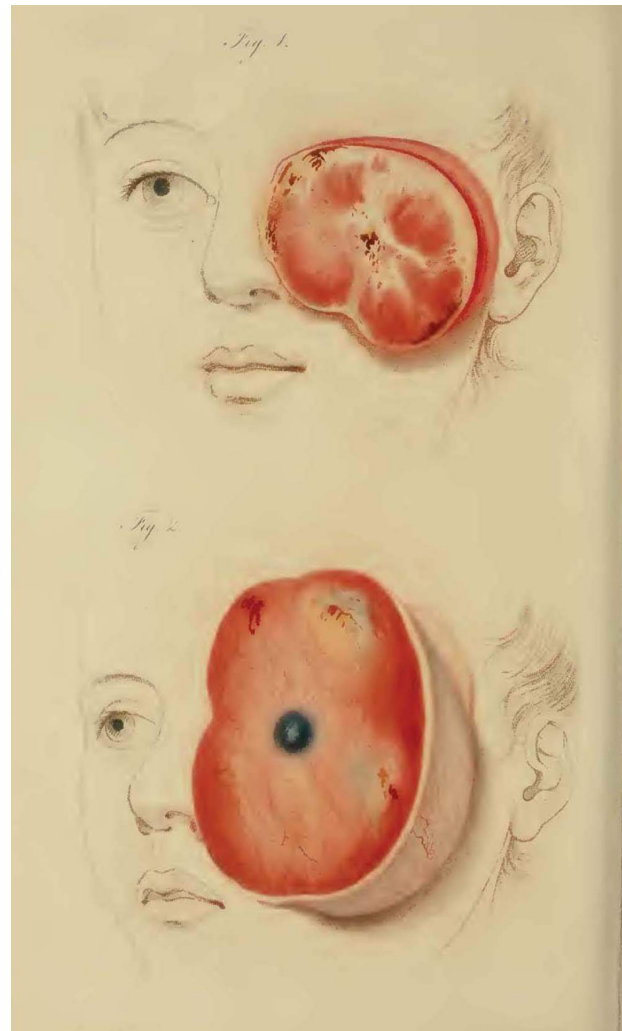
modern medicine. In addition, apart from the other organs, ancient Greek physicians described also ocular cancer. Although we do not have a specific description of retinoblastoma in ancient Greek medical literature, we should believe that this disease was not unknown in antiquity and probably the physicians of those times faced similar cases even if they are not mentioned exactly in their writings. We should also point that the terracotta figurine, now lost, which earlier belonged to Meyer-Steineg collection (Jena, Friedrich-Schiller-Universität, Institut für Geschichte der Medizin, Naturwissenschaft und Technik) which depicted a child's head with an ophthalmocoele with characteristics analogous to retinoblastoma, should not be considered the earliest representation of this disease [5,6], because modern archeology has pointed out that this is a modern forgery creation after the careful examinations of the style of the hairs and the cheeks which are unparalleled to ancient Greek art [7,8].

## Fungus haematodes - Glioma - Retinoblastoma

The history of retinoblastoma began in 1597 when Petrus Pawius (ca. 1564-1617) performed autopsy on a 3-year-old boy who died due to a huge tumor in his left eye. The tumor had caused an exophthalmos, while another tumor had appeared in his left temporal muscle. The autopsy revealed expansion of the tumor to the brain [9]. A similar incident was described in 1767 by William Hunter (1718-1783) but that time concerned a 3-year-old girl with bilateral ocular tumor. This time Hunter described the loss of the dark color of iris and the presence of clear and bright color, while it was underlined that vitreous was replaced by a white gel substance so that the physician believed that the cancer originated in the vitreous [10]. In these two examples the physicians dealt with a soft type cancer, therefore it was believed that they should be linked to soft cancers appearing in other parts of the body, while all these forms of cancers were attributed to an unspecific fungus and were included in the type of cancer then called Fungus haematodes, as proposed by William Hey (1736-1819) in 1805 [9]. On the basis of this assumption, the most comprehensive study of Fungus haematodes was the one published in 1809 by James Wardrop (1782-1869), in which it is distinguished for the first time the ocular form of Fungus haematodes as a distinct pathological entity, even if a common name was used for this type of cancer found in different parts of the body [11].

In 1817 J. Beer indicated the whitish or yellowish reflection of the pupil in this disease introducing the term for this sign, 'amaurotic cat's eye', which was accepted as the main pathological sign of the disease until the mid 19<sup>th</sup> century, while the disease received also the name amaurosis after this sign [12].

But the progress of pathology during the 19<sup>th</sup> century allowed the microscopic examination of the these tumors and their histological description for the first time. Virchow in 1864 pointed for the first time that these tumors derived from giant cells of neuroglia, therefore he proposed the term glioma of retina for this disease, while after the studies of Simon Flexner (1863-1946) in 1891 and Hugo Wintersteiner (1865-1918) in 1897 it was believed that the disease was a form of neuroepithelioma due to the appearance of the special rosettes bearing their names. But in 1926 there was a consensus that this type of tumor derived from retinoblasts, so finally it was given the term retinoblastoma [13].



**Figure 1.** A sketch representation of a real case of retinoblastoma in early 19<sup>th</sup> century by Travers B. "A Synopsis of the Diseases of the Eye and their Treatment. Longman, Hurst, Rees, Orme & Brown, 1824".

## Discussion

From the first official description of retinoblastoma back in 1597 this type of ocular cancer was identified as soft cancer in order to be distinguished from scirrhous (carcinoma) cancer. This distinction was highlighted in Antonio Scarpa's (1752-1832) work *Trattato delle principali malattie degli occhi* (Study of the principal diseases of the eye) which is considered a very important study not only for ocular cancer but for ocular diseases in general, because this study acts as a bridge that connects the knowledge of the past regarding ophthalmology to the modern scientific approach to the diseases of the eye which began during the 19<sup>th</sup> century. In this study Scarpa made three major observations regarding retinoblastoma. Apart from the basic distinction between ocular carcinoma and Fungus haematodes (retinoblastoma), this physician pointed that Fungus haematodes

affected the inner anatomical structures of the eye in children under 12 years more often than adults, this type of cancer could be or not a variation of ocular carcinoma and excision of eyeball to treat Fungus haematodes was considered pointless and could provoke a faster death of the patient. In his remarks, although with many incorrect conclusions, is made clear the difficulties faced by the physicians at his time to understand and treat the disease [14].

However, almost half a century later the picture is very different. The progress in understanding the disease thanks to the development of pathology is obvious in the work of Karl Stellwag von Carion (1823-1904) *Treatise on the diseases of the eye: including the anatomy of the organ*, which is the fourth edition of the English translation of his original work *Lehrbuch der praktischen Augenheilkunde* (A treatise of practical ophthalmology). Now the scientific observations for the disease are very different.

Following Virchow, Karl Stellwag von Carion accepted and that this type of disease is originated from neuroglia using the term glioma. In microscopic analysis he indicated that this tumor was composed of small round cells with large round nuclei which were quite close to the cell wall. Inside the cytoplasm he distinguished fibrosis and pointed the fatty degeneration observed at the extension of the tumor. He emphasized that this tumor could occur in every anatomical structure of the retina, while it could expand to the optic nerve or intraocularly. He noticed that in 1/5 of the patients who were children not older than 12 years, this cancer was observed in both eyes. Stellwag refused the idea that a fungus was the cause for this cancer, as it was believed until the early 20<sup>th</sup> century, while he pointed also that cachexia and ocular injuries had no relation to this tumor [15,16].

Virchow's ideas on the pathological picture of the disease was also followed by Hermann Jacob Knapp (1832-1911) in his work entitled *Die intraocularen Geschwülste* (intraocular tumor) which was the fundamental study for intraocular tumors during the last quarter of 19<sup>th</sup> century. Knapp suspected for the first time a congenital origin of this malignancy. He stressed the spread of the disease to the other eye through the optic chiasm and he recognized enucleation as the only effective treatment, while he stressed that the physician should be very careful in order to detect early the expansion of the disease to the other eye, because early enucleation of both eyes could save patient's life [17].

At the end of the 19<sup>th</sup> century Photinos Panas (1832-1903) in his study *Traité des maladies des yeux* (Treatise on ocular diseases) which included the

distillate of experience in ophthalmology, he accepted also Virchow's ideas for the pathology of the disease and after making an extensive review of the bibliography of his time he admitted that the disease is of unknown cause, but would suggest that probably a malignant transformation should have been made during fetal life, since it affects young children. He also suspected a hereditary predisposition based on incidents in relatives of patients who had experienced various forms of cancer [18].

After the invention of ophthalmoscope by Hermann von Helmholtz (1821-1894) [19] in 1851 and its introduction in clinical practice, all the above mentioned physicians and the others during the second half of the 19<sup>th</sup> century considered ophthalmoscopy necessary for the diagnosis of retinoblastoma in order to be observed not only the whitish or yellowish reflection of the tumor in retina but also neovascularization and possibly coat detachment points.

However, differential diagnosis presented several difficulties, as during ophthalmoscopy this picture could be simple retinal detachment, choroid leukosarcoma, tuberculosis of the choroid, chronic inflammation, acute vitritis, cysticercus vitreous, congenital anomaly, circular retinitis and detachment with edematous retinal degeneration of rod and cone [20].

## Conclusion

From 1597 when was recorded the first official case of retinoblastoma described as Fungus haematodes until 1926 when the scientific community accepted the term retinoblastoma for this disease after detecting the origins of the tumor, great efforts were made by the physicians during this time period to understand and describe the disease. Many difficulties were faced by the physicians in studying this malignancy, but their great difficulty and concern was to save the life of the patients as this was a fatal disease. Enucleation was the only treatment although recurrence was not excluded, until 1903 when Henry Louis Hilgartner (1868-1937) an ophthalmologist from Austin, Texas, applied for the first time X-rays against retinoblastoma in order to save the eyes of a young girl, 3.5-year-old with bilateral retinoblastoma [21]. This was the starting point for the introduction of radiotherapy against retinoblastoma which now has the form of conformal proton beam radiation therapy.

## Conflict of interests

The authors declare no conflict of interests.

## References

1. Dunphy EB. The story of retinoblastoma. *Trans Am Acad Ophthalmol Otolaryngol* 1964;68:249-64.
2. Karamperopoulos D, Kouzis A. Cancer in ancient Greek Physicians. Athens: Stamoulis; 2004 (in Greek).
3. Virchow RLC. *Die Cellularpathologie in ihrer Begründung auf physiologische und pathologische Gewebelehre*. Berlin: Verlag von August Hirschwald; 1858.
4. Virchow RLC. *Die krankhaften Geschwülste: dreissig Vorlesungen, gehalten während des Wintersemesters 1862-1863 an der Universität zu Berlin*. Berlin: Verlag von August Hirschwald; 1863.
5. Künzl E, Zimmermann S. Die Antiken der Sammlung Meyer-Steineg in Jena II. Instrumente verschiedener Fundorte, Kästchen, Statuetten und Votive. *Jahrbuch des Römisch-Germanischen Zentralmuseums Mainz* 1994;41:179-198.
6. Grmek M, Gourevitch D. *Les maladies dans l'art antique*. Paris; Fayard; 1998.
7. Van Straten FT. Gifts for the gods In: Versnel HS (Ed): *Faith, Hope and Worship: aspects of religious mentality in the ancient world*. Leiden: Brill; 1981, 65-151.
8. Laios K, Karamanou M, Tsoucalas G, Sgantzos M, Androutsos G. Ophthalmic malignancies in antiquity as depicted in two terracotta figurines, *JBUON* 2015;20:650-2.
9. Kivelä T. 200 years of success initiated by James Wardrop's 1809 monograph on retinoblastoma. *Acta Ophthalmol* 2009;87:810-2.
10. Hayes R. The case of a diseased eye communicated to Mr. William Hunter by Mr. Hayes, Surgeon. *Medical Observations and Inquiries*. By a society of physicans in London. London: William Johnston; 1767.
11. Wardrop J. Observations on fungus hæmatodes or soft cancer, in several of the most important organs of the human body: containing also a comparative view of the structure of fungus hæmatodes and cancer. With cases and dissections. Edinburgh: Printed by G. Ramsay and Co., for A. Constable and Co.; 1809.
12. Beer J. *Lehre von den Augenkrankheiten: als Leitfaden zu seinen öffentlichen Vorlesungen entworfen*. Wien: Camesina; 1817.
13. Albert DM. Historic review of retinoblastoma. *Ophthalmology* 1987;94:654-62.
14. Scarpa A. *Trattato delle principali malattie degli occhi*. I-II. Pavia: nella stamperia di Pietro Bizzoni; 1816.
15. Stellwag K. von Carion. *Lehrbuch der praktischen Augenheilkunde*. Wien: Wilhelm Braumüller; 1870.
16. Stellwag K. von Carion. *Treatise on the diseases of the eye: including the anatomy of the organ*. (Trans. Hackley CE, Roosa DBStJ, Countway AF). New York: William Wood & Co.; 1873.
17. Knapp H. *Die intraocularen Geschwülste*. Nach eigenen klinischen Beobachtungen und anatomischen Untersuchungen. Karlsruhe, Müller, 1868.
18. Panas Ph. *Traité des maladies des yeux*. Vol. I-II. Paris: G. Masson; 1894.
19. Wood CA. Hermann von Helmholtz: the inventor of the ophthalmoscope. *J Am Med Assoc* 1902;38:552-7.
20. Da Gama P. *Untersuchungen über intraoculare Tumoren*. Netzhautgliome. Wiesbaden: Bergmann; 1886.
21. Hilgartner HL. Report of case of double glioma treated with x-ray. *Tex Med J* 1903;18:322-3.