

## HISTORY OF ONCOLOGY

---

# The distinguished Greek born, French ophthalmologist Photinos Panas (1832-1903) and his views on ocular cancer

Konstantinos Laios<sup>1</sup>, Marianna Karamanou<sup>1</sup>, Efstathia Lagiou<sup>2</sup>, Konstantinos Ioannidis<sup>3</sup>, Despoina Pavlopoulou<sup>3</sup>, Vicky Konofaou<sup>4</sup>, George Androutsos<sup>5</sup>

<sup>1</sup>History of Medicine, Medical School, University of Crete, Crete, Greece; <sup>2</sup>Medical School, University of Patras, Patras, Greece; <sup>3</sup>Private physician, Athens, Greece; <sup>4</sup>Neurosurgical Department, Children's Hospital of Athens "P. & A. Kyriakou", Athens, Greece; <sup>5</sup>Biomedical Research Foundation, Academy of Athens, Athens, Greece

### Summary

Photinos Panas (1832-1903) was one of the world's most important ophthalmologists in the second half of the 19<sup>th</sup> century. In his leading work entitled, *Traité des maladies des yeux* (Treatise of ophthalmic diseases), he made an in depth analysis of the various types of ocular cancer. His ideas on the subject were important for their tutorial char-

acter, their connection to the clinical work and very helpful for the everyday clinical practice of physicians of that time.

**Key words:** history of oncology, ocular cancer, Photinos Panas, retinoblastoma, sarcoma

### Introduction

At the beginning of 19<sup>th</sup> century, ophthalmology was part of general medicine and it was not considered a medical priority. General surgeons operated cataracts and treated ocular problems. The eminent German ophthalmologist and medical historian Julius Hirschberg (1843-1925) argues that ophthalmology became a distinct medical specialty thanks to two important political-social events: the French Revolution of 1789 and the Napoleonic wars from 1803 to 1815, mainly the Egyptian campaign. War emerged the


need for care and intervention in ocular trauma while the endemic trachoma in Egypt, known also as Egyptian ophthalmia, became the most common cause of blindness along with smallpox in Western Europe. Ophthalmology advanced rapidly and by the 1830s new hospitals were build and new surgical techniques were developed [1]. In Paris, Photinos Panas (1832-1903) excelled in ophthalmology and ocular cancer establishing the ophthalmology clinic at Hôtel-Dieu hospital.

## Panas' life and work

Photinos Panas was born in the island of Cephalonia on January 30, 1830 [2]. In 1855 he enrolled in the Medical School of Paris and graduated in 1860. During the first year of his medical studies and despite his bad financial situation affecting his living condition, he received the gold medal of the Faculty of Medicine and soon afterwards he became assistant and prosector in anatomy, providing also some classes in medical students [3]. His thesis entitled: «Sur l'anatomie des fosses nasales et des voies lacrimales» (On the anatomy of nasal cavities and lacrimal passages) was presented in 1860 [4]. Three years later, he naturalized French citizen and he was appointed assistant professor of Surgery presenting his aggregation thesis on vicious cicatrization and the means of preventing («Des cicatrices vicieuses et des moyens d'y remédier») [2,4].

Panas presented a various work in general surgery: he was the first to perform successfully ovariectomy in Parisian hospitals; he operated fractures of the radius, strangulated hernia and amputation of the breast with good results [3]. From 1859 to 1863 he gave courses of surgical anatomy, physiology of the nervous system and the organs of sense, of external pathology and even of syphilography at Saint Antoine hospital [2,3]. From 1869 to 1878, he started to deliver clinical lessons of ophthalmology initially at Saint Louis and later at Lariboisière hospital, while in the period 1872-1878 he provided complimentary courses in ophthalmology at the Faculty of Medicine [3]. In 1879, the first chair of ophthalmology was created in the Medical School of Paris and Panas was called to it, becoming thus the first professor of ophthalmology till his retirement in 1901 [2].

Panas was considered one of the most important ophthalmologists in the second half of the 19<sup>th</sup> century and his work gained international recognition (Figure 1). He left numerous works on surgery, anatomy, orthopedics and physiology but mostly on ophthalmology such as on strabismus (1873), on keratitis (1876), on affections of the lacrimal apparatus (1877), on retinitis (1878), on the inflammatory diseases of the deep membranes of the eye (1878), and his masterpiece, a complete treatise on the diseases of the eye (1894) [5]. He introduced an operation for blepharoptosis and a technique for the management of entropion in trichiasis [2]. Member of the Academy of Medicine, honorary member of the Surgical Society and of the Royal Academy of Belgium, knight of the Legion of Honor and founder with his colleagues Edmund Landolt (1846-1926) and Antonin Poncet



**Figure 1.** Professor Photinos Panas painted by Federico de Madrazo (1815-1894).

(1849-1913) of the Archives of Ophthalmology (Archives d'Ophtalmologie), Panas contributed to the development of ophthalmology as a distinct medical specialty [2,5]. Furthermore, he never forgot his fatherland, Greece and when the Greco-Turkish war of 1897 was declared he sent an ambulance corps to Athens [3].

Panas died on the 6<sup>th</sup> of January 1903 at his home at Roissy [2]. He was survived by his wife of Greek-Chian origin, Maria Balli, daughter of the wealthy family of Xenophon and Calliope Balli, based in London [6].

## Panas' contribution in ocular cancer

Photinos Panas, published at the end of the 19<sup>th</sup> century, his most mature work on ocular diseases entitled: "Traité des maladies des yeux" (Treatise on ophthalmic diseases) [7], which concentrates all the knowledge of his time about eye malignancies along with his personal observations (Figure 2). In this manuscript, Panas made an in depth analysis of ocular cancer. Concerning the malignant tumors of the conjunctiva, he used examples of past incidents, described in medical literature and highlighted the appearance of epithelial tumors and sarcomas [7].

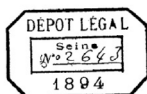
TRAITÉ  
DES  
MALADIES DES YEUX



PAR

PH. PANAS

Professeur de clinique ophthalmologique à la Faculté de médecine  
Chirurgien de l'Hôtel-Dieu, Membre de l'Académie de médecine  
Membre honoraire et ancien président de la Société de chirurgie



TOME PREMIER

Avec 158 figures et 7 planches coloriées

PARIS

G. MASSON, ÉDITEUR

LIBRAIRE DE L'ACADÉMIE DE MÉDECINE DE PARIS  
120, BOULEVARD SAINT-GERMAIN, 120

1894

Source gallica.bnf.fr / Bibliothèque nationale de France

**Figure 2.** Frontispiece of Pana's treatise on ophthalmic diseases.

In cases of malignant tumors of the iris, he indicated that iris' sarcomas are extremely rare and in most cases they represent extensions of tumors from the radial body or from the anterior part of the choroid [8]. He focused on sarcomas that are an extension of those initially appearing in the choroid and emphasized that these tumors are more common in women and in the elderly, while concerning their pathology he mentioned that they are similar to those in choroids where fetal cells (mesenchymal) round or spindle are observed. He distinguished melanomas and leukomas based on the presence or absence of hyperchromatic-pigment nuclei in the cells [7]. Furthermore, he pointed out that for establishing a correct diagnosis, in cases of sarcomas, it was primordial to distinguish if the tumor was of primary origin or an extension from the choroid or radial body. He mentioned that the physician should realize that ophthalmoscopy is not an absolute method of diagnosis [7], as in several cases it is impossible to examine the part immediately behind the iris, and he suggested that the portion of the iris near the

sclera should be examined to determine if there is a color change or a tumor appearance. Increased intraocular pressure, cataract formation, and retinal edema are signs that indicate the expansion of the tumor inside the eye [9]. The recommended treatment for sarcomas was the iridectomy [10], but in cases that it was a suspicion of a choroid tumor, the only approach was the extraction of the ophthalmic bulb [7].

Concerning choroidal neoplasms, Panas analyzed extensively choroidal sarcoma sustaining, based on the observations of other researchers, that it was the most common malignant neoplasm of the eye. He acknowledged that it was appearing more often in middle and older age and he considered questionable the injury as the cause, pointing out that chronic inflammation, which was appearing, was not a provoking factor but the result. He considered primary the choroidal sarcoma, while in cases of metastases from the breast, stomach or other organs, the presence of epithelial cells in histology could confirm the diagnosis. He pointed out that it must be some predisposition for the disease, which he couldn't determine. The form of this cancer was lobular in most cases, while the diffuse type was rare. The cells were circular or spindle-like while the appearance or no of hyperchromatin pigmentation could lead to the identification of melanoma or leukoma [11]. Panas mentioned also the four stages in the development of this tumor. In the first stage, the patient complains about the presence of a shadow when observing the objects, and loss of vision occurs when the tumor is expanded to the posterior chamber. Rarely, the patient could complain about illuminations and headache or migraine. In the second stage, the eye becomes red and intense pain occurs. In the third stage, deepening of the sclera occur which penetrates the conjunctiva and infiltrates into the orbit and the eyelids. The fourth stage is the stage of metastases. For the diagnosis of choroidal neoplasms, he recommended the ophthalmoscopy. The only point where difficulty in diagnosing was observed was when the tumor was small and there was only detachment of the retina. In that case, he was suggesting control of the intraocular pressure. Therapeutically, he was proposing the extraction of the ophthalmic bulb. The approach of Panas in the diagnosis of malignancies is superior and beyond the simple observation and consideration of exophthalmus as a common feature of the malignancy of the eye in early and mid-19<sup>th</sup> century [7].

As for retinal glioma (retinoblastoma), Panas made an extensive review of the literature, especially from the early 19<sup>th</sup> century until his time, but

what impresses us is that he didn't refer to the name of the tumor as "fungus haematodes" [7,12], probably because he wanted to remain faithful to the strict scientific facts about the disease. He accepted Virchow's views on the origin of the tumor from the neuroglia [13] and he discussed the possibility of spreading through the optical chiasm and the brain, underlining the unfavorable prognosis of the disease. He admitted that the disease is of unknown etiology, but he indicated that malignant transformation should have an embryonic origin because it was affecting young patients. Moreover, Panas spoke about the hereditary predisposition based on observations and cases that occurred in the family or relatives of the patients [7].

Regarding the malignant tumors of the optic nerve, he classified endothelioma, psamoma and sarcoma, as well as the mixed types. He didn't emphasize the histological but the clinical characteristics of these malignancies discussing about the disturbances and the loss of vision, the headaches and the eyeball deflection [7].

Concerning the cancer of the orbit Panas referred to the sarcoma. He mentioned the diverse origins of cancer cells in this case, highlighting the origin of adipose, bone and nervous tissue as well. He recognized two basic types of cells, the rounds cells occurring mainly in childhood and the spindle cells that occur in patients over 40 years of age. He made also a distinction in leukosarcomas and melanosarcomas based on the presence or absence of pigmentation in the cells, as well as the appearance of fibrosarcoma based on the presence of fibrous tissue [7].

Discussing about cylindroma, he mentioned that it was distinguished from sarcoma, but its cells had cellular structure. He referred to the origin of orbit cancer from adipose tissue or ocular muscles. He reported the pressure observed during tumor growth, while vision problems did not appear at the initial stage. He added the epithelial type as a carcinoma originated from the eyelids or the conjunctiva or the lacrimal gland. Regarding the prognosis he stated that it was bad, especially with intracranial tumor expansion and he accepted that surgical treatment was necessary [7].

## Conclusion

Evaluating the work of Photinos Panas, we could say that it has a significant importance since it reviews the ocular malignancies at the end of the 19<sup>th</sup> century in an evidence-based way [14]. Although in his study he mentioned the basic elements of the pathogenesis of malignant tumors of the eye, he focused also on the clinical area, in order to help the physician in making a proper diagnosis of tumors. This is why there are many details on medical semiology and differential diagnosis in his book. What appears for the first time in a book of ophthalmology, is his persistence to provide an early diagnosis of ophthalmic cancer, which can be, according to Panas, life-saving for the patient. In addition, his book had a teaching character, focusing on the essential elements of everyday clinical practice, creating a skeleton of basic knowledge that helped and trained a whole generation of physicians.

## References

- Hirschberg J. Handbuch der Gesamten Augenheilkunde. Geschichte der Augenheilkunde IX & X: Die Reform der Augenheilkunde. Berlin, Springer, 1918.
- Lapersonne F de. Le professeur Panas. Paris: Steinheil, 1903.
- Anonymous. Photinos Panas, Obituary. *Am J Ophtalmol* 1903;20: 62-4.
- Photinos P. Titres et travaux scientifiques, Novembre 1868. Paris, Martinet, 1868.
- Pecker A. La médecine à Paris du XIIIe au XXe siècle. Paris, Hervas, 1984, p 445.
- Anonymous. Wills and Bequests. *The Illustrated London News*, 1877;3:263.
- Panas P. *Traité des maladies des yeux*. Vol. I-II. Paris, Masson, 1894.
- Hirschberg J. *Die Augenheilkunde in der Neuzeit*. Leipzig, Engelmann, 1911.
- Knapp H. *Die intraocularen Geschwülste*. Nach eigenen klinischen Beobachtungen und anatomischen Untersuchungen. Carlsruhe, Müller, 1868.
- Wood CA. *A system of ophthalmic operations*. Vol. I-II. Chicago, IL, Cleveland Press, 1911.
- Panas P, Rémy DA. *Anatomie pathologie de l'œil*. Paris, Adrien Delahaye, 1879.
- Wardrop J. *Observations on fungus hæmatodes or soft cancer, in several of the most important organs of the human body: containing also a comparative view of the structure of fungus hæmatodes and cancer. With cases and dissections*. Edinburgh, Ramsay-Constable, 1809.
- Virchow RLC. *Die krankhaften Geschwülste: dreissig Vorlesungen, gehalten während des Wintersemesters 1862-1863 an der Universität zu Berlin*. Berlin, Verlag von August Hirschwald, 1863.
- Arrington GE, Mart-Ibanez F. *A History of Ophthalmology*. MD Publications, New York, 1959.