

ORIGINAL ARTICLE

Correlation of COX-2 and MMP-13 expressions with gastric cancer and their effects on prognosis

Jianli Ren^{1*}, Jian Liu^{2*}, Xin Sui¹

¹Department of Gastroenterology and ²Department of Radiology, Dezhou People's Hospital, Dezhou, China

*These authors contributed equally to this work.

Summary

Purpose: To study the expressions of cyclooxygenase-2 (COX-2) and matrix metalloproteinase-13 (MMP-13) genes in gastric cancer, and to investigate the correlation between them and gastric cancer and their effects on prognosis.

Methods: 80 cases of tumor tissues and 40 cases of normal tumor-adjacent tissues were collected from patients with gastric cancer admitted to the Surgical Department of our hospital. The mRNA expression levels of COX-2 and MMP-13 in tumor tissues and normal tumor-adjacent tissues were detected via real-time fluorescence reverse transcription polymerase chain reaction (RT-PCR). The expressions of COX-2 and MMP-13 in gastric cancer tissues and normal tumor-adjacent tissues were detected via immunohistochemical method. The clinical data of patients were recorded and the correlation between the COX-2 and MMP-13 expressions and the pathological parameters and prognosis of patients with gastric cancer were analyzed.

Results: RT-PCR results showed that the mRNA expressions

of COX-2 and MMP-13 in gastric cancer tissues were significantly higher than those in normal tumor-adjacent tissues. Immunohistochemical results showed that the positive expression rates of COX-2 and MMP-13 in gastric cancer tissues were 76.25% (60/80) and 71.25% (57/80), respectively and the high expression was related to the invasion, metastasis and tumor stage. The 5-year overall survival of patients was 16.6% (13/80). Single-factor survival analysis showed that both COX-2 and MMP-13 were factors influencing the overall survival of patients with gastric cancer ($p < 0.01$).

Conclusion: The high expressions of COX-2 and MMP-13 are closely related to the pathological parameters of patients with gastric cancer, especially the invasion, metastasis and tumor stage. COX-2 and MMP-13 can be used as reference indexes to guide the treatment of gastric cancer and predict the disease prognosis.

Key words: gastric cancer, COX-2, MMP-13, prognosis

Introduction

At present, the mortality rate of gastric cancer is second only to that of lung cancer among malignant tumors, and its incidence rate also ranks fourth in the world [1,2]. The clinical treatment method of early gastric cancer is mainly surgery, but most patients are in advanced stage when diagnosed, so the main treatment option is chemotherapy-based comprehensive therapy. However, there is not a unified standard of chemotherapy regimens for gastric cancer, and the survival rate of patients

with advanced gastric cancer is not significantly improved by chemotherapy, not forgetting the adverse reactions of chemotherapy [3-5]. Gastric cancer does not have typical clinical features in the early stage, so it is often ignored. It has been reported that 50-60% of patients with gastric cancer in China are diagnosed in middle and advanced stages; the resection rate is only 40% in diagnosed patients, the recurrence and metastasis still occur easily after resection due to the high tumor ma-

Correspondence to: Dr. Xin Sui. Department of Gastroenterology, Dezhou People's Hospital, 1751 Xinhua Street, Dezhou 253014, Shandong, China.

Tel: +86 534 2637114, Fax: +86 534 2637115, E-mail: dezhscq009@163.com

Received: 07/10/2017; Accepted: 08/11/2017

lignant behavior and the prognosis is poorer with only 20-30% of the patients surviving for 5 years after surgery. Therefore, the outcomes of surgical treatment alone are unsatisfactory for those patients, especially the ones accompanied with local spread or metastasis in other tissues/organs [6]. The clinical treatment of gastric cancer now has been transformed from simple surgery into surgery combined with radiotherapy and chemotherapy, as well as targeted therapy such as herceptin and other drugs, a hotspot in recent years [7].

The existing clinical treatment options are accompanied with serious adverse reactions, leading to reduced quality of life. COX-2 is known as the inducible enzyme, which exists in the brain tissues and some kidney tissues, but not expressed in most other tissues. However, the expression of COX-2 will be increased and will promote the development and progression of tumors under the stimulation of interleukin, various cytokines, tumor inducers and oncogenes [8]. MMP-13 is a glycoprotein with the molecular weight of 60KD, which was originally found in human breast cancer and cloned. As a kind of proteolytic enzyme, it can hydrolyze a wide range of substrates, almost involving all of the proteins in the extracellular matrix. When the MMP-13 expression is increased under a pathological state, it will participate in the growth, invasion and metastasis of tumor cells [9,10].

In order to study the correlation between COX-2 and MMP-13 and gastric cancer and their effects on prognosis, the mRNA and protein expression levels of COX-2 and MMP-13 in gastric cancer and normal tumor-adjacent tissues were detected via RT-PCR and immunohistochemistry, respectively, and the correlation between the COX-2 and MMP-13 expressions and the pathological parameters and prognosis of gastric cancer were analyzed.

Methods

Patients

A total of 80 patients with gastric cancer admitted to the Surgical Department of our hospital from January 2010 to December 2012 were enrolled. All patients

were clinically and pathologically diagnosed with gastric cancer, and were treated for the first time. There were 42 males and 38 females aged 28-75 years (median 46). The collection of all samples in the experiment was approved by the Clinical Ethics Committee of the hospital, and all patients or their family members signed informed consent.

Materials

RNA extraction kit, reverse transcription kit and RT-PCR Kit were purchased from Invitrogen (Carlsbad, CA, USA); primer synthesis (TaKaRa, Dalian, China); COX-2 and MMP-13 primary antibodies and HRP-labeled secondary antibody were purchased from Proteintech (Wuhan, China); immunohistochemical staining kit SP-9001 was purchased from Beijing Zhongshan Goldenbridge Biotechnology Co., Ltd. (Beijing, China).

Detection of mRNA expressions of COX-2 and MMP-13 in samples via RT-PCR

About 50mg of tumor tissue samples and 50mg normal tumor-adjacent tissue samples were taken from patients and placed in the Eppendorf tube. Total RNA in tissues was extracted according to the instructions of RNA extraction kit. The ultraviolet-visible spectrophotometer (HITACHI, Tokyo, Japan) was used to detect the concentration and purity of total RNA (qualified if the ratio of A260/A280 absorbance value was 1.8-2.0). Following this, cDNA was obtained via reverse transcription according to the instructions of reverse transcription kit. With cDNA as the template, mRNA expressions of COX-2 and MMP-13 were detected according to the instructions of real-time fluorescent quantitative PCR kit, and glyceraldehyde-phosphate dehydrogenase (GADPH) was used as the internal control. The primer sequences of COX-2, MMP-13 and GADPH are shown in Table 1. Reaction conditions were as follows: 95°C for 10 min, 95°C for 30s, 57°C for 30s, 72°C for 30s, a total of 40 cycles of amplification; 72°C for 5min. The relative expression quantity was calculated using the $2^{-\Delta Ct}$ method: ΔCt (target gene) = Ct (target gene) - Ct (control gene).

Detection of protein expressions of COX-2 and MMP-13 in pathological tissues via immunohistochemistry

This detection was performed according to the instructions of immunohistochemical staining kit SP-9001, and the operating steps were as follows: The paraffin-embedded sections were dewaxed and the endog-

Table 1. RT-PCR primer sequences

Gene	Primer name	Primer sequence
COX-2	Forward primer	5'-TCGCTGTGCCTGATGATTG-3'
	Reverse primer	5'-TCGCTTATGATCTGTCTTG-3'
MMP-13	Forward primer	5'-TGACTATGCGTGGCTGGAA-3'
	Reverse primer	5'-AAGCTGAAATCTTGCCCTTGG-3'
GAPDH	Forward primer	5'-ATGGCACCCTCAAGGCTGAG-3'
	Reverse primer	5'-GCAGTGATGGCATGGACTGT-3'

enous peroxidase was blocked using 3% H₂O₂. Antigen retrieval was achieved by using citric acid buffer and sealed using 10% goat serum. Primary antibodies (diluted at 1:100) were added to incubate at 4°C overnight. After proteins were washed with phosphate-buffered saline (PBS), the biotin-labeled secondary antibodies were added to incubate with proteins for 15min. Then, the proteins were washed with PBS, followed by color development via diaminobenzidine (DAB), restaining via hematoxylin and photographed under microscope (TE2000-U, Nikon, Japan).

The representative regions were selected and the results of immunohistochemical staining were evaluated according to the following methods: The expression intensity was classified and graded according to the staining intensity and the percentage of positive cells. The staining intensity was defined as 0 (no staining), 1 (faint yellow), 2 (brown yellow) and 3 points (dark brown), and the number of positive cells in high-power field (400×) was defined as 0 (<5%), 1 (5-25%), 2 (26-50%) and 3 points (>50%). Both points were added. Scoring >3 points: positive expression, ≤2 points: negative expression; the final scores were recorded and analyzed.

Correlation between the expressions of COX-2 and MMP-13 in gastric cancer tissues and the pathological parameters and prognosis

According to the expression levels of COX-2 and MMP-13 in gastric cancer tissues, 80 patients with gastric cancer were divided into the COX-2 positive expression group, COX-2 negative expression group, MMP-13 positive expression group and MMP-13 negative expression group. There were no statistically significant differences in the age, gender and patient's condition

between the two groups ($p>0.05$). The correlation between COX-2 and MMP-13 and pathological parameters of patients was analyzed in relation to the clinical data. All the 80 patients were followed up for 5 years after surgery and the follow-up rate was 100%. The survival time was recorded from the first day after surgery until the death date of patients or the deadline of follow-up.

Statistics

Statistical analyses were performed on a monthly basis.

SPSS 17.0 software (International Business Machines Corporation, New York, USA) was used for data processing and analyses. Quantitative data were presented as mean ± standard deviation, and Student's t-test was used for intergroup comparison. Chi square test was used for the intergroup comparison of numerical data. Kaplan-Meier method was used for single-factor survival analysis and log-rank test was used to test the differences of survival. A p value ≤0.05 suggested that the difference was statistically significant.

Results

Detection of mRNA expressions of COX-2 and MMP-13 in tissue samples via RT-PCR

RT-PCR results showed that the mRNA expression levels of COX-2 and MMP-13 in gastric cancer tissues were significantly increased compared with those in normal tumor-adjacent tissues, and the differences were statistically significant (Figure 1; $p<0.01$).

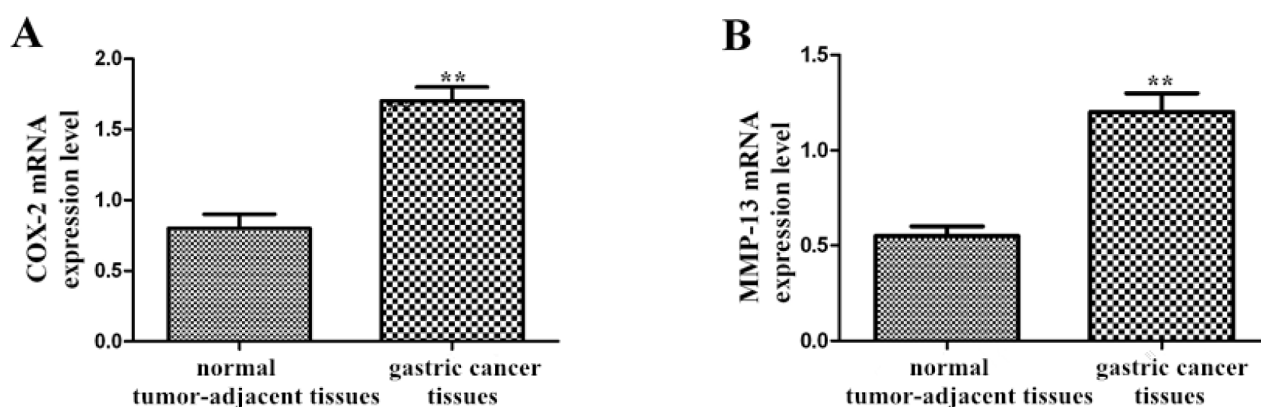


Figure 1. Detection of mRNA expressions of COX-2 and MMP-13 in tissue samples via RT-PCR. **A:** The mRNA expression of COX-2 in tissue samples; **B:** The mRNA expression of MMP-13 in tissue samples. The mRNA expression levels of COX-2 and MMP-13 in gastric cancer tissues were significantly increased compared with those in normal tumor-adjacent tissues (** $p<0.01$).

Table 2. Protein expressions of COX-2 and MMP-13 in normal tumor-adjacent tissues and gastric cancer tissues

Group	Cases	COX-2			MMP-13		
		Positive	Positive rate, %	p value	Positive	Positive rate, %	p value
Gastric cancer tissues	80	61	76.25	<0.01	57	71.25	<0.01
Normal tumor-adjacent tissues	40	7	17.50		9	22.50	

Detection of protein expressions of COX-2 and MMP-13 in pathological tissues via immunohistochemistry

Immunohistochemical results showed that the positive immunohistochemical staining of COX-2 and MMP-13 showed brown yellow. COX-2 proteins were mainly located in the cytoplasm and nuclear membrane, while MMP-13 proteins were located in the cytoplasm (Figure 2).

The staining scores were recorded. The positive expression rates of COX-2 in gastric cancer tissues and normal tumor-adjacent tissues were 76.25% (60/80) and 17.5% (7/40), respectively, and the difference was statistically significant ($p < 0.01$); the positive expression rates of MMP-13 in gastric cancer tissues and normal tumor-adjacent tissues were 71.25% (57/80) and 22.5% (9/40), respectively, and the difference was statistically significant ($p < 0.01$, Table 2).

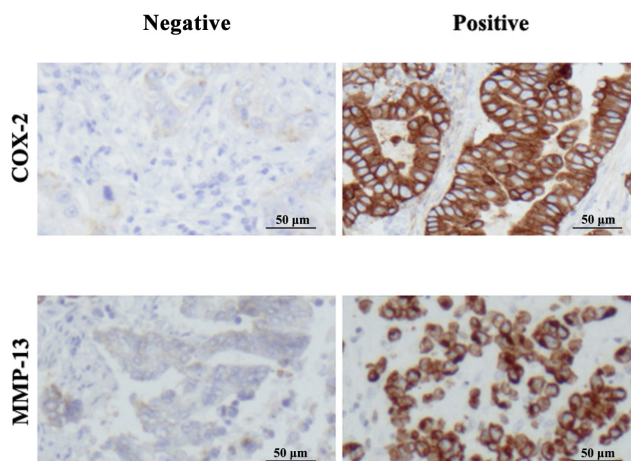


Figure 2. Detection of protein expressions of COX-2 and MMP-13 in pathological tissues via immunohistochemistry (400×). The positive expression rates of COX-2 and MMP-13 in gastric cancer tissues was higher compared with normal tumor-adjacent tissues ($p < 0.05$).

Table 3. Relationship between abnormal expressions of COX-2 and MMP-13 and pathological parameters of gastric cancer

Clinical data	Cases	COX-2			MMP-13		
		Positive	Positive rate, %	<i>p</i> value	Positive	Positive rate, %	<i>p</i> value
Gender				>0.05			>0.05
Male	43	33	76.74		32	74.42	
Female	37	28	75.68		25	67.57	
Age, years				>0.05			>0.05
≥50	48	35	72.92		34	70.83	
<50	32	26	81.25		21	65.63	
Tumor size, cm				>0.05			>0.05
≥5	46	33	71.74		31	67.39	
<5	34	28	82.35		26	76.47	
Invasion and metastasis				<0.01			<0.01
Yes	49	43	87.76		42	85.71	
No	31	19	61.29		15	48.39	
Tumor staging				<0.01			<0.01
I-II	29	17	58.62		14	48.28	
III-IV	51	44	86.27		43	84.31	

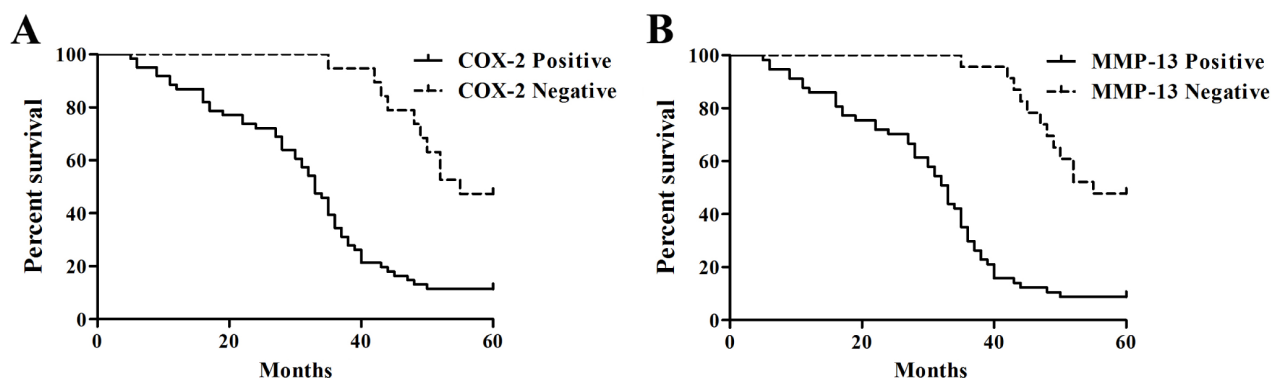


Figure 3. COX-2 and MMP-13 expressions and Kaplan-Meier survival curve of patients with gastric cancer. **A:** Kaplan-Meier survival curves of gastric cancer patients with positive and negative expressions of COX-2 ($p < 0.01$). **B:** Kaplan-Meier survival curves of gastric cancer patients with positive and negative expressions of MMP-13 ($p < 0.01$).

Table 4. Single-factor analysis of the relationship between COX-2 and MMP-13 expressions and overall survival of patients with gastric cancer

Group	Cases	Number of 5-year survivors	5-year survival rate, %	Wald (Log-rank)	p value
COX-2				18.91	<0.01
Positive	61	7	11.48		
Negative	19	9	47.37		
MMP-13				27.54	<0.01
Positive	57	5	8.77		
Negative	23	11	47.83		

Correlation between pathological indexes of gastric cancer and COX-2 and MMP-13 expressions

The results of correlation between patient pathological parameters with gastric cancer and COX-2 and MMP-13 expressions are shown in Table 3. Chi-square test showed that the positive expressions of COX-2 and MMP-13 were related to tumor metastasis and tumor staging ($p < 0.01$), but not related to tumor size, gender and age ($p > 0.05$).

Single-factor analysis of the survival situation and prognosis of patients

A total of 80 patients with gastric cancer were followed up; the number of 5-year survivors was 16 and the number of deaths 64 (Table 4). Kaplan-Meier survival curves of 80 gastric cancer patients with different expressions of COX-2 and MMP-13 are shown in Figure 3A and 3B, and the results showed that gastric cancer patients with negative expressions of COX-2 and MMP-13 had a relatively better survival prognosis. Differences in the overall survival were compared via log-rank test (Figure 3) and the results of single-factor survival analysis showed that the effects of COX-2 and MMP-13 on overall survival rate of patients with gastric cancer were statistically significant ($p < 0.01$).

Discussion

The incidence rate of gastric cancer ranks fifth among the malignant tumors around the world while it ranks second in China [11]. Although the treatment options of gastric cancer have been greatly improved, the 5-year survival rate in progressive state is still only 16.6% [12]. Therefore, it is of utmost importance to carry out research on the pathogenesis and progression of gastric cancer.

Arachidonic acid can produce prostaglandins (PG) under the catalysis of COX, limiting the speed of PG synthesis [13]. In the present study, COX was divided into COX-1, COX-2 and COX-3, among

which the expression level of COX-2 was an important index affecting the pathological factors and prognosis of cancer patients [14,15]. Studies have shown that PG products in mice can accelerate the cell proliferation and DNA synthesis. When the tumor cells are stimulated in this environment, their growth will be unrestricted, thus accelerating the deterioration of tumors [16]. Medhurst et al. [17] studied the bone cancer pain of rats and the results showed that the expression quantity of COX-2 was significantly associated with tumor cell proliferation and disease deterioration.

MMPs are proteolytic enzymes and all extracellular matrix components can be degraded by them except polysaccharides. MMPs play an important role in the infiltration and invasion of tumor cells and metastasis to distant sites, which can break down the balance of extracellular matrix degradation and further make cancer cells break through the barriers of basement membrane and extracellular matrix [18]. At the same time MMPs can also induce tumors to form new vessels and reduce the adhesion of extracellular matrix to tumor cells, so as to facilitate the cancer cell metastasis. As one of the most important proteases in the human body, MMP-13 is a member of MMP family, which was first obtained in human breast cancer cells in 1994 [19]. At present, more reports have confirmed that the high expression of MMP-13 under pathological states has a significant correlation with tumor invasion and metastasis, which can be used as an important reference index of the pathological factors and prognosis of cancer patients [20]. There are many studies on the relationship between MMP-13 and colorectal cancer, esophageal cancer and lung cancer in China [21-23]. However, there are only few reports on the relationship between MMP-13 and the pathogenesis of gastric cancer.

In order to further investigate the COX-2 and MMP-13 expressions in tumor tissues of patients with gastric cancer and their effects on pathological parameters and disease prognosis, the mRNA

expressions of COX-2 and MMP-13 in tumor tissues of patients with gastric cancer were detected via RT-PCR. The results showed that the mRNA expressions of COX-2 and MMP-13 in gastric cancer tissues were significantly increased compared with those in normal tumor-adjacent tissues. The immunohistochemical results showed that the positive protein expression rates of COX-2 and MMP-13 in gastric cancer tissues were 76.25% (60/80) and 71.25% (57/80), respectively, which were significantly higher than those in normal tumor-adjacent tissues. Furthermore, combined with the analysis of patients' clinicopathological features, it was found that the COX-2 and MMP-13 expressions were related to metastasis and tumor stage, but unrelated to gender, age and tumor size. Similarly, Ristimäki et al. studied and showed that the increased COX-2 expression was significantly associated with the TNM stage, histological grade, invasion and metastasis of patients with breast cancer [24]. The report of Thomas et al. showed that the MMP-13 expression in non-small cell lung cancer tissues was significantly increased compared with that in normal lung tissues, and

the difference was statistically significant [25]. Johansson et al. showed that the high expression of MMP-13 was often accompanied by tumor invasion and metastasis, so MMP-13 can be used as a prognosticator of tumor metastasis [26].

In this study the effects of different expressions of COX-2 and MMP-13 on patient overall survival were studied using the single-factor Kaplan-Meier survival analysis, and the results showed that the positive expressions of COX-2 and MMP-13 had a significant impact on overall survival of gastric cancer patients, with statistically significant differences.

In conclusion, the positive expressions of COX-2 and MMP-13 are closely related to the occurrence and development of gastric cancer, especially to tumor metastasis and tumor stage. COX-2 and MMP-13 can be used as reference indexes to guide the treatment of gastric cancer and predict the disease prognosis.

Conflict of interests

The authors declare no conflict of interests.

References

1. Brenner H, Rothenbacher D, Arndt V. Epidemiology of stomach cancer. *Methods Mol Biol* 2009;472:467-77.
2. Jemal A, Siegel R, Ward E, Hao Y, Xu J, Thun MJ. Cancer statistics, 2009. *CA Cancer J Clin* 2009;59:225-49.
3. Ryu MH, Kang YK. ML17032 trial: capecitabine/cisplatin versus 5-fluorouracil/cisplatin as first-line therapy in advanced gastric cancer. *Expert Rev Anti-cancer Ther* 2009;9:1745-51.
4. De Vita F, Vecchione L, Galizia G et al. Perspectives in adjuvant therapy of gastric cancer. *Oncology* 2009;77 (Suppl 1):38-42.
5. Mlkvy P. Multimodal therapy of gastric cancer. *Dig Dis* 2010;28:615-8.
6. Mello BS, Lucena Ade F, Echer IC et al. Patients with gastric cancer submitted to gastrectomy: an integrative review. *Rev Gaucha Enferm* 2010;31:803-11.
7. Bang YJ, Van Cutsem E, Feyereislova A et al. Trastuzumab in combination with chemotherapy versus chemotherapy alone for treatment of HER2-positive advanced gastric or gastro-oesophageal junction cancer (ToGA): a phase 3, open-label, randomised controlled trial. *Lancet* 2010;376:687-97.
8. Tan KB, Putti TC. Cyclooxygenase-2 expression in nasopharyngeal carcinoma: immunohistochemical findings and potential implications. *J Clin Pathol* 2005;58:535-8.
9. Leeman MF, Curran S, Murray GI. The structure, regulation, and function of human matrix metalloproteinase-13. *Crit Rev Biochem Mol Biol* 2002;37:149-66.
10. Ala-aho R, Kahari VM. Related articles, Collagenases in cancer. *Biochimie* 2005;87:273-86.
11. Chen W, Zheng R, Baade PD. Cancer statistics in China, 2015. *CA Cancer J Clin* 2016;66:115-32.
12. Sakuishi K, Apetoh L, Sullivan JM et al. Targeting Tim 3 and PD 1 pathways to reverse T cell exhaustion and restore anti tumor immunity. *J Exp Med* 2010;207:2187-94.
13. Smith WL, Dewitt DL, Garavito RM. Cyclooxygenases: structural cellular and molecular biology. *Ann Rev Biochem* 2000;69:145-82.
14. Zhu L, Loo WT, Cheng CW, Chow LW. Possible predictive markers related to micro-metastasis in breast cancer patients. *Oncol Rep* 2006;15:1217-23.
15. Park K, Han S, Shin E, Kim HJ, Kim JY. Cox-2 expression on tissue microarray of breast cancer. *Eur J Surg Oncol* 2006;32:1093-6.
16. Kimmura M, Osumi S, Ogihara M. Stimulation of DNA synthesis and proliferation by prostaglandins in primary cultures of adult rat hepatocytes. *Eur Pharmacol* 2000;404:259-71.
17. Medhurst SJ, Walker K, Bowes M et al. A rat model of bone cancer pain. *Pain* 2002;96:129-40.
18. Kleiner DE, Stetler-Stevenson WG. Matrix Metallo-

- proteinases and Metastasis. *Cancer Chemother Pharmacol* 1999;43 (Suppl) :42-51.
19. Leeman MF, Curran S, Murray GI. The structure, regulation, and function of human matrix metalloproteinase-13. *Crit Rev Biochem Mol Biol* 2002;37:149-66.
 20. Leeman MF, McKay JA, Murray GI. Matrix metalloproteinase-13 activity is associated with poor prognosis in colorectal cancer. *J Clin Pathol* 2002;55:758-62.
 21. Huang MY, Chang HJ, Chung FY et al. MMP13 is a potential prognostic marker for colorectal cancer. *Oncol Rep* 2010;24:1241-47.
 22. Xue J, Chen Z, Gu X, Zhang Y, Zhang W. MicroRNA-148a inhibits migration of breast cancer cells by targeting MMP-13. *Tumour Biol* 2016;37:1581-90.
 23. Jin D, Tao J, Li D et al. Golgi protein 73 activation of MMP-13 promotes hepatocellular carcinoma cell invasion. *Oncotarget* 2015;6:33523-33.
 24. Ristimäki A, Sivula A, Lundin J et al. Prognostic significance of elevated cyclooxygenase-2 expression in breast cancer. *Cancer Res* 2002;62:632.
 25. Thomas P, Khokha R, Shepherd FA, Feld R, Tsao M. Differential expression of matrix metalloproteinases and their inhibitors in non-small cell lung cancer. *J Pathol* 2000;190:150-6.
 26. Johansson N, Valamo M, Grénman S. Collagenase-3(MMP-13) is expressed by tumor cells in invasive vulvar squamous cell carcinomas. *Am J Pathol* 1999;154:469-80.