

ORIGINAL ARTICLE

Efficacy of endostar combined with transcatheter arterial chemoembolization by contrast enhanced ultrasound and analysis of vascular endothelial factor and C-reactive protein levels in patients with advanced hepatocellular carcinoma under

Yu Wang¹, Zhidong Xuan¹, Xue Zheng¹, Ruoling Han², Li Zhou¹, Haixia Liu¹, Yongrong Liu¹

¹Department of Ultrasound (III), Cangzhou Central Hospital, Cangzhou 061000, P.R.China; ²Department of Ultrasound, Fourth Hospital of Hebei Medical University, Shijiazhuang 050011, P.R.China.

Summary

Purpose: To evaluate the effect of transcatheter arterial chemoembolization (TACE) under the guidance of contrast-enhanced ultrasound (CEUS) in patients with advanced hepatocellular carcinoma (HCC).

Methods: One hundred and sixty patients with HCC admitted to Cangzhou Central Hospital from April 2015 to April 2017 were enrolled. The clinical data were retrospectively analyzed. Seventy-five patients who underwent TACE according to CEUS results were selected as the observation group. The remaining 85 cases that underwent digital subtraction angiography (DSA) angiography-guided TACE were selected as the control group and were intravenously infused with 15 mg of Endostar+500 mL of normal saline once a day for 3 consecutive days (Endostar 30 mg was reperfused during the operation). Both groups were re-contrasted at 1 month (T2) and 3 months (T3) to determine whether TACE was performed again. The numbers of TACEs re-performed were recorded. Color Doppler energy imaging was used to observe the neovascularization of the tumor. The changes of serum vascular endothelial growth factor (VEGF) and CRP levels were detected by enzyme-linked immunosorbent assay (ELISA).

Results: There were significant differences in the number of TACEs re-performed between the observation group and the control group ($p<0.05$). The serum VEGF level in the observation group was always lower than that in the control group ($p<0.05$). CRP levels in the control group showed an upward trend. The serum CRP level in the control group was significantly higher compared to the observation group at T3. The number of grades 0 and 1 neovascularization in the control group was significantly lower than in the observation group. The neovascularization rate of the observation group was significantly higher than the control group; the tumor effective rate of the observation group was not different from that of the control group, but the disease control rate was higher than in the control group.

Conclusion: CEUS-guided TACE treatment of HCC can effectively inhibit tumor angiogenesis, control tumor progression, and prolong the survival of patients, which is conducive to the prognosis of patients.

Key words: advanced hepatocellular carcinoma, contrast enhanced ultrasonography, C-reactive protein, endostar, transcatheter arterial chemoembolization, vascular endothelial growth factor

Introduction

Hepatocellular carcinoma (HCC) is one of the top ten tumors in the world. About 300,000 people in China die every year because of HCC [1]. Only

10-25% of patients can undergo surgical resection, and most patients are diagnosed at advanced stages when they visit the hospital, thus missing

Corresponding author: Dr. Yu Wang, PhD. Department of Ultrasound (III), Cangzhou Central Hospital, No.16 Xinhua West Rd, Cangzhou 061000, P.R.China
Tel: +89 153507717302, Fax: +89 0317 2075685, Email: rr22mw@163.com
Received: 15/05/2019; Accepted: 11/06/2019

the opportunity of radical surgery. The preferred treatment is transcatheter arterial chemoembolization (TACE) [2,3]. TACE refers to the selective or super-selective insertion of a catheter into a tumor-supplying target artery and an appropriate amount of embolic agent is injected at an appropriate rate to occlude the target artery so as to cause ischemic necrosis of the tumor tissue [4,5]. Although TACE can cause tumor necrosis, the tumor neovascularization induced by ischemia and hypoxia is easy to cause tumor recurrence and metastasis, reducing long-term survival rate [6,7]. Endostar is a recombinant human endostatin that inhibits vascular endothelium and formation of neovascularization [7]. HCC is a vascular-dependent tumor and Endostar can inhibit recurrence and metastasis of HCC by inhibiting angiogenesis [8]. To accurately determine the tumor size and blood supply is very important for the determination of the amount of embolization agent, it is also important for the postoperative efficacy, and it has a decisive effect on whether TACE should be performed again.

VEGF is a vascular endothelial cell-specific heparin-binding growth factor that induces angiogenesis *in vivo*. Studies have reported that the expression of VEGF in HCC is associated with angiogenesis [9]. C-reactive protein (CRP) is an inflammatory marker of systemic and local inflammation. CRP levels are elevated in the active phase of many diseases. It has been reported that CRP is closely related to the prognosis of HCC after intervention [10] and it is an independent predictor for the post-

operative recurrence of HCC [11]. At present, under the guidance of DSA after TACE, the tumor size, vascular supply, and the amount of embolization agent are judged and whether TACE will be performed again after surgery are determined. CEUS, as a blood flow detection technique, is widely used in the diagnosis and treatment of HCC. It has high sensitivity, real-time convenience, and no radiation in the evaluation of tumor neovascularization [12,13]. However, there are scarce reports on whether CEUS-guided Endostar and TACE in the treatment of patients with advanced HCC need to have TACE again and the effects of the method on VEGF, CRP and prognosis.

This article evaluated the efficacy of Endostar and TACE in the treatment of patients with advanced HCC under the guidance of CEUS and measured the levels of VEGF and CRP in order to provide a new guidance method, a more objective and effective assessment method of tumor size and blood supply for TACE, with the aim of improving the efficacy of TACE and patient prognosis.

Methods

Research objects

A total of 160 patients with HCC who were admitted to Cangzhou Central Hospital from April 2015 to April 2017 were enrolled and 75 of them underwent TACE as the observation group according to the results of ultrasound angiography. The remaining 85 cases that underwent DSA angiography-guided TACE were selected as the control group. Inclusion criteria were as follows: pathologically confirmed as HCC; age >18 years; Child Pugh grade A-B; Barcelona Clinic Liver Cancer (BCLC stage) B-C; no obstruction in portal vein, no bile duct infiltration; no other related treatment; expected survival more than 3 months, signed informed consent form and voluntary to participate in the study. Exclusion criteria were as follows: obstruction in portal vein; presence of refractory ascites; complicated with other diseases such as heart, liver, and kidney; contraindications for Endostar; incomplete clinical data.

This study has been approved by the ethics committee of Cangzhou Central Hospital.

Kit material

Endostar (Shandong Simcere Bio-Pharmaceutical Co., Ltd., CFDA Approval No. S20050088); VEGF Human ELISA Kit (Thermo Fisher Scientific, # KHG0111); Human CRP ELISA Test Kit (Jianglai Bio, JL46268); SonoVue 03 (Bracco, Milan, Italy); lipiodol emulsion (Shanghai Xudong Haipu Pharmaceutical Co., Ltd., batch number: 060109); microsphere (Biosphere Medical, France).

Treatment groups

All patients were intravenously infused with 15 mg of Endostar (diluted with 500 mL normal saline) once

Table 1. Grading of tumor angiogenesis control

Grade	
0	No dot-like blood flow in the tumor
1	1-2 dot-like blood flow in the tumor
2	3-4 points of blood flow in the tumor, 1-2 blood vessels
3	The number of dot-like blood flow in the tumor was >4, and the number of blood vessels was >2.

Table 2. RECIST standards

RECIST criteria	Tumor condition
Complete remission (CR)	No intrahepatic lesions
Partial remission (PR)	Target lesion reduction $\geq 30\%$
Stable (SD)	Criteria not achieved for complete or partial remission, no progress.
Progress (PD)	<i>In situ</i> lesions with a maximum diameter increase of >20% or new lesions or extrahepatic metastasis

a day for a total of 3 days. Using Seldinger technique, the catheter sheath was introduced through the femoral artery puncture and the catheter was placed through the catheter sheath. After super-selecting the tumor feeding artery, 3 mL of lipiodol emulsion were infused (30 mg/m² lobaplatin+30 mg/m² epirubicin+lipiodol, the amount was determined according to the patient's tumor size and blood supply), 30 mg of Endostar was reperfused, then refilled with the remaining lipiodol emulsion, and finally injected a small amount of (about 400) Embosphere embolization microspheres to embolize the blood vessels. Both groups were treated with routine hepatoprotective and infection preventive treatment. One month after operation, the observation group underwent CEUS (contrast agent: SonoVue 03) to review the embolization effect and the control group underwent DSA to observe whether the lesions were within the embolization range and the deposition of lipiodol embolization. If the tumor was found to have residual activity, TACE treatment was performed again. If the lipiodol deposit was dense, the tumor tissue was necrotic, there was no new lesion, or no new progression, the TACE treatment was suspended. After 3 months, the two groups followed the same method and performed a different angiography method to determine whether TACE needs to be performed again. The time point of the first TACE was recorded as T1, and the time point for TACE determined by re-examination after 1 month was recorded as T2, the time point for TACE determined by re-examination after 3 months was recorded as T3.

Comparison of serum VEGF and CRP levels in the two groups

Serum VEGF and CRP were detected in the two groups at T1, T2, and T3 (serum VEGF and CRP levels were measured at all time points, and then contrast re-examination was performed. If TACE was needed to be performed, the operation should be performed after blood collection). Four mL of the patient's fasting blood were collected around 9 am. After standing for 30 min, the blood was centrifuged at 3000 r/min for 10 min and the upper serum was taken for detection by ELISA.

Tumor neovascularization

Three months after surgery, color power angiography (CPA) was used in the observation group and CT angiography was used in the control group to grade the angiogenesis. The grading standards are shown in Table 1.

Tumor control

The tumor control was evaluated by RECIST criteria 3 months after surgery. The effective rate (RR)=CR+PR, the disease control rate (DCR)=CR+PR+SD, and the RECIST criteria are shown in Table 2.

Statistics

Data were analyzed by SPSS 19.0 statistical software package (IBM, SPSS, Chicago, IL, USA). The measurement data were expressed by $\bar{x}\pm S$ and analyzed by *t*-test. Three time points in the same group were com-

Table 3. General clinical data

	Observation group (n=75) n (%)	Control group (n=85) n (%)	χ^2/t	<i>p</i>
Age (years), $\bar{x}\pm SD$	54.23±10.33	56.21±15.23	0.972	0.333
Sex			0.834	0.461
Male	46 (61.33)	58 (68.24)		
Female	29 (38.67)	27 (31.76)		
Previous liver disease			0.348	0.951
Hepatitis B	55 (73.33)	61 (71.76)		
Hepatitis C	8 (10.67)	9 (10.59)		
Alcoholic liver disease	6 (8.00)	6 (7.06)		
No	6 (8.00)	9 (10.59)		
Child-Pugh classification			0.478	0.490
A	56 (74.67)	60 (70.59)		
B	19 (25.33)	25 (29.41)		
BCLC staging			0.011	0.917
B	18 (24.00)	21 (24.71)		
C	57 (76.00)	64 (75.29)		
Tumor, $\bar{x}\pm SD$ diameter (cm)	5.32±3.54	6.43±4.12	1.833	0.0687
AFP (μg/L)			0.6499	0.4201
≤400	56 (74.67)	68 (80.00)		
>400	19 (25.33)	17 (20.00)		

Table 4. Comparison of postoperative repeated TACE in the two groups

	Observation group (n=75) n (%)	Control group (n=85) n (%)	χ^2	p
Time of repeated TACE			10.070	0.007
0	4 (5.33)	10 (11.76)		
1	26 (34.67)	45 (52.94)		
2	45 (60.00)	30 (35.29)		

Table 5. VEGF levels in the two groups (means \pm SD)

VEGF (pg/L)	Observation group (n=75)	Control group (n=85)	t	p
T1	12.32 \pm 3.21	12.19 \pm 2.98	0.316	0.753
T2	12.87 \pm 2.54	13.24 \pm 3.12 ^a	0.410	0.826
T3	13.92 \pm 3.21 ^{ab}	15.35 \pm 3.76 ^{ab}	2.595	0.010
F	6.871	10.07		
P	0.001	0.007		

^aIn the same group, compared with T1, p<0.05. ^bIn the same group, p<0.05 compared with T2

pared using one-way ANOVA. The enumeration data were analyzed by chi-square test, and the significance level was $\alpha=0.05$.

Results

Comparison of general clinical data between the two groups

There were no significant differences in age, gender, previous history of liver disease, Child-Pugh classification, BCLC stage, tumor diameter and AFP content between the two groups ($p>0.05$), as shown in Table 3.

Comparison of postoperative TACE in the two groups

There were significant differences in the number of TACEs re-performed between the observation and the control group ($p<0.05$). Sixty percent of the observation group needed 2 more TACEs and 64.70% of the control group needed 0 or 1 more TACE (Table 4).

Comparison of VEGF levels in the two groups

At the time of T1 and T2, there was no significant difference in serum VEGF levels between the observation and the control group ($p>0.05$). The VEGF level in the serum at T3 was significantly lower than that in the control group ($p<0.05$). Serum VEGF levels in the observation group at T3 were significantly higher than those at T1 and T2 and there was no significant difference in serum VEGF levels between T1 and T2. Serum VEGF levels in the control group at T3 were significantly higher than those at T1 and T2. The serum VEGF

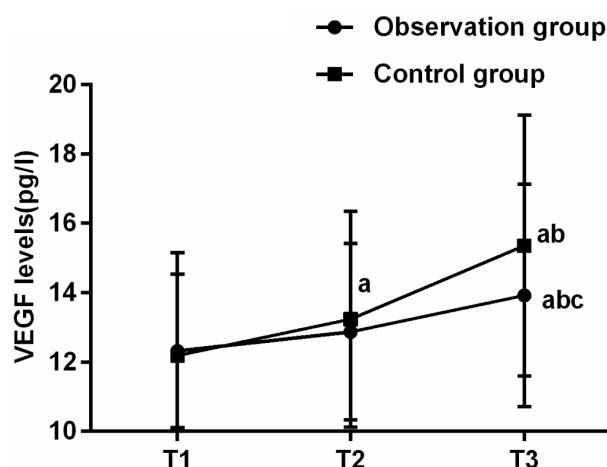


Figure 1. Comparison of VEGF levels between the two groups. The ELISA results showed that there was no significant difference in serum VEGF levels between the observation group and the control group at T1 and T2 ($p>0.05$). The serum VEGF level in the observation group was significantly lower than that in the control group at T3 ($p<0.05$). Serum VEGF levels in the observation group at T3 were significantly higher than those at T1 and T2 and there was no significant difference in serum VEGF levels between T1 and T2. Serum VEGF levels in the control group at T3 were significantly higher than those at T1 and T2. The serum VEGF level at T2 was significantly higher than that at T1. Note **a**: in the same group, compared with T1, $p<0.05$. **b**: in the same group, $p<0.05$ compared with T2. **c**: at the same time, $p<0.05$ compared with the control group.

level at T2 was significantly higher than that at T1, as shown in Table 5 and Figure 1.

Comparison of CRP levels between the two groups

At the time of T1 and T2, there was no significant difference in serum CRP levels between

the observation and the control group ($p>0.05$). The serum CRP level at T3 was significantly lower than that in the control group ($p<0.05$). There was no significant difference in serum CRP levels in the observation groups at T1, T2 and T3 ($p>0.05$). Serum CRP levels in the control group at T3 were significantly higher than those in T1 and T2. There was no difference in serum CRP levels between T1 and T2 ($p>0.05$), as shown in Table 6 and Figure 2.

Tumor neovascularization

Three months after surgery, color doppler energy imaging (CPA) was used in the observation group and CT angiography was used in the control group to detect tumor angiogenesis (Table 7). Seventy two percent of the observation group had no neovascularization, 10 cases (13.33%) had > grade 2 neovascularization, and the number of grade 0 and 1 in the control group was significantly lower than that in the observation group. There were 44 cases (51.76%) of neovascularization above grade 2 in the control group. The neovascularization rate of the observation group was significantly higher than that of the control group ($p<0.05$), as shown in Table 7.

Tumor control

The tumor control was evaluated by RECIST criteria 3 months after surgery. The tumor control scores of the observation group were significantly different from those of the control group. The RR of the observation group and the control group were 38 (50.67%) and 32 (37.65%), respectively. There

was no significant difference between the two groups. The DCR of the observation group and the control group were 62 (82.67%) and 45 (52.94%), respectively. The tumor control rate of the observation group was significantly higher than that of the control group, as shown in Table 8.

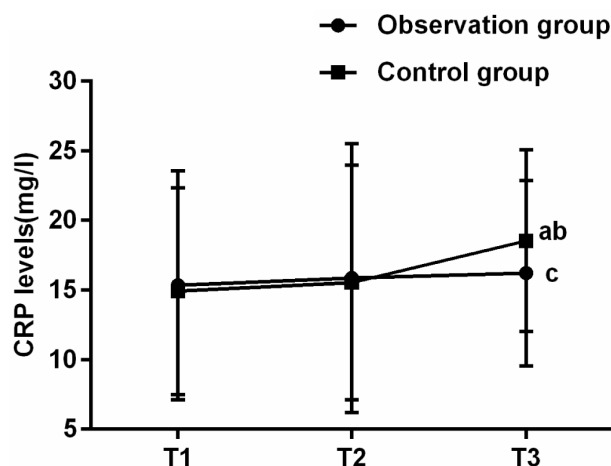


Figure 2. Comparison of CRP levels between the two groups. The ELISA results showed that there was no significant difference in serum CRP levels between the observation group and the control group at T1 and T2 ($p>0.05$). The serum CRP levels in the observation group were significantly lower than that in the control group at T3 ($p<0.05$). There was no significant difference in serum CRP levels between T1, T2, and T3 in the observation group ($p>0.05$). Serum CRP levels in the control group at T3 were significantly higher than those at T1 and T2 and there was no difference in serum CRP levels between T1 and T2 ($p>0.05$). Note **a**: in the same group, compared with T1, $p<0.05$. **b**: in the same group, $p<0.05$ compared with T2. **c**: at the same time, $p<0.05$ compared with the control group.

Table 6. CRP levels in the two groups (means±SD)

CRP (mg/L)	Observation group (n=75)	Control group (n=85)	t	p
T1	15.34±8.23	14.93±7.43	0.329	0.743
T2	15.86±9.65	15.54±8.43 ^a	0.222	0.825
T3	16.21±6.65	18.54±6.54 ^{ab}	2.229	0.027
F	0.210	5.633		
P	0.811	0.004		

^aIn the same group, compared with T1, $p<0.05$. ^bIn the same group, $p<0.05$ compared with T2

Table 7. Tumor neovascularization

	Observation group (n=75) n (%)	Control group (n=85) n (%)	χ^2	p
Grading of neovascularization			26.830	0.000
0	54 (72.00)	32 (37.65)		
1	11 (14.67)	9 (10.59)		
2	6 (8.00)	23 (27.06)		
3	4 (5.33)	21 (24.71)		

Table 8. Tumor control

	Observation group (n=75) n (%)	Control group (n=85) n (%)	χ^2	p
Grading of tumor control			16.990	0.001
CR	15 (20.00)	13 (15.29)		
PR	23 (30.67)	19 (22.35)		
SD	24 (32.00)	13 (15.29)		
PD	13 (17.33)	40 (47.06)		
RR	38 (50.67)	32 (37.65)	1.578	0.115
DCR	62 (82.67)	45 (52.94)	15.890	0.000

Discussion

HCC is one of the most common malignant tumors. Among gastrointestinal malignant tumors its mortality rate is second only to gastric cancer and esophageal cancer. The 3-year survival rate is less than 15%, which seriously threatens the physical and mental health of patients and brings great burdens and economic pressure to patients and families [14]. Although surgical resection is by far the most effective treatment of HCC, most HCC patients are already in advanced stage, and the tumor cannot be surgically removed, and only interventional therapy such as TACE can be performed. At present, the use of embolic agents and whether or not to repeat TACE mostly depends on DSA. CEUS, as a highly sensitive blood flow detection technology, can not only visually judge the therapeutic effect but also assist in the preoperative precise positioning of lesions [15,16], but the current application and feasibility study of CEUS guidance combined with TACE in the treatment of HCC has rarely been reported. Therefore, in this study, the efficacy of Endostar and TACE in the treatment of advanced HCC patients under the guidance of CEUS was evaluated and the VEGF, CRP levels were analyzed, in order to improve the therapeutic effect of TACE, improve patient prognosis, and reduce the probability of recurrence and metastasis.

The number of TACEs re-performed 0 or 1 time in the observation group was significantly lower than that in the control group, while the number of TACEs repeated twice in the observation group was significantly higher than that in the control group, indicating that, compared with the DSA, TACE treatment under the guidance of CEUS increased the number of re-performed TACEs. The possible explanation was that CEUS was more sensitive to embolization than DSA. The level of VEGF reflects the neovascularization of tumors; VEGF can specifically promote the proliferation and migration of vascular endothelial cells and promote tumor angiogenesis, which is one of the important indi-

cators for evaluating the therapeutic effect in HCC [17]. There was no significant difference in serum VEGF levels between the observation group and the control group at T1. The levels of serum VEGF at T2 and T3 showed an upward trend, indicating that the VEGF level was induced to increase by ischemia and hypoxia in tumor tissues caused by TACE. Although Endostar was used for prophylaxis, it did not completely reverse the increase in VEGF levels. The serum VEGF level in the observation group was always lower than that in the control group, and there was a significant difference at T3, indicating that the neovascularization of the observation group was inhibited to a certain extent, which may be related to the higher number of repeated TACE in the observation group. The neovascularization control rate of the observation group was significantly better than that of the control group, which was consistent with the level of VEGF.

CRP is an acute-phase reactive protein that is used primarily to assess the extent of early inflammation and tissue damage and its level is positively correlated with the degree of inflammation and tissue damage [18]. Studies have shown that CRP is closely related to the prognosis of HCC and the progressive elevation of CRP suggests metastasis or spread of HCC [19]. There was no difference in serum CRP levels between T1, T2, and T3 in the observation group. The serum CRP levels in the control group at T1, T2, and T3 showed an upward trend. There was no difference in serum CRP levels between the observation group and the control group at T1 and T2. CRP levels in the observation group at T3 were significantly higher than those in the control group and the treatment efficacy of CEUS-guided TACE was better than DSA-guided TACE.

There was no difference between the observation group and the control group in terms of PR. The tumor control rates of the observation group and the control group were significantly different. The tumor DCR of the observation group was sig-

nificantly better than that of the control group. It is indicated that compared with DSA-guided TACE, the use of color Doppler ultrasound to guide TACE cannot improve the effectiveness of TACE on tumors, but it can slow down the progress of tumors and strive for a little survival time for patients with advanced HCC.

Lu et al [20] studied the clinical value of CEUS and enhanced CT in the evaluation of the efficacy of TACE in HCC. It was found that the accuracy of CEUS test results was higher than that of enhanced CT test and its accuracy was close to DSA test results, which is inconsistent with the results of this paper. The possible reason is that CEUS was compared with DSA in this article, with CPA as a standard to evaluate angiogenesis and tumor control and CPA as a bridge to compare CEUS with DSA, while Bruenn et al [21] compared CEUS with enhanced CT and took the results of DSA as the standard. It was concluded that the specificity of CEUS under the standard of DSA was 100% and the positive predictive value was 100%. The conclusion that CEUS and DSA had close performance in the diagnosis of TACE in HCC was incorrect, because the DSA cannot be a standard when comparing the diagnostic performance of CEUS and DSA. The negative predictive value of CEUS with DSA as a standard was only 50%, which indicates that there was a certain difference in the diagnostic performance of CEUS and DSA. Chen et al [22] studied CEUS in the prediction of the response/recurrence of hepatic malignant focal lesions after radiofre-

quency ablation (RFA) or TACE and observed that there was no adverse reaction after CEUS and the combined effect with CT/MRI was better. Therefore, CEUS can be combined with CT/MRI to improve the detection scheme proposed in this paper.

The limitation of this study is that pathological section was not used as the gold standard to calculate specificity, sensitivity, and negative predictive value. Since this study is a retrospective analysis, the patients with liver cancer were confirmed pathologically before and after TACE many times, which is not necessary in most cases. Imaging techniques and other biochemical indicators should be used first and highly suspected patients should be followed by pathological examination [23,24]. Another limitation of this study is that the follow-up time was relatively short and only three months after surgery. To further investigate the long-term efficacy of CT and CEUS after TACE, the follow-up time can be extended to 1 year, 3 years, or even 5 years after surgery.

In summary, compared with TACE under the guidance of DSA, CEUS-guided TACE combined with Endostar treatment of HCC can effectively inhibit the formation of tumor angiogenesis, control tumor progression, and prolong the survival time of patients, which is beneficial for patient prognosis.

Conflict of interests

The authors declare no conflict of interests.

References

1. Wang WP, Wu Y, Luo Y et al. Clinical value of contrast-enhanced ultrasonography in the characterization of focal liver lesions: a prospective multicenter trial. *Hepatobiliary Pancreat Dis Int* 2009;8:370-6.
2. Park KH, Kwon SH, Lee YS et al. Predictive factors of contrast-enhanced ultrasonography for the response to transarterial chemoembolization in hepatocellular carcinoma. *Clin Mol Hepatol* 2015;21:158-64.
3. Lee DH, Lee JM, Kang TW et al. Clinical Outcomes of Radiofrequency Ablation for Early Hypovascular HCC: A Multicenter Retrospective Study. *Radiology* 2018;286:338-49.
4. Uller W, Wiggermann P, Gossmann H et al. Evaluation of the microcirculation of hepatocellular carcinomas using contrast-enhanced ultrasound with intraarterial and intravenous contrast application during transarterial chemoembolization with drug-eluting beads (DEB-TACE): preliminary data. *Clin Hemorheol Microcirc* 2011;49:55-66.
5. Lencioni R, Llovet JM, Han G et al. Sorafenib or placebo plus TACE with doxorubicin-eluting beads for intermediate stage HCC: The SPACE trial. *J Hepatol* 2016;64:1090-8.
6. Raut CP, Izzo F, Marra P et al. Significant long-term survival after radiofrequency ablation of unresectable hepatocellular carcinoma in patients with cirrhosis. *Ann Surg Oncol* 2005;12:616-28.
7. Zhang ZY, Chen LL, Xu W, Sigdel K, Jiang XT. Effects of silencing endothelin-1 on invasion and vascular formation in lung cancer. *Oncol Lett* 2017;13:4390-6.
8. Cong N, Li Z, Shao W, Li J, Yu S. Endothelin-1 Induces Hepatocellular Carcinoma Cell Migration and Invasion via ERK1/2 and AKT Signaling Pathways. *J Membr Biol* 2016;249:119-28.
9. Pang R, Poon RT. Angiogenesis and antiangiogenic therapy in hepatocellular carcinoma. *Cancer Lett* 2006;242:151-67.

10. Jun CH, Ki HS, Lee KH et al. Impact of serum C-reactive protein level on the prognosis of patients with hepatocellular carcinoma undergoing TACE. *Clin Mol Hepatol* 2013;19:70-7.
11. Kim JM, Kwon CHD, Joh JW et al. C-reactive protein may be a prognostic factor in hepatocellular carcinoma with malignant portal vein invasion. *World J Surg Oncol* 2013;11:92.
12. Xu HX, Lu MD, Xie XH et al. Treatment response evaluation with three-dimensional contrast-enhanced ultrasound for liver cancer after local therapies. *Eur J Radiol* 2010;76:81-8.
13. Xiang Z, Liang Q, Liang C, Zhong G. The correlation of contrast-enhanced ultrasound and MRI perfusion quantitative analysis in rabbit VX2 liver cancer. *Cell Biochem Biophys* 2014;70:1859-67.
14. Wiggermann P, Heibl M, Niessen C et al. Degradable starch microspheres transarterial chemoembolisation (DSM-TACE) of HCC: Dynamic Contrast-Enhanced Ultrasonography (DCE-US) based evaluation of therapeutic efficacy using a novel perfusion software. *Clin Hemorheol Microcirc* 2012;52:123-9.
15. Ross CJ, Rennert J, Schacherer D et al. Image fusion with volume navigation of contrast enhanced ultrasound (CEUS) with computed tomography (CT) or magnetic resonance imaging (MRI) for post-interventional follow-up after transcatheter arterial chemoembolization (TACE) of hepatocellular carcinomas (HCC): Preliminary results. *Clin Hemorheol Microcirc* 2010;46:101-15.
16. Guerrini GP, Berretta M, Tarantino G et al. Multimodal oncological approach in patients affected by recurrent hepatocellular carcinoma after liver transplantation. *Eur Rev Med Pharmacol Sci* 2017;21:3421-35.
17. Leelawat K, Laisupasin P, Kiatdilokrut A et al. The effect of doxorubicin on the changes of serum vascular endothelial growth factor (VEGF) in patients with hepatocellular carcinoma after transcatheter arterial chemoembolization (TACE). *J Med Assoc Thai* 2008;91:1539-43.
18. Slaats J, Ten Oever J, van de Veerdonk FL, Netea MG. IL-1beta/IL-6/CRP and IL-18/ferritin: Distinct Inflammatory Programs in Infections. *PLoS Pathol* 2016;12:e1005973.
19. Li Z, Xue TQ, Chen XY. Predictive values of serum VEGF and CRP levels combined with contrast enhanced MRI in hepatocellular carcinoma patients after TACE. *Am J Cancer Res* 2016;6:2375-85.
20. Lu MD, Yu XL, Li AH et al. Comparison of contrast enhanced ultrasound and contrast enhanced CT or MRI in monitoring percutaneous thermal ablation procedure in patients with hepatocellular carcinoma: a multi-center study in China. *Ultrasound Med Biol* 2007;33:1736-49.
21. Bruenn K, Beyer I, Haimeri M et al. Comparison of computed tomography (CT) and contrast-enhanced ultrasound (CEUS) for the quantitative evaluation of an ablation defect following radiofrequency ablation of malignant liver lesions. *Clin Hemorheol Microcirc* 2017;67:445-50.
22. Chen MH, Wu W, Yang W et al. The use of contrast-enhanced ultrasonography in the selection of patients with hepatocellular carcinoma for radio frequency ablation therapy. *J Ultrasound Med* 2007;26:1055-63.
23. Ghanaati H, Alavian SM, Firouznia K et al. Tailoring of interventional procedures for HCC patients-review article. *Iranian J Radiol* 2010;7:129-43.
24. Terzi E, Kim WR, Sanchez W et al. The Impact of Multiple TACE Treatments on Hepatocellular Carcinoma for Patients Awaiting Liver Transplantation. *Liver Transplant* 2015;21:248-57.