

ORIGINAL ARTICLE

# Efficacy of transcatheter arterial chemoembolization combined with <sup>125</sup>I seed implantation and three-dimensional conformal radiotherapy in advanced primary hepatocellular carcinoma

Huanyun Zhang<sup>1</sup>, Aiyan Yang<sup>1</sup>, Jing Zhang<sup>2</sup>

<sup>1</sup>Department of Radiotherapy, Linyi Cancer Hospital, Linyi, China; <sup>2</sup>Department of Image Division, Linyi Cancer Hospital, Linyi, China.

## Summary

**Purpose:** To investigate the efficacy and safety of transcatheter arterial chemoembolization (TACE) combined with iodine-125 (<sup>125</sup>I) seed implantation and three-dimensional conformal radiotherapy (3DCRT) in treating primary hepatocellular carcinoma (HCC) in the advanced stage.

**Methods:** A total of 110 primary HCC patients in the advanced stage without operative indications admitted to and treated in our hospital from March 2014 to March 2016 were selected and divided into two groups using randomized single-blind method to receive TACE and <sup>125</sup>I seed implantation combined with 3DCRT (TACE+<sup>125</sup>I+3DCRT group, n=55) as well as TACE combined with 3DCRT (TACE+3DCRT group, n=55) separately. The short-term clinical efficacy, changes in the levels of alpha fetoprotein (AFP), insulin-like growth factor-II (IGF-II) and insulin-like growth factor binding protein-2 (IGFBP-2) in the serum before and after treatment, adverse reactions and long-term survival of the patients were observed and recorded.

**Results:** TACE+<sup>125</sup>I+3DCRT group had significantly higher objective response rate (ORR) and disease control rate (DCR) than TACE+3DCRT group [83.6% (46/55) vs. 63.6% (35/55), 96.4% (53/55) vs. 83.6% (46/55)] ( $p=0.029$ ,  $p=0.043$ ). The levels of serum AFP, IGF-II and IGFBP-2 declined markedly after treatment in both groups compared with those

before treatment ( $p<0.001$ ), while they were evidently lower in TACE+<sup>125</sup>I+3DCRT group than TACE+3DCRT group ( $p=0.008$ ,  $p=0.004$ ,  $p=0.018$ ). The major adverse reactions in the patients after treatment included bone marrow suppression, fever, gastrointestinal reaction, transaminase elevation, radiodermatitis, radiation-induced hepatitis and radiation-induced gastric ulcer, most of which were in I-II grade. There was no statistically significant difference in the incidence rate of adverse reactions between the two groups of patients after chemoradiotherapy ( $p>0.05$ ). The results of follow-up indicated that TACE+<sup>125</sup>I+3DCRT group had notably longer overall survival (OS) and progression-free survival (PFS) than TACE+3DCRT group ( $p=0.030$ ,  $p=0.016$ ).

**Conclusions:** The treatment scheme of TACE and <sup>125</sup>I seed implantation combined with 3DCRT have exact efficacy in advanced primary HCC, which can distinctly increase the ORR and DCR, prominently reduce the levels of serum AFP, IGF-II and IGFBP-2 and prolong the survival time of the patients without increasing adverse reactions compared with TACE+3DCRT, so it is worthy of clinical popularization and application.

**Key words:** transcatheter arterial chemoembolization, <sup>125</sup>I seed, three-dimensional conformal radiotherapy, primary hepatocellular carcinoma, advanced stage, efficacy

## Introduction

Primary hepatocellular carcinoma (HCC) is the most common malignant tumor of the digestive tract in China, with high malignancy and rapid pro-

gression, and radical resection is the best means to treat the disease. However, most HCC patients have lost the chance of operation due to the mani-

Corresponding author: Jing Zhang, BM. Department of Image Division, Linyi Cancer Hospital, Linyi, China.  
No. 6 Mausoleum East Street, Linyi, 276000 China.  
Tel: 86015964826755, Email: zhangjingly\_2018@163.com  
Received: 04/09/2019; Accepted: 02/10/2019

festations of massive-type tumors, multiple lesions or collapsed liver functions at the time of diagnosis [1]. Transcatheter arterial chemoembolization (TACE) is the recognized preferred treatment for HCC patients unsuitable for surgical resection, but it needs to be conducted repeatedly and leads to a high recurrence rate with poor long-term results, especially for patients with poor hepatic artery blood supply [2,3]. Therefore, the comprehensive application of radical and minimally invasive treatments is the key to further improve the therapeutic effect. In recent years, iodine-125 (<sup>125</sup>I) seed implantation, characterized by short radiation distance and small damage to surrounding tissues, has been applied in the treatment of HCC, and it can guarantee a higher dose at the tumor site, obviously enhancing the therapeutic effect of TACE alone [4,5]. With the development of radiotherapy and imaging technology, three-dimensional conformal radiation therapy (3DCRT) has manifested prominent effects on primary HCC [6,7].

In this research, the clinical data of 110 HCC patients in the advanced stage admitted to and treated in our hospital from March 2014 to March 2016 were retrospectively reviewed, and the efficacy and safety of TACE and <sup>125</sup>I seed implantation combined with 3DCRT as well as TACE combined with 3DCRT in treating those patients were com-

pared and analyzed, so as to provide a more scientific basis for the formulation of efficacious treatment protocols.

## Methods

### General data

A total of 110 patients with advanced primary HCC who were admitted to and treated in our hospital from March 2014 to March 2016 were enrolled as the study subjects. All the patients had performed computed tomography (CT) plain scan with enhancement and/or magnetic resonance imaging (MRI) examination as well as percutaneous liver biopsy before treatment. Patients with measurable/evaluable tumor lesions definitely diagnosed via pathology and cytology, those with a liver function Child-Pugh grade A or B, and those with a Karnofsky performance score  $\geq 60$  points were selected. *Exclusion criteria:* patients previously treated with liver surgery, chemoradiotherapy, TACE or radiofrequency ablation, those with a tumor occupying over 70% of the liver volume or with diffuse HCC, those with spontaneous rupture or hemorrhage of HCC, uncontrolled ascites, hemorrhagic tendency, hepatic metastasis or liver transaminase level 3-fold higher than the upper limit of normal, or those complicated with a history of iodine allergy, diabetes mellitus, severe liver cirrhosis or serious heart, kidney or brain diseases. The diagnosis of primary HCC was confirmed based on the Evidence-based practice guidelines for the standardized pathological diag-

**Table 1.** Demographics and general clinical data of all studied patients

Parameters	TACE+ <sup>125</sup> I+3DCRT group (n=55)	TACE+3DCRT group (n=55)	p-value
Gender (Male/Female)	36/19	30/25	0.331
Age (years)	54.34±9.48	56.30±10.06	0.295
Number of tumors			0.340
1	26 (64.4%)	32 (69.5%)	
$\geq 2$	29 (35.6%)	23 (30.5%)	
Tumor diameter (cm)	6.1±1.9	5.8±1.6	0.372
UICC staging			0.337
III	28 (50.8%)	34 (61.0%)	
IV	27 (49.2%)	21 (39.0%)	
Child-Pugh class			0.560
A	35 (72.9%)	31 (81.4%)	
B	20 (27.1%)	24 (18.6%)	
AFP (ng/ml)			0.445
$\geq 400$	32 (23.7%)	27 (16.9%)	
< 400	23 (76.3%)	28 (83.1%)	
PVTT	37	33	0.552
HBsAg (+)	30 (57.6%)	35 (66.1%)	0.438
Karnofsky score			0.548
80-90	17 (42.4%)	21 (33.9%)	
60-80	38 (42.4%)	34 (42.4%)	

TACE: Transcatheter arterial chemoembolization; 3DCRT: 3 dimensional conformal radiation therapy; UICC: Union for International Cancer Control; AFP: alpha fetoprotein; PVTT: Portal vein tumor thrombus

nosis of primary liver cancer (2015 update). 110 patients with primary HCC meeting the diagnosis were selected according to the inclusion and exclusion criteria, including 66 males and 44 females aged 29-71 years, with an average age of 55.8±9.6 years. In terms of the liver function Child-Pugh classification, there were 66 cases of grade A and 44 cases of grade B. As for the UICC stage, 62 patients were in stage III and 48 patients in stage IV. There were 58 cases of solitary tumor and 52 cases of multiple tumors in the liver, with a maximum lesion diameter of 9.3 cm. Fifty-nine patients had an alpha fetoprotein (AFP) level >400 ng/mL, 65 patients were HBsAg positive, and 70 patients had portal vein tumor thrombus. All the 110 patients were assigned into TACE+<sup>125</sup>I+3DCRT group (n=55) and TACE+3DCRT group (n=55) using randomized single-blind method. The clinical data of the patients were comparable between the two groups (p>0.05) (Table 1). According to the *Declaration of Helsinki*, the duty of disclosure was performed, and all the patients enrolled signed informed consent. This study was approved by the Ethics Committee of Linyi Cancer Hospital.

#### Therapeutic methods

**TACE:** After local anesthesia, percutaneous right femoral artery puncture was performed by means of Seldinger technique, 5FRH catheter was inserted into the celiac trunk and common hepatic artery, and angiography was conducted to understand the local blood supply. Then a superselective catheter was sent to the proper hepatic artery, arterial branches and superior mesenteric artery. Next, 5-fluorouracil (150 mg/m<sup>2</sup>), epirubicin (50 mg/m<sup>2</sup>), mitomycin C (10 mg) and lipiodol (10-15 mL) were mixed and injected into the target arteries. Finally, gelatin sponge microparticles (1 mm) were used for embolism. If arteriovenous fistula occurred, the gelatin sponge would be applied to block up the fistula first, and then the treatment with TACE was performed. The treatment was conducted once every 4 weeks for 2-3 consecutive times, and hepatoprotective treatment such as oral Bicyclol was adopted during chemoradiotherapy.

**<sup>125</sup>I seed implantation:** <sup>125</sup>I seed implantation was implemented at 3-4 weeks after the treatment with TACE. First, CT scan was applied to formulate the treatment plan and delineate the target area. Then the prescribed doses were prepared, and the target volume and matched peripheral dose (MPD) were calculated. Later, the isodose curves, radioactivity of the seeds and spatial distribution of the seeds needed were plotted, and the path of needle insertion and the number of needles and seeds were determined. The <sup>125</sup>I seeds were retrograde implanted at 0.5-1 cm apart with a Mick applicator guided by CT under local anesthesia. It should be ensured that the needles reach the deepest site of the lesion (about 1 cm away from the tumor margin, without bleeding in resorption), and the damage to the great vessels should be avoided. The MPD of the tumor was 90-140 Gy. CT scan was employed intraoperatively for verification, and the seeds were implanted in the dose defective regions immediately in the case of maldistribution or omission of the seeds.

**3DCRT:** The patients were subjected to 3DCRT at 4-6 weeks after <sup>125</sup>I seed implantation. CT scan was adopted for location, and the target area and organs at risk were delineated by reference to the lesions displayed on plain and enhanced CT or plain and enhanced MRI of the liver. The planning target volume was determined in accordance with the liver mobility with breath, and the optimal treatment plan was decided through comprehensive evaluation. 2-6 radiation fields were set, with the prescribed dose at 45-60 Gy (2 Gy/time). The treatment plan was optimized by the dose-volume histogram. The planning target area was surrounded by 90% isodose lines, with D<sub>max</sub> ≤22.5 Gy for 33% of right renal volume, D<sub>max</sub> ≤15 Gy for 1/3 of left renal volume and D<sub>mean</sub> <15 Gy for both kidneys. As for the small intestine, D<sub>50%</sub> was <20-50 Gy, and D<sub>max</sub> was ≤45-50 Gy. V20 of adjacent organs was <30%, and the radiation dose of the spinal cord was <40 Gy.

Both groups were given hepatoprotective therapy (oral Bicyclol), nutritional support and symptomatic treatments for embolism syndrome, bone marrow depression and gastrointestinal reaction after treatment.

#### Observation indexes

The short-term efficacy was evaluated by reference to the RECIST (1.1 Version), including complete response (CR) (Lesion disappears completely after treatment for >1 month), partial response (PR) (The product of maximum diameter and maximum vertical diameter of the lesion decreases by >50% for >1 month), stable disease (SD) (The product of maximum diameter and maximum vertical diameter of the lesion decreases by <50% or increases by <25%, without new lesions) and progressive disease (PD) (The product of maximum diameter and maximum vertical diameter of the lesion increases by ≥25%, or new lesions emerge). Objective response rate (ORR)=(CR+PR)/total cases ×100%, and disease control rate (DCR)=(CR+PR+SD)/total cases ×100%.

The blood was collected before treatment and at 1 month after treatment to detect the levels of serum AFP, insulin-like growth factor II (IGF-II) and insulin-like growth factor binding protein-2 (IGFBP-2), and the tumor cell burden in the body was assessed. With regard to the radiation injuries, the adverse reactions of radiotherapy were evaluated according to the criteria recommended by RTOG, and the toxic reactions of chemotherapy were assessed based on the NCI-CTCAE3.0. The patients were followed up to record the long-term survival conditions, of which progression-free survival (PFS) refers to the period from the start of treatment to the day of disease progression or death, and overall survival (OS) refers to the period from the start of treatment to the day of death or last follow-up or end of follow-up. For patients lost to follow-up, the survival was calculated until the day of last follow-up. The follow-up ended in March 2019.

#### Statistics

SPSS 22.0 (IBM, Armonk, NY, USA) was adopted for statistical analysis. The measurement data were expressed as mean±standard deviation (x±s), and two-sample t-test was performed for inter-group comparison.

son. The enumeration data were presented as ratio (%),  $\chi^2$  test was conducted for inter-group comparison, and  $p < 0.05$  suggested that the difference was statistically significant. Kaplan-Meier method was applied to plot the survival curves, log-rank test was utilized to compare the difference in survival rate between the two groups, and  $p < 0.05$  suggested that the difference was statistically significant.

## Results

### Evaluation of short-term efficacy

In TACE+<sup>125</sup>I+3DCRT group, there were 4 cases of CR, 42 cases of PR, 7 cases of SD and 2 cases of PD. The ORR was 83.6% (46/55), and the DCR was 96.4% (53/55). TACE+3DCRT group exhibited 1 case of CR, 34 cases of PR, 11 cases of SD and 9 cases of PD, with an ORR of 63.6% (35/55) and a DCR of 83.6% (46/55). TACE+<sup>125</sup>I+3DCRT group had remarkably higher ORR and DCR than TACE+3DCRT group, and the differences were statistically significant ( $p = 0.029$ ,  $p = 0.043$ ) (Table 2).

### Comparisons of AFP, IGF-II and IGFBP-2 levels before and after treatment between the two groups of patients

The serum AFP levels before and after treatment were (520.48±88.90) ng/mL and (292.35±71.15) ng/mL in TACE+<sup>125</sup>I+3DCRT group, and (498.33±79.67) ng/mL and (331.53±80.52) ng/mL in TACE+3DCRT

group, respectively. The serum IGF-II levels were (7.0±1.1) µg/L and (4.5±0.6) µg/L before and after treatment, respectively, in TACE+<sup>125</sup>I+3DCRT group, while they were (7.2±0.9) µg/L and (4.9±0.8) µg/L in TACE+3DCRT group, respectively. The serum IGFBP-2 levels were (8.3±1.2) µg/L and (4.8±0.6) µg/L before and after treatment, respectively, in TACE+<sup>125</sup>I+3DCRT group, which were (8.4±1.3) µg/L and (5.1±0.7) µg/L, respectively, in TACE+3DCRT group. There were no statistically significant differences in the levels of serum AFP, IGF-II and IGFBP-2 before treatment between the two groups ( $p = 0.172$ ,  $p = 0.299$ ,  $p = 0.676$ ), which were comparable. However, the levels of serum AFP, IGF-II and IGFBP-2 declined markedly after treatment in both groups compared with those before treatment ( $p < 0.001$ ), while they were evidently lower in TACE+<sup>125</sup>I+3DCRT group than TACE+3DCRT group ( $p = 0.008$ ,  $p = 0.004$ ,  $p = 0.018$ ) (Figure 1).

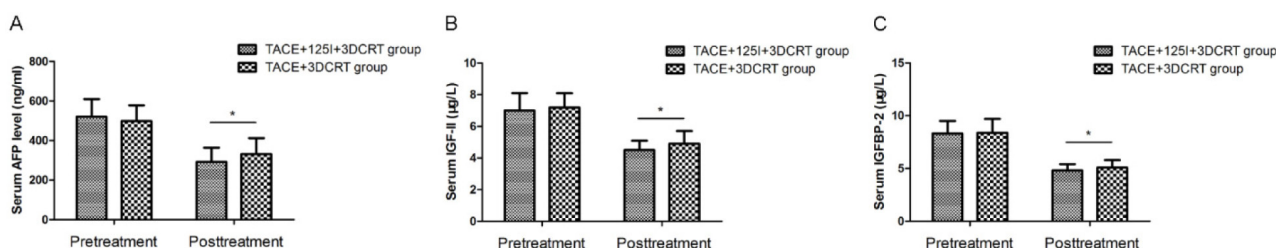
### Adverse reactions and complications

Adverse reactions in various degrees occurred in the two groups of patients during treatment, mainly including bone marrow suppression, fever, gastrointestinal reactions, transaminases' elevation, radiodermatitis, radiation-induced hepatitis and radiation-induced gastric ulcer, most of which were in I-II grade, and few adverse reactions were of III-IV grade. All the patients accom-

**Table 2.** Comparison of clinical efficacy of patients in the two groups

Parameters	TACE+ <sup>125</sup> I+3DCRT group (n=55)	TACE+3DCRT group (n=55)	p value
CR	4	1	
PR	42	34	
SD	7	11	
PD	2	9	
ORR (%)	46 (83.6%)	35 (63.6%)	0.029
DCR (%)	53 (96.4%)	46 (83.6%)	0.043

TACE: Transcatheter arterial chemoembolization; 3DCRT: 3 dimensional conformal radiation therapy; CR: Complete Response; PR: Partial Response; SD: Stable Disease; PD: Progressive Disease; ORR: Objective response rate; DCR: Disease Control Rate

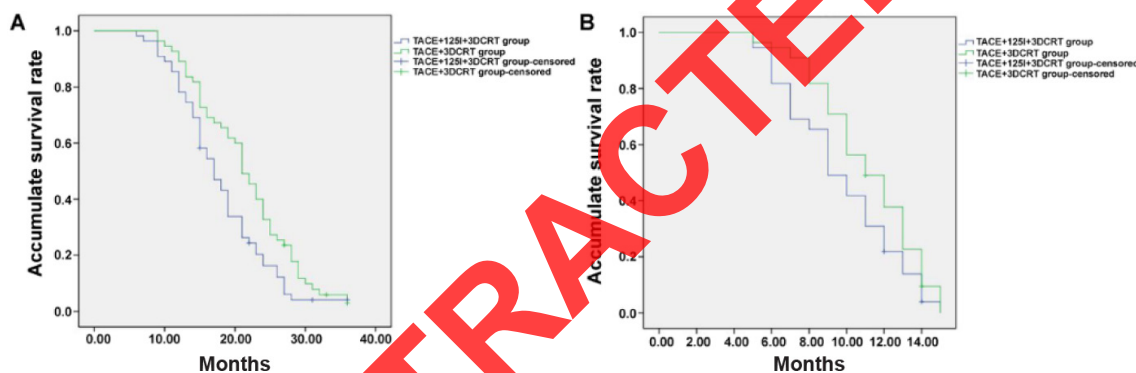


**Figure 1.** Comparison of serum AFP, IGF-II, IGFBP-2 levels of patients in the two studied groups. The difference of pretreatment serum AFP (A), IGF-II (B) and IGFBP-2 (C) levels of patients in TACE+<sup>125</sup>I+3DCRT group and TACE+3DCRT group had no statistical significance ( $p = 0.172$ ,  $p = 0.299$ ,  $p = 0.676$ ). After treatment, serum AFP (A), IGF-II (B) and IGFBP-2 (C) levels decreased dramatically in both groups. Posttreatment serum AFP (A), IGF-II (B) and IGFBP-2 (C) levels of patients in TACE+<sup>125</sup>I+3DCRT group were significantly lower than that of TACE+3DCRT group ( $p = 0.008$ ,  $p = 0.004$ ,  $p = 0.018$ ).

**Table 3.** Comparison of adverse reactions of patients in the two studied groups

Parameters	Grade I-IV		p value	Grade III-IV		p value
	TACE+ <sup>125</sup> I+3DCRT	TACE+3DCRT		TACE+ <sup>125</sup> I+3DCRT	TACE+3DCRT	
	group n (%)	group n (%)		group n (%)	group n (%)	
Anemia	11 (20.0)	7 (12.7)	0.440	0 (0)	0 (0)	1.000
Thrombocytopenia	19 (34.5)	14 (25.5)	0.406	0 (0)	0 (0)	1.000
Leukopenia	15 (27.3)	12 (21.8)	0.658	2 (3.6)	1 (1.8)	1.000
Gastrointestinal reaction	31 (56.4)	26 (47.3)	0.446	7 (12.7)	4 (7.3)	0.527
Fever	25 (45.5)	20 (36.4)	0.438	0 (0)	0 (0)	1.000
Elevated ALT/AST	19 (34.5)	13 (23.6)	0.294	1 (1.8)	0 (0)	1.000
Radiodermatitis	5 (9.1)	3 (5.5)	0.716	0 (0)	0 (0)	1.000
Radiation hepatitis	8 (14.5)	6 (10.9)	0.776	0 (0)	0 (0)	1.000
Radiation gastric ulcer	3 (5.5)	1 (1.8)	0.618	0 (0)	0 (0)	1.000

TACE: Transcatheter arterial chemoembolization; 3DCRT: 3 dimensional conformal radiation therapy; ALT: Alanine aminotransferase; AST: Aspartate aminotransferase.



**Figure 2.** Kaplan-Meier survival curves of the studied patients. The overall survival rate (A) and progression free survival rate (B) of patients in TACE+<sup>125</sup>I+3DCRT group were significantly higher than that of TACE+3DCRT group ( $p=0.030$ ,  $p=0.016$ ).

plished the chemoradiotherapy after symptomatic treatment. The incidence rate of radiation-related adverse reactions was not increased markedly in TACE+<sup>125</sup>I+3DCRT group compared with that in TACE+3DCRT group ( $p>0.05$ ). Puncture-induced hematoma, ectopic embolism, biliary fistula, radiation pneumonitis, gastrointestinal hemorrhage, needle track implantation and other severe complications did not emerge in both groups after operation. According to the postoperative reexamination, TACE+<sup>125</sup>I+3DCRT group had 2 cases (3.6%) of mild migration of seeds, without any discomfort in the patients. There was no statistically significant difference in the incidence rate of adverse reactions between the two groups of patients after chemoradiotherapy ( $p>0.05$ ) (Table 3).

#### Follow-up results of patient survival

All the patients were followed up for 7-36 months, with a median follow-up time of 24.3

months and 22.6 months, respectively, in the two groups. Each group had 2 patients lost by the end of follow-up. The median PFS was  $11.1\pm 1.9$  months in TACE+<sup>125</sup>I+3DCRT group and  $8.9\pm 1.2$  months in TACE+3DCRT group, and the median OS was  $22.9\pm 2.4$  months and  $17.6\pm 2.1$  months in TACE+<sup>125</sup>I+3DCRT group and TACE+3DCRT group, respectively. The Kaplan-Meier survival curves are shown in Figure 2. The log-rank test indicated that TACE+<sup>125</sup>I+3DCRT group exhibited distinctly longer OS and PFS than TACE+3DCRT group, displaying statistically significant differences ( $p=0.030$ ,  $p=0.016$ ).

#### Discussion

Since primary HCC is featured with insidious onset, only 20-30% of the patients meet the indications of surgical resection when diagnosed, and the portal vein is easily invaded, resulting in portal

hypertension, upper gastrointestinal hemorrhage, liver failure and even hepatic encephalopathy [8]. TACE has become the preferred interventional method for primary HCC that cannot be excised by surgery, and it has relatively ideal short-term efficacy, kills massive cancer cells, causes tumor necrosis, notably slows down the tumor growth, improves the quality of life and prolong the survival of the patients [9]. Nevertheless, TACE produces unfavorable therapeutic effects on HCC with poorly blood supply. With respect to the HCC with incomplete capsule or diffuse nodules, the efficacy of TACE is limited because the margins of the lesions are clearer as the lesions are supplied by the portal vein. In addition, the hypoxia induced by the treatment with TACE can upregulate angiogenic factors and stimulate residual tumor cells to proliferate continuously [10]. Some HCC lesions receive extrahepatic arterial blood supply and have abundant intrahepatic blood supply and many collateral circulations, so merely 20-50% of tumor tissues present complete necrosis after TACE is repeated several times, showing unsatisfactory long-term efficacy. The 1-year survival rate of the patients complicated with PVTT is only 14.5-20.4% after treatment with TACE alone [11,12].

HCC is a malignant tumor sensitive to radiation. Persistent radiotherapy can not only lead to DNA fragmentation and inhibit mitosis and proliferation of tumor cells but also prominently reduce the generation of tumor microvessels. Besides, radiotherapy is not affected by the blood supply of tumor [13,14]. Theoretically, therefore, TACE combined with radiotherapy is able to efficiently make up the deficiency of TACE in treating HCC with lack of blood supply and HCC with portal vein blood supply.

3DCRT is a kind of radiotherapy where the radiation field is consistent with the tumor shape at the 3D level on the basis of the CT image data, whose advantage is to reduce the radiation damage to surrounding tissues while increasing the radiation dose in the target area, thus enhancing the local therapeutic effect in a better way [15,16]. It has been reported that the effective rate is 44.4-69.7% at 4-6 weeks after TACE combined with 3DCRT, and the 1-year survival rate is 41.2-62.4% [17]. When HCC is treated using <sup>125</sup>I radioactive seed implantation, an emerging minimally invasive technique for tumor, the rays emitted can kill the tumor cells by producing oxygen free radicals and by destroying DNA in the nucleus and repressing mitosis at the same time [18,19]. Considering the short range of rays with radioactive sources and weak penetration ability of the technique, tumors can receive a high dose, while the surrounding normal tissues

are protected due to a low dose. Moreover, the radiation is performed at a persistent low dose, which is not compromised by respiratory movement and abdominal visceral migration. Studies have demonstrated that the combination therapy of TACE and <sup>125</sup>I seed implantation for HCC increases the complete tumor necrosis rate, effective rate, long-term survival rate and local control rate evidently, and its short-term and long-term efficacy is much better than that of TACE alone [20,21]. However, the treatment of HCC in the advanced stage with TACE and <sup>125</sup>I seed implantation combined with 3DCRT is rarely reported.

According to the results in this research, the ORR and DCR of the HCC patients in the advanced stage in TACE+<sup>125</sup>I+3DCRT group were obviously higher than those in TACE+3DCRT group ( $p=0.029$ ,  $p=0.043$ ). AFP, IGF-II and IGFBP-2 are important biomarkers that assist HCC diagnosis, prognosis judgment, efficacy assessment and relapse monitoring [22,23]. TACE+<sup>125</sup>I+3DCRT group had markedly lowered levels of serum AFP, IGF-II and IGFBP-2 in comparison with TACE+3DCRT group after treatment ( $p=0.008$ ,  $p=0.004$ ,  $p=0.018$ ). In terms of the adverse reactions observed, all of the patients finished the treatment, without severe adverse reactions. No significant increase in the incidence rate of adverse reactions was detected in TACE+<sup>125</sup>I+3DCRT group compared with that in TACE+3DCRT group ( $p>0.05$ ), suggesting that <sup>125</sup>I seed implantation does not increase the adverse reactions, and further illustrating that the combination of the three therapies is safe and feasible for the patients. It was shown in the follow-up results that the OS and PFS in TACE+<sup>125</sup>I+3DCRT group were distinctly longer than those in TACE+3DCRT group ( $p=0.030$ ,  $p=0.016$ ), implying that <sup>125</sup>I seed implantation based on TACE and 3DCRT can further kill the tumor cells, inhibit the tumor growth, decrease tumor metastasis or recurrence, extend the OS and PFS and improve the survival rate of the patients.

There are still multiple limitations in this research, such as small sample sizes, incomplete follow-up contents and no evaluation of impacts of different treatments on patient's quality of life. How to effectively prevent liver injury and how to determine the radiation volume, total radiation dose and fractionated dose according to factors such as the size of tumor and the grade of liver cirrhosis are problems to be solved urgently. Large-sample multicenter randomized controlled trials will be conducted in the future to testify the conclusion of this research, which is expected to provide more powerful evidence for the selection of treatment protocols for the patients.

## Conclusions

The treatment scheme of TACE and <sup>125</sup>I seed implantation combined with 3DCRT have the same efficacy in advanced primary HCC, which can distinctly increase the ORR and DCR, prominently reduce the levels of serum AFP, IGF-II and IGFBP-2 and prolong the survival of the patients with-

out increasing adverse reactions compared with TACE+3DCRT, so it is worthy of clinical popularization and application.

## Conflict of interests

The authors declare no conflict of interests.

## References

- Testino G, Leone S, Patussi V, Scafato E, Borro P. Hepatocellular carcinoma: diagnosis and proposal of treatment. *Minerva Med* 2016;107:413-26.
- Huang X, Li J, Wang F, Hao M. CT combined with tumor markers in the diagnosis and prognosis of hepatocellular carcinoma. *JBUON* 2018;23:985-91.
- Sieghart W, Huckle F, Peck-Radosavljevic M. Transarterial chemoembolization: modalities, indication, and patient selection. *J Hepatol* 2015;62:1187-195.
- Yu W, Wang Y, Liao G. Blood sugar level affects the recurrence of hepatocellular carcinoma after laparoscopic surgery: a retrospective study. *J BUON* 2018;23:622-8.
- Li S, He X, Dang L et al. Efficacy of (125)I Versus Non-(125)I Combined with Transcatheter Arterial Chemoembolization for the Treatment of Unresectable Hepatocellular Carcinoma with Obstructive Jaundice. *Dig Dis Sci* 2018;63:321-8.
- Zhang XB, Wang JH, Yan ZP, Qian S, Du SS, Zeng ZC. Hepatocellular carcinoma with main portal vein tumor thrombus: treatment with 3-dimensional conformal radiotherapy after portal vein stenting and transarterial chemoembolization. *Cancer* 2009;115:1245-52.
- Lu L, Zeng J, Wen Z, Tang C, Xu N. Transcatheter arterial chemoembolisation followed by three-dimensional conformal radiotherapy versus transcatheter arterial chemoembolisation alone for primary hepatocellular carcinoma in adults. *Cochrane Database Syst Rev* 2019;2:D12244.
- Clark T, Maximin S, Meier J, Pokharel S, Bhargava P. Hepatocellular Carcinoma: Review of Epidemiology, Screening, Imaging Diagnosis, Response Assessment, and Treatment. *Curr Probl Diagn Radiol* 2015;44:479-86.
- Kudo M, Arizumi T. Transarterial Chemoembolization in Combination with a Molecular Targeted Agent: Lessons Learned from Negative Trials (Post-TACE, BRISK-TA, SPACE, ORIENTAL, and TACE-2). *Oncology* 2017;93 (Suppl 1):127-34.
- Dong H, Xiao J, Zhu R et al. Serum sphingosine 1-phosphate in hepatocellular carcinoma patients is related to HBV infection. *JBUON* 2018;23:1711-6.
- Lee JM, Jang BK, Lee YJ et al. Survival outcomes of hepatic resection compared with transarterial chemoembolization or sorafenib for hepatocellular carcinoma with portal vein tumor thrombosis. *Clin Mol Hepatol* 2016;22:160-7.
- Huang M, Lin Q, Wang H et al. Survival benefit of chemoembolization plus Iodine-125 seed implantation in unresectable hepatitis B-related hepatocellular carcinoma with PVTT: a retrospective matched cohort study. *Eur Radiol* 2016;26:3428-36.
- Ohri N, Dawson LA, Krishnan S et al. Radiotherapy for Hepatocellular Carcinoma: New Indications and Directions for Future Study. *J Natl Cancer Inst* 2016;108.
- Yu Y, Feng M. Radiotherapy for Hepatocellular Carcinoma. *Semin Radiat Oncol* 2018;28:277-87.
- Cheng SH, Lin YM, Chuang VP et al. A pilot study of three-dimensional conformal radiotherapy in unresectable hepatocellular carcinoma. *J Gastroenterol Hepatol* 1999;14:1025-33.
- Okazaki E, Yamamoto A, Nishida N et al. Three-dimensional conformal radiotherapy for locally advanced hepatocellular carcinoma with portal vein tumour thrombosis: evaluating effectiveness of the model for end-stage liver disease (MELD) score compared with the Child-Pugh classification. *Br J Radiol* 2016;89:20150945.
- Lu DH, Fei ZL, Zhou JP, Hu ZT, Hao WS. A comparison between three-dimensional conformal radiotherapy combined with interventional treatment and interventional treatment alone for hepatocellular carcinoma with portal vein tumour thrombosis. *J Med Imaging Radiat Oncol* 2015;59:109-14.
- Qian J, Bao Z, Zou J, Yang H. Effect of pedicle fixation combined with (125)I seed implantation for metastatic thoracolumbar tumors. *J Pain Res* 2016;9:271-8.
- Li W, Zheng Y, Li Y et al. Effectiveness of (125)I seed implantation in the treatment of non-small cell lung cancer during R2 resection. *Oncol Lett* 2017;14:6690-700.
- Peng S, Yang QX, Zhang T et al. Lobaplatin-TACE combined with radioactive 125I seed implantation for treatment of primary hepatocellular carcinoma. *Asian Pac J Cancer Prev* 2014;15:5155-60.
- Yang M, Fang Z, Yan Z et al. Transarterial chemoembolization (TACE) combined with endovascular implantation of an iodine-125 seed strand for the treatment of hepatocellular carcinoma with portal vein tumour thrombosis versus TACE alone: a two-arm, randomised clinical trial. *J Cancer Res Clin Oncol* 2014;140:211-9.
- Ranke MB, Maier KP, Schweizer R et al. Pilot study of elevated levels of insulin-like growth factor-binding protein-2 as indicators of hepatocellular carcinoma. *Horm Res* 2003;60:174-80.
- Espelund U, Gronbaek H, Villadsen GE et al. The Circulating IGF System in Hepatocellular Carcinoma: The Impact of Liver Status and Treatment. *Growth Horm Igf Res* 2015;25:174-81.