JBUON 2020; 25(4): 1784-1791
ISSN: 1107-0625, online ISSN: 2241-6293 • www.jbuon.com
Email: editorial_office@jbuon.com

ORIGINAL ARTICLE

Value on the diagnosis of axillary lymph node metastasis in breast cancer by color Doppler ultrasound combined with computed tomography

Jianmin Zhou[1]*, Boxu Zhang[2]*, Yan Dong[3], Leilei Yu[4], Tiantian Gao[5], Zhenna Wang[6]

[1]Ultrasound Diagnosis Department, Yantaishan Hospital, Yantai 264000, China. [2]Department of Medical Imaging, no.970 Hospital of Chinese People's Liberation Army, Joint Logistic Support Force, Weihai 264200, China. [3]Breast Diagnosis and Treatment Center, Qingdao Central Hospital, Qingdao University 266042, China. [4]Endoscopic Room, the People's Hospital of Zhangqiu Area, Jinan 250200, China. [5]Urology Department, the People's Hospital of Zhangqiu Area, Jinan 250200, China. [6]Special Inspection Section, Qingdao Women and Children's Hospital, Qingdao 266000, China.

*Jianmin Zhou and Boxu Zhang contributed equally to this work.

Summary

Purpose: *To explore the clinical application value of color Doppler ultrasound combined with computed tomography (CT) in the diagnosis of axillary lymph node metastasis (ALNM) in breast cancer.*

Methods: *From January 2016 to June 2018, 189 breast cancer patients who underwent radical mastectomy in our hospital were included and retrospectively analyzed. All patients had preoperative color Doppler ultrasound and CT examination of mammary gland and axillary lymph nodes, with pathological diagnosis as the gold standard. Eighty-eight cases were divided into axillary lymph node metastasis group (metastatic group) and 101 cases formed the non-axillary lymph node metastasis group (non-metastatic group). The ultrasound and CT imaging of axillary lymph nodes were analyzed to evaluate the value of color Doppler ultrasound combined with CT in the assessment of axillary lymph node metastasis in breast cancer.*

Results: *Ultrasonographic metastatic lymph nodes showed unclear borders and eccentric thickening of the cortex. The enhancement scan showed obvious heterogeneous enhancement and disappearance of lymphatic structure. The sensitivity, accuracy, and negative predictive value of ultrasonography combined with CT were 92.05%, 90.48% and 92.78%, retrospectively, which were significantly improved compared with those in the individual tests (x^2=13.41, 6.126, 8.933, p=0.001, 0.047, 0.011), with significant statistical difference.*

Conclusions: *Color Doppler ultrasound combined with CT examination can significantly improve the detected rate of axillary lymph node metastasis in breast cancer before surgery, and provide a reliable basis for the treatment options on breast cancer patients before surgery.*

Key words: *breast cancer, axillary lymph node metastasis, ultrasound, CT, combined examination*

Introduction

Breast cancer is one of the common malignant tumors in women, which seriously threatens their health. In recent years, more attention has been paid over the fact that the age at onset has moved to the youngers and the incidence has increased year by year. The incidence and mortality of breast cancer are even higher than that of cervical cancer. Therefore, the prevention and treatment shall be a very important issue [1]. Easy metastasis and recurrence are the main causes of mortality. The earliest and most common metastatic pathway for breast cancer patients is axillary lymph node metastasis.

Corresponding author: Zhenna Wang, MD. Special Inspection Department, Qingdao Women's and Children's Hospital, 217 Liaoyang West Rd, Shibei District, Qingdao 266000, China.
Tel: +86 0532 68661155, Email:usskm0@163.com
Received: 07/04/2020; Accepted: 01/05/2020

It is an important indicator of breast cancer progression and an important indicator for axillary lymph node metastasis in the clinical staging of breast tumors [2]. In addition, the status of axillary lymph nodes plays an important role on the next clinical treatment plan (such as surgical method, surgical scope, postoperative adjuvant treatment, and psychological impact of patient and prognosis aspects) [3-5]. In the past, the gold standard for assessing the metastasis of axillary lymph node was based on the biopsy of axillary lymph node or pathological histological examination after surgical lymph node dissection. However, those methods often have certain side effects as invasive examinations, often leading to excessive checking for patients without axillary lymph node metastasis. It is very important to strengthen the non-invasive diagnosis of axillary lymph nodes metastasis before surgery and assess their status accurately, which can effectively avoid unnecessary surgical injury to patients, and also become the primary problem that clinicians need to consider in the diagnosis and treatment of breast cancer. A simple, fast and non-invasive examination method should be found to evaluate the axillary lymph node status of breast cancer, and provide reference for the next treatment to improve the accuracy of treatment.

In this study, we have retrospectively analyzed the ultrasound imaging combined with the CT imaging of axillary lymph nodes before operation for patients with breast cancer, and compared with their pathological results to evaluate the clinical value of the combined examination in the diagnosis of axillary lymph node metastases in breast cancer before surgery, providing basis for choosing a treatment plan of the breast cancer patients before operation.

Methods

Clinical materials

189 breast cancer patients who were first diagnosed and treated in our hospital from January 2016 to June 2018 formed the research cohort. All patients had undergone radical mastectomy with definite pathological diagnosis, and had complete color Doppler ultrasound combined with CT of axillary lymph nodes before surgery. Combined with pathological diagnosis as the gold standard, 88 cases formed the axillary lymph node metastasis group (metastasis group) and 101 cases formed the non-axillary lymph node metastasis group (non-metastasis group). All of them were female, 119 cases had unilateral tumor sites in the left breast and 70 cases in the right breast. Their ages ranged from 26 to 81 years (mean 52.36±12.54). Histopathological types: there were 112 (59.26%) cases of invasive ductal carcinoma, 50 (26.46%) cases of mixed invasive carcinoma, 14 (7.41%) cases of preinvasive carcinoma, 6 (2.17%) cases of invasive lobular carcinoma, and 7 (3.7%) cases of other types (tubular carcinoma, mucinous adenocarcinoma, etc.). Grade of tumor differentiation: there were 65 cases of high differentiation, 81 cases of moderate differentiation, and 43 cases of poor differentiation. Inclusion criteria were as follows: 1) All patients were pathologically diagnosed with breast cancer, without radiotherapy and chemotherapy before operation. 2) All color Doppler ultrasound combined with CT examination data were available before operation. 3) All patients signed the informed consent form. Exclusion criteria were as follows: 1) Breast cancer patients after treatment. 2) breast cancer without histopathological diagnosis. 3) patients combined with other malignant diseases.

Method

Color Doppler ultrasound was performed using PHILIPS iU22, with probe frequency 5-12 MHz. Detection method: the patients were placed in supine position, raise their arms, and place their hands behind the head, with full exposure of bilateral breasts and the areas of bilateral axillary and supraclavicular fossae. The breast lesions should be observed first, then the axillary and supraclavicular lymph nodes should be observed. Then color Doppler flow image (CDFI) was used to observe the morphology and distribution of blood flow signals in lymph nodes [6]. The criteria in ultrasound diagnostic of axillary lymph node metastasis (ALNM): there were unclear lymph node borders and eccentric thickening of the cortex, the ratio of cortex and medulla was larger than 1, with unclear boundary of cortex and medulla, internal microcalcifications and uneven internal echo, the aspect ratio was less than 2:1, the blood flow distribution was peripheral, the classification of blood flow signal was mainly level 3.

Enhanced CT examination: the CT equipment was SOMATOM Definition Flash. Examination method: patients were placed in supine position, with arms crossed and hands placed on the top of the head, the axillary plain scan and enhancement scan were conducted on the scan range from the lower border of the breast to the supraclavicular region, with layer thickness of 5 mm and inter-slice spacing of 5 mm. The non-ionic contrast agent was intravenously injected during enhancement scanning. The criteria in CT diagnosis of ALNM: the lymph was round or with irregular shape and fuzzy edge, with the diameter of short axis over 5 mm, the aspect ratio was less than 2:1, the enhancement scanning has been intensified, and the structure of lymphatics disappeared [7,8].

Statistics

The data obtained were processed by SPSS19.0 software. Count data were expressed as numbers and percents and x^2 test was used for comparison between groups. Four-table method was used to calculate color Doppler Ultrasound, CT and joint examination in the diagnosis of breast cancer ALNM.

Enumeration data was expressed as percents. Comparison in groups was performed by x^2 test. $P<0.05$ was considered statistically significant.

Results

Comparison on the two-dimensional ultrasonographic characteristics of axillary metastatic lymph nodes and non-metastatic lymph nodes in breast cancer

The two-dimensional ultrasonographic images of axillary metastatic lymph nodes in breast cancer showed unclear border of lymph nodes and eccentric thickening of cortex, thickness of cortex was larger than 3 mm, ratio of cortex and medulla was larger than 1, along with unclear boundary between cortex and medulla, internal microcalcifications and uneven internal echo. The aspect ratio was less than 2:1. The detection rate was signifi-

Table 1. Comparison of two-dimensional ultrasonographic characteristics of axillary metastatic lymph nodes and non-metastatic lymph nodes in breast cancer [n (%)]

Pathology	*Boundary of lymph node*		*Morphology of cortex*			*Thickness of cortex*		*Ratio of cortex and medulla*	
	Clear	*Unclear*	*Eccentric thickening*	*Concentric thickening*	*Stricture type*	*≤3mm*	*>3mm*	*≤1*	*>1*
Metastasis group (88)	27 (30.68)	61 (69.32)	54(61.36)	19(21.59)	15 (17.05)	28(31.82)	60 (68.18)	33 (37.50)	55 (62.50)
Non-metastasis group (101)	82 (81.19)	19 (18.81)	0	20(19.80)	81 (80.20)	79 (78.22)	22 (27.85)	57 (56.44)	44 (43.56)
x^2	49.141		98.975			41.219		6.760	
P	0.000		0.000			0.000		0.009	

Table 2. Comparison of two-dimensional ultrasonographic characteristics of axillary metastatic lymph nodes and non-metastatic lymph nodes in breast cancer [n (%)]

Pathology	*Boundary between cortex and medulla*		*Internal microcalcifications*		*Internal echo*		*Aspect ratio*	
	Clear	*Unclear*	*Yes*	*No*	*Even*	*Uneven*	*<2*	*≥2*
Metastasis group (88)	30 (34.09)	58 (65.91)	50 (56.82)	38 (43.18)	20 (22.73)	68 (77.27)	54 (61.36)	34 (38.64)
Non-metastasis group (101)	72 (71.29)	29 (28.71)	7 (6.93)	94 (93.07)	76 (75.25)	25 (24.75)	15 (14.85)	86 (85.15)
x^2	26.191		55.565		49.166		43.890	
P	0.000		0.000		0.000		0.000	

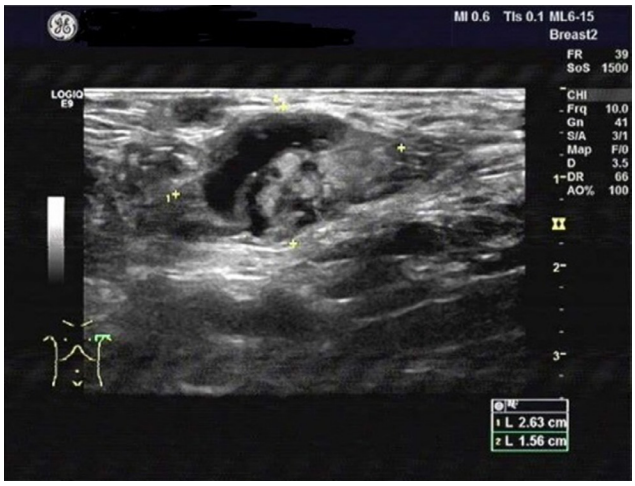

Figure 1. A two-dimensional ultrasonographic image of the right armpit showing a solid mass of approximately 2.6 cm x1.5 cm, with unclear edges and uneven internal echoes. The axillary metastatic lymph nodes of breast cancer were also considered.

Figure 2. Color Doppler flow image CDFI. The lymph nodes had rich blood flow and shown as peripheral distribution. The axillary metastatic lymph nodes of breast cancer were also considered.

cantly higher than that of non-metastasis group (p<0.001), with statistically significant difference as shown in Table 1 and Table 2. Two-dimensional ultrasonographic image is shown in Figure 1.

Comparison between color Doppler flow image CDFI of axillary metastatic lymph nodes and non-metastatic lymph nodes in breast cancer

The color Doppler flow image CDFI of axillary metastatic lymph nodes in breast cancer showed that there was peripheral blood flow distribution, and the classification of blood flow signal was mainly level 3 (75.00%). Most non-metastatic lymph nodes in the axilla showed blood flow distribution of lymphatic hilus, the classification of blood flow signal was mainly level 2 (74.26), and the difference between the two groups was statistically significant (p<0.01), as shown in Table 3. The color Doppler flow image CDFI was shown in Figure 2.

Comparison between CT imaging characteristics of axillary metastatic lymph nodes and non-metastatic lymph nodes in breast cancer

The enhanced CT images of axillary metastatic lymph nodes in breast cancer showed that the diameter of short-axis was larger than 5 mm, the structure of lymphatic hilus disappeared, and the aspect ratio was less than 2:1. With the intensification of enhancement scan, the detection rate was obviously increased compared with that of non-metastatic lymph node enhanced CT images, with statistically significant difference (p<0.01), as shown in Table 4. CT plain scan image is shown in Figure 3, and the image of CT enhancement scan is shown in Figure 4.

Comparison between diagnosis and pathological results of color Doppler ultrasound vs CT in axillary lymph nodes of breast cancer

Comparison between diagnosis and pathological results of color Doppler ultrasound *vs* CT in axillary lymph nodes of breast cancer is shown in Table 5. The value of color Doppler ultrasound, CT, and the combined examination in the diagnosis of axillary lymph node metastases in breast cancer were calculated in Table 5, as shown in Table 6. The sensitivity, accuracy, and negative predictive value of ultrasound combined with CT in the diagnosis of axillary lymph node metastases in breast cancer were 92.05%, 90.48%, and 92.78%, respectively, which were significantly improved compared with those in the individual tests (x^2=13.41, 6.126, 8.933, p=0.001, 0.047, 0.011), and the difference was statistically significant (p<0.05).

Table 3. Comparison on color Doplor flow image CDFI of axillary metastatic lymph nodes and non-metastatic lymph nodes in breast cancer [n (%)]

Pathology	*Distribution of blood flow*				*Classification of blood flow signal*		
	Mixed type n (%)	*peripheral type n (%)*	*lymphatic hilus type n (%)*	*Scattered type n (%)*	*Level 0-1 n (%)*	*Level 2 n (%)*	*Level 3 n (%)*
Metastasis group (88)	13 (14.77)	58 (65.91)	8 (9.09)	9 (10.23)	5 (5.68)	17 (19.32)	66 (75.00)
Non-metastasis group (101)	4 (3.96)	5 (4.95)	77 (76.24)	15 (14.85)	20 (19.80)	75 (74.26)	6 (5.94)
x^2	106.473				95.121		
P	0.000				0.000		

Table 4. Comparison of enhanced CT imaging features of axillary metastatic and non-metastatic lymph nodes in breast cancer [n (%)]

Pathology	*Diameter of short-axis*		*Structure of lymphatic hilus*		*Aspect ratio*		*Enhancement scan*	
	>5mm	*≤5mm*	*Disappeared*	*Completed*	*<2*	*≥2*	*Intensification*	*Non-intensification*
Metastasis group (88)	62 (70.45)	26 (29.55)	60 (68.18)	28 (31.82)	53 (60.23)	35 (39.77)	70 (79.55)	18 (20.45)
Non-metastasis group (101)	20 (19.80)	81 (80.20)	6 (5.94)	95 (94.06)	32 (31.68)	69 (68.32)	5 (4.95)	96 (95.05)
x^2	49.121		80.163		15.483		109.325	
P	0.000		0.000		0.000		0.000	

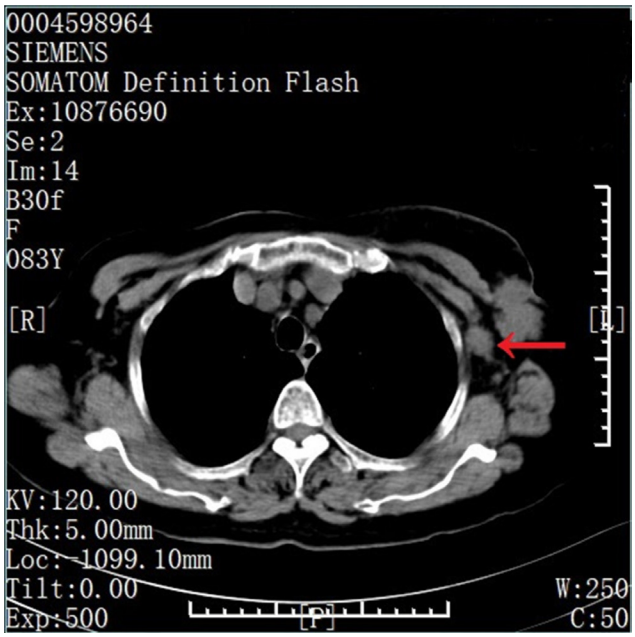

Figure 3. CT plain scan. The lymph node is round, with the increased volume and rough edges, shown with arrow.

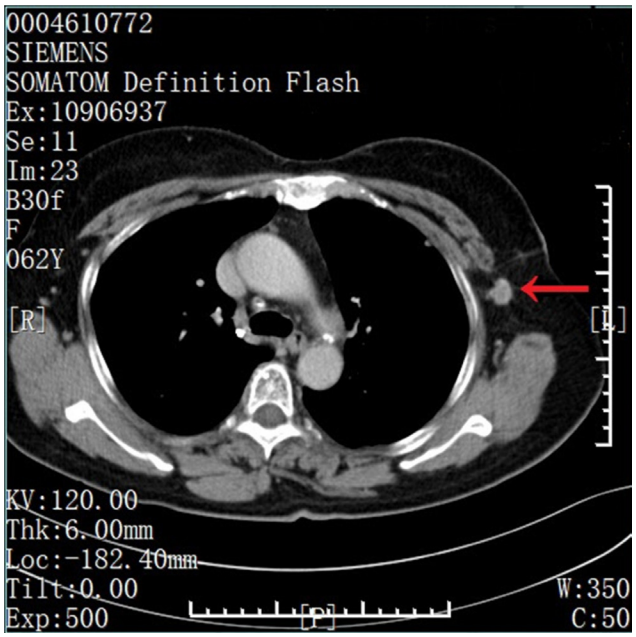

Figure 4. CT enhancement scan. The lymph node is shown as the mainly intensification of edge (arrow).

Table 5. Comparison on diagnosis and pathological results of color doppler ultrasound with CT in axillary lymph nodes of breast cancer (n)

Pathology	*Ultrasound*		*Total*	*CT*		*Total*
	Positive	*Negative*		*Positive*	*Negative*	
Positive	63	25	88	65	23	88
Negative	9	92	101	8	93	101
Total	72	117	189	73	116	189

Table 6. Comparison on the value among color Doppler ultrasound, CT and the combined examination in the diagnosis of axillary lymph node metastases in breast cancer

Indicator of examination	*Sensibility n (%)*	*Sensitivity n (%)*	*Accuracy n (%)*	*Positive predictive value n (%)*	*Negative predictive value n (%)*
Ultrasound	71.59 (63/88)	91.10 (92/101)	82.01 (155/189)	87.50 (63/72)	78.63 (92/117)
CT	73.86 (65/88)	92.08 (93/101)	83.60 (158/189)	89.04 (65/73)	80.17 (93/116)
Combined examination	92.05 (81/88)[a]	89.11 (90/101)	90.48 (171/189)[a]	88.04 (81/92)	92.78 (90/97)[a]
x^2	13.41	0.551	6.126	0.947	8.933
p	0.001	0.759	0.047	0.623	0.011

Compared with the single examination, [a]$p<0.05$.

Discussion

Axillary lymph node metastasis of breast cancer usually can be used as an important reference index for clinical staging, selection of surgical therapy, dissection scope of lymph node, and judgment on survival and prognosis of the patients [9,10]. In the past, ipsilateral axillary lymph node dissection or pathologic biopsy of sentinel lymph node were used for the determination of axillary lymph node metastasis in breast cancer. However, there are existing problems for excessive treatment. It has been confirmed that there was no metastasis in some patients by pathological examination after performing lymph node dissection, and some authors believe that the complete lymph node chain without metastasis could be helpful to block the spread of breast cancer cells, and lymph node dissection is a very traumatic surgery to patients. Furthermore, the lymph node dissection without metastasis

could not improve the survival rate of patients [11]. Although the pathologic biopsy of sentinel lymph node causes minor trauma, the false negative rate is about 5-10% [12,13]. At present, with the continuous development of imaging technology (ultrasound, CT, etc.), these non-invasive, convenient and economical examination methods have been well used in the assessment of the axillary lymph node status before breast cancer surgery [14], which can provide multiple parameters for the characterization of axillary lymph nodes to determine whether metastasis has occurred.

Color Doppler ultrasound has the advantages of simplicity, real time, non-invasion, well reproducibility, economy, no radiation and other aspects, and is used as the most commonly examination method for breast cancer diagnosis. The invasion of cancer cells often damage the capsule, cortex and medulla and often has unbalanced damage on the cortex and medulla in the metastatic lymph nodes of breast cancer, causing deformation and eccentricity in the center region of the medulla or nodule. The volume of lymph node increases and deforms as near circular, the vertical and horizontal diameter are reduced, the boundaries between the skin and the medulla are unclear, the lymphatic hilus disappears, the medulla shows uneven echo for damage cause by the cancer cells, and some small calcifications can occur [15,16]. After infiltrating the lymph nodes, the cancer cells are planted in the lymphatic sinuses of the lymph node cortex. While multiplication and necrosis continue in breast cancer cells, thickening cortex is created by the connective tissue reaction, and there is existing eccentricity and mutual fusion. Lee et al [17] had found that the thickening of the cortex and the disappeared hyperecho of lymphatic hilus were closely related to lymph node metastasis. Mainiero et al [18] had defined the maximum cortical thickness of 3 mm as the critical value of indicator for the determination of axillary lymph node metastasis, and they concluded that the sensitivity and specificity reached 85% and 75%, respectively. The results of this study showed that there were statistically significant differences in the characteristics of two-dimensional ultrasonographic imaging between lymph node metastases of breast cancer group and non-metastatic group. Most of the metastatic lymph nodes showed unclear borders, thickened cortex and uneven internal echo, the aspect ratio was less than 2:1, shown as internal microcalcifications, unclear demarcation of cortex and medulla, etc., which is consistent with the above report.

The new micro angiogenesis in axillary metastatic lymph nodes of breast cancer is induced by the large number of angiogenic factors synthesized by tumor cells [19]. The neoplastic tumor vessels penetrate from the lymph node subcapsular into the lymph node parenchyma, and due to the thickening of the metastatic lymph node cortex microvessels are enriched and disordered, forming a large number of venous sinuses, and the blood flow characteristics are peripheral distribution, while the cortical lymphatic sinus gradually progresses to the lymphatic hilus, causing compression of the blood vessels at the lymphatic portal, leading to a reduction of blood flow characteristics in the lymphatic hilus [20,21]. The blood flow characteristics of benign lymph nodes are mainly lymphatic hilus type, even though a small part of lymph nodes showed an increment of blood flow, which is much lower than that of metastatic lesions. The results of this study showed that the peripheral blood flow characteristics of metastatic lymph nodes accounted for 65.91%, and the blood flow signals were mainly level 3, accounting for 75.00%, which was statistically significant difference when compared with the non-metastatic lymph node group.

CT imaging not only can intuitively, accurately and in much detail evaluate axillary lymph nodes, supraclavicular lymph nodes, pectoralis major and minor interstitial lymph nodes, and posterior pectoralis minor lymph nodes, but also comprehensively evaluate whether patients with breast cancer have distant metastases and invasion of breast muscle, and it can guide the scope of axillary lymph node dissection during surgery for those with axillary lymph node metastasis, with the advantages which are not available in other examinations. In CT imaging of axillary lymph node, indicators such as morphology, size and degree of enhancement of lymph node, structure of lymphatic hilus, horizontal diameter ratio of lymph node, and cortical thickness were used to determine whether metastasis occurs [22]. The high resolution of CT imaging can clearly show the morphological characteristics of lymphatic vessels and lymph nodes, and CT value of axillary metastatic lymph nodes was significantly higher than that of non-metastatic lymph nodes after CT enhanced imaging, which can effectively distinguish the presence or absence of lymph node metastasis. Taking the aspect ratio of lymph nodes with 2:1 as the boundary, the aspect ratio of metastatic lymph nodes is less than 2 in the most parts, and the cortex is eccentric or irregular, while the benign enlarged node cortex is shown as concentric circles, which is used to further identify metastatic and non-metastatic lymph nodes [23]. Peiqi et al [24] has evaluated axillary lymph node metastasis by using CT imaging, showing that the sensitivity, specificity and accuracy were 93.0%, 57.6%

and 71.6%, respectively. The results of this study showed that combined with pathological diagnosis as the gold standard, the sensitivity, specificity and accuracy of CT diagnosis were 73.86%, 92.08% and 83.60%, respectively, which may be related to the relatively high diagnostic standards in our study, with the increased specificity, decreased sensitivity, and insufficient sensitivity in single examination.

In conclusion, the examination of axillary lymph nodes based on color Doppler ultrasound and CT imaging before breast cancer surgery can effectively assess whether axillary lymph nodes are metastatic, which has important guiding value for deciding the surgical treatment plans. However, the single examination has low sensitivity and low accuracy. The ultrasound examination is rather notable to detect some deeper and smaller lesions for the influence of the surrounding tissue structure, resulting in reduced sensitivity and missed diagnosis [25]. CT examination also has certain limitations, with unsatisfactory sensitivity. The results of this study showed that the sensitivity, accuracy and negative predictive value of the ultrasound combined with CT single examination on the diagnosis of axillary lymph node metastasis in breast cancer has significantly improved compared with that in the single examination, which are 92.05%, 90.48% and 92.78%, respectively, with statistically significant difference ($p<0.05$). The assessment of axillary lymph node status for breast cancer before surgery cannot be determined by the result of a single examination. The combined examination can be used in cross-validation and cross-complement, reducing the misdiagnosis and missed diagnosis, which has important reference value for guiding the clinical decision of treatment plans.

To sum up, color Doppler ultrasound combined with CT examination can significantly improve the detected coincidence rate of axillary lymph node metastasis in breast cancer before surgery, and provide a reliable basis for the treatment options on breast cancer patients before surgery.

Conflict of interests

The authors declare no conflict of interests.

References

1. Ramakrishna N, Temin S, Chandarlapaty S et al. Recommendations on disease management for patients with advanced human epidermal growth factor receptor 2-positive breast cancer and brain metastases: American Society of Clinical Oncology clinical practice guideline. J Clin Oncol 2014;32:2100-8.
2. He M, Zhang JX, Jiang YZ et al. The lymph node ratio as an independent prognostic factor for node-positive triple-negative breast cancer. Oncotarget 2017;8:44870-80.
3. Cuperjani F, Gashi L, Kurshumliu F, Dreshaj S, Selimi F. Relationship between Ribosomal Protein S6-pS240 Expression and other Prognostic Factors in Non-Special Type Invasive Breast Cancer. Breast Care (Basel) 2019;14:171-5.
4. Li L, Chen LZ. Factors influencing axillary lymph node metastasis in invasive breast cancer. Asian Pac J Cancer Prev 2012;13:251-4.
5. Filippakis GM, Zografos G. Contraindications of sentinel lymph node biopsy: are there any really? World J Surg Oncol 2007;5:10.
6. Na DG, Lim HK, Byun HS, Kim HD, Ko YH, Baek JH. Differential diagnosis of cervical lymphadenopathy: usefulness of color Doppler sonography. Am J Roentgenol 1997;168:1311-16.
7. Ogino I, Tayama Y, Arai M, Inoue T, Shimizu D, Ishikawa T. CT assessment of breast cancer for pathological involvement of four or more axillary nodes. Breast Cancer 2012;19:125-30.
8. Lowes S, Leaver A, Cox K, Satchithananda K, Cosgrove D, Lim A. Evolving imaging techniques for staging axillary lymph nodes in breast cancer. Clin Radiol 2018;73:396-409.
9. Krag DN, Anderson SJ, Julian TB et al. Sentinel lymph node resection compared with conventional axillary lymph node dissection in clinically node-negative patients with breast cancer: overall survival findings from the NSABP B-32 randomised phase 3 trial. Lancet Oncol 2010;11:927-33.
10. Hyun SJ, Kim EK, Moon HJ, Yoon JH, Kim MJ. Preoperative axillary lymph node evaluation in breast cancer patients by breast magnetic resonance imaging (MRI): Can breast MRI exclude advanced nodal disease? Eur Radiol 2016;26:3865-73.
11. Drukker K, Giger M, Meinel LA, Starkey A, Janardanan J, Abe H. Quantitative ultrasound image analysis of axillary lymph node status in breast cancer patients. Int J Comput Assist Radiol Surg 2013;8:895-903.
12. Kim T, Giuliano AE, Lyman GH. Lymphatic mapping and sentinel lymph node biopsy in early-stage breast carcinoma: a metaanalysis. Cancer 2006;106:4-16.
13. Barone JE, Tucker JB, Perez JM, Odom SR, Ghevariya V. Evidence-based medicine applied to sentinel lymph node biopsy in patients with breast cancer. Am Surg 2005;71:66-70.
14. França LKL, Bitencourt AGV, Paiva HLS. Role of magnetic resonance imaging in the planning of breast can-

cer treatment strategies: comparison with conventional imaging techniques. Radiol Bras 2017;50:76-81.

15. Assing MA, Patel BK, Karamsadkar N et al. A comparison of the diagnostic accuracy of magnetic resonance imaging to axillary ultrasound in the detection of axillary nodal metastases in newly diagnosed breast cancer. Breast J 2017;23:647-55.
16. Chen X, He Y, Wang J et al. Feasibility of using negative ultrasonography results of axillary lymph nodes to predict sentinel lymph node metastasis in breast cancer patients. Cancer Med 2018;7:3066-72.
17. Lee B, Lim AK, Krell J et al. The efficacy of axillary ultrasound in the detection of nodal metastasis in breast cancer. Am J Roentgenol 2013;200:W314-320.
18. Mainiero MB, Cinelli CM, Koelliker SL, Graves TA, Chung MA. Axillary ultrasound and fine-needle aspiration in the preoperative evaluation of the breast cancer patient: an algorithm based on tumor size and lymph node appearance. Am J Roentgenol 2010;195:1261-7.
19. Matsuzawa F, Einama T, Abe H et al. Accurate diagnosis of axillary lymph node metastasis using contrast-enhanced ultrasonography with Sonazoid. Mol Clin Oncol 2015;3:299-302.
20. Bedi DG, Krishnamurthy R, Krishnamurthy S et al. Cortical morphologic features of axillary lymph nodes as a predictor of metastasis in breastcancer: in vitro sonographic study. AJR Am J Roentgenol 2008;191:646-52.
21. Iannace C, Di Libero L, Lepore M et al. Prognostic and curative value of sentinel node in breast cancer: a 377 patients experience. Ann Ital Chir 2010;81:103-111; discussion 112-113.
22. Urata M, Kijima Y, Hirata M et al. Computed tomography Hounsfield units can predict breast cancer metastasis to axillary lymph nodes. BMC Cancer 2014;14:730.
23. Yuen S, Yamada K, Goto M, Sawai K, Nishimura T. CT-based evaluation of axillary sentinel lymph node status in breast cancer: value of added contrast-enhanced study. Acta Radiol 2004;45:730-37.
24. Wu PQ, Liu CL, Liu ZY, Ye WT, Liang CH. Value of mammography, CT and DCE-MRI in detecting axillary lymph node metastasis of breast cancer. Nan Fang Yi Ke Da Xue Xue Bao 2016;36:493-9.
25. Gipponi M, Fregatti P, Garlaschi A et al. Axillary ultrasound and Fine-Needle Aspiration Cytology in the preoperative staging of axillary node metastasis in breast cancer patients. Breast 2016;30:146-50.