

ORIGINAL ARTICLE

Efficacy of transumbilical laparoendoscopic single-site staging surgery in treating endometrial cancer

Yanyan Dou, Xiangmei Zheng

Department of Gynecology, People Hospital of Xingtai, Xingtai, China.

Summary

Purpose: To investigate the safety and feasibility of transumbilical laparoendoscopic single-site staging surgery in treating endometrial cancer.

Methods: The clinical data from 96 patients with endometrial cancer were retrospectively analyzed. The patients were assigned into two groups according to different surgical schemes, namely transumbilical laparoendoscopic single-site staging surgery and traditional laparoendoscopic staging surgery for endometrial cancer, with 48 patients in each group. The surgical indicators, incidence of postoperative complications, postoperative pain score, and postoperative cosmetic satisfaction were compared between the two groups, and the survival status and disease progression of patients were followed up and recorded.

Results: The laparoendoscopic single-site surgery (LESS) group exhibited a shorter operation time, a smaller amount of intraoperative blood loss, fewer lymph nodes dissected, shorter postoperative peritoneal drainage tube indwelling time, a smaller amount of postoperative peritoneal drainage,

and shorter postoperative ventilation time than the Control group. LESS group had significantly shorter postoperative hospital stay than the Control group. The postoperative cosmetic satisfaction score in LESS group was considerably higher than that in the Control group. LESS group had a markedly lower visual analog scale (VAS) score during walking at 24 h after operation than the Control group. The 3-year overall survival (OS) rate was 80.0% (52/65) in the LESS group and 84.6% (55/65) in the Control group, and the 3-year progression-free survival (PFS) rate was 66.2% (43/65) and 72.3% (47/65), respectively.

Conclusions: Transumbilical LESS is safe and feasible as the staging surgery for endometrial cancer and has advantages such as quick postoperative recovery, mild pain, good cosmetic outcomes, and short hospital stay, so it merits promotion.

Key words: transumbilical single-site surgery, endometrial cancer, staging surgery, efficacy

Introduction

Endometrial cancer, one of the most common gynecologic malignant tumors, has an increasing incidence rate, and its major procedure is comprehensive staging surgery [1]. The safety and effectiveness of surgery are the key factors affecting the prognosis and quality of life of patients with endometrial cancer. As medical technologies continue to develop and people have higher requirements for postoperative quality of life, laparoendoscopic surgery has become the first method for patients

with endometrial cancer for small surgical incision, clear field of view, a small amount of blood loss, short hospital stay, quick recovery, fewer postoperative complications, mild postoperative pain, and favorable cosmetic outcomes [2-5].

Laparoendoscopic single-site surgery (LESS) emerges with the constant pursuit of minimal invasiveness and cosmetics, unceasing exploration of novel technologies and the proposal of the idea of "scarless surgery" [6]. Transumbilical LESS tech-

nique hides the surgical incision at the umbilicus or around umbilicus by means of human natural scars, thereby leaving almost no scar on the body surface and even enabling further intraoperative umbilical cosmetics [7,8]. The clinical data of 96 patients with endometrial cancer were retrospectively analyzed in the present study, and the efficacy and safety were also compared between traditional laparoendoscopic surgery and transumbilical LESS in treating endometrial cancer.

Methods

Study subjects

A total of 96 patients with endometrial cancer were selected, and their age was 25-70 years old, with a median of 55.56 years. Endometrial cancer was confirmed histopathologically before operation in both groups of patients, and the size of the uterus was smaller than that at the 12th weeks of gestation. Exclusion criteria: 1) patients suspected of having multiple tumor metastasis, 2) those with a history of abdominopelvic surgery and pelvic endometriosis that might cause severe adhesion, 3) those with a history of umbilical hernia, 4) those with concomitant severe heart, lung, liver and renal dysfunctions, blood coagulation disorders, immune system disorders, or infectious diseases, 5) those complicated with other tumors, or 6) those with neurological abnormalities. According to different treatment methods, the patients were divided into two groups to receive transumbilical LESS of endometrial cancer as LESS group (n=48) and traditional laparoendoscopic staging surgery of endometrial cancer as Control group (n=48). The clinical baseline data such as age, sex and pathological types and stages of tumors in both groups are shown in Table 1, and they displayed no statistically significant differences ($p>0.05$). All the enrolled patients were informed

of this study according to the *Declaration of Helsinki*, and they signed the informed consent upon the review by the Ethics Committee of our hospital.

Treatment methods

In the LESS group, the single-port multi-channel device with a disposable incision protective film (Beijing Aerospace Company, Beijing, China) was used. There were 4 approaches, with the caliber ranging from 5 mm to 10 mm, and 2 approaches had a 5-mm caliber, while 2 approaches had a 10-mm caliber. A laparoscopic lens was inserted through one 10-mm approach. In the Control group, 3-4 disposable trocars, with the size of 5 mm and 10 mm (Hangzhou Kangji Medical Instrument Co., Ltd., Hangzhou, China) were employed.

After satisfactory general anesthesia, the patient was placed in the bladder lithotomy position, and transumbilical laparoendoscopic single-site staging surgery of endometrial cancer was then performed in the LESS group as follows: An about 1.5-3-cm-long incision was made at the umbilicus, and the single-port multi-channel tube was placed, into which CO₂ was insufflated to establish an artificial pneumoperitoneum at a set pressure of 11-13 mmHg. The laparoscope was used to explore the pelvic and abdominal cavities, including the gastrointestinal tract, omentum, liver, diaphragm, and peritoneal surface, examine the uterus and both appendages, and verify whether there is pelvic metastasis or distant metastasis. Moreover, the ascitic specimen or peritoneal irrigation fluid was retained and sent for cytologic examination. Bilateral fallopian tubes were ligated through bipolar coagulation, and the uterus and both appendages were completely removed. The uterus was profiled to show the size and invasion depth of the lesion, and it was quickly sent for frozen-section pathologic examination. Besides, abdominopelvic lymph node dissection was carried out. After operation, a peritoneal drainage tube was conventionally placed, and it could be withdrawn when the postoperative drainage amount was less than 50 mL.

Table 1. Baseline characteristics of the studied patients

Parameters	LESS group (n=48)	Control group (n=48)	p value
Age (years)	56.06±8.44	54.75±8.73	0.457
BMI (kg/m ²)	23.8±3.6	24.3±3.4	0.456
Pathological type, n (%)			0.741
Endometrioid adenocarcinoma	45 (93.8)	46 (95.8)	
Clear cell carcinoma	2 (4.2)	1 (2.1)	
Undifferentiated carcinoma	1 (2.1)	1 (2.1)	
FIGO stage, n (%)			0.616
Ia	15 (31.3)	19 (39.6)	
Ib	23 (47.9)	21 (43.8)	
II	20 (41.7)	18 (37.5)	
Differentiation degree, n (%)			0.583
Low	5 (10.4)	7 (14.6)	
Moderate	12 (25.0)	14 (29.2)	
High	31 (64.6)	27 (56.3)	

LESS: laparoendoscopic single-site surgery; FIGO: International Federation of Gynecology and Obstetrics; BMI: body mass index.

Traditional laparoendoscopic staging surgery of endometrial cancer was performed in the Control group. Specifically, a 10-mm-long incision was made at the umbilicus, and punctured using a trocar, from which a laparoscope was inserted. After that, the trocars were inserted through the puncture points at the right McBurney's point, the left McBurney's point, and 1/3 of the upper middle connection line between the umbilicus and the left anterior superior iliac spine, which were 5 mm, 5 mm and 10 mm in caliber. The remaining procedures were the same as those in the LESS group.

Observation indicators

The operation time (from the first cut through the skin to the ending of skin suture), intraoperative blood loss (calculated based on the total amount in the negative-pressure aspiration bag minus the sum of abdominal irrigation fluid, peritoneal effusion and anti-adhesion agent), drainage tube indwelling time, peritoneal drainage amount (calculated based on the accumulative amount in the peritoneal drainage bag), number of pelvic lymph nodes dissected, hospital stay, postoperative ventilation time and other surgical indicators were recorded for the two groups of patients. The incidence rates of the incision infections (poor incision healing and incision infection within 1 month after operation), postoperative abdominal distention, lower extremity venous thrombosis, postoperative incision hernia and other complications were measured in both groups.

The visual analogue scale (VAS) score was recorded at 24 h after operation for the two groups of patients, and according to the international standard VAS, the degree of pain was scored 0-10 points, where 0 indicated painless (0 points), while 10 the most painful (10 points). After operation, the patients selected one point to show the degree of pain. The postoperative cosmetic outcome score was compared between the two groups: At 3 months after operation, follow-up was conducted via telephone for patients' satisfaction with postopera-

tive abdominal wall wound cosmetics, as follows: 1 point for very dissatisfied, 2 points for dissatisfaction, 3 points for neutral, 4 points for satisfied, and 5 points for very satisfied.

The survival status of patients was followed up and recorded. Overall survival (OS) was defined as the duration from the start of treatment to the death of patients or the last follow-up, while progression-free survival (PFS) referred to the time from the start of treatment to the progression of disease, or recurrences or metastasis. The deadline of the follow-up was May 2020.

Statistics

SPSS 22.0 software (IBM, Armonk, NY, USA) was used for statistical analyses. Measurement data were expressed as mean \pm standard deviation ($\bar{x}\pm s$) and intergroup comparisons were made using two-sample t-test. Enumeration data were presented as percentage (%), and χ^2 test was performed for intergroup comparisons. The survival curves were plotted using the Kaplan-Meier method. Survival analysis was conducted using the log-rank test. $P < 0.05$ suggested statistically significant difference.

Results

Comparison of surgical indicators between the two groups of patients

The LESS group exhibited shorter operation time, a smaller amount of intraoperative blood loss, fewer lymph nodes dissected, shorter postoperative peritoneal drainage tube indwelling time, a smaller amount of postoperative peritoneal drainage, and shorter postoperative ventilation time than the Control group [(156.61 \pm 46.43) min vs. (143.38 \pm 49.84) min, (109.39 \pm 74.54) mL vs. (131.40 \pm 88.17) mL, (8.14 \pm 2.51) vs. (8.58 \pm 2.30),

Table 2. Comparison of surgical indicators and postoperative recovery parameters of the studied patients in two different groups

Parameters	LESS group (n=48)	Control group (n=48)	p value
Operation time (min)	156.61 \pm 46.43	143.38 \pm 49.84	0.182
Blood loss (ml)	109.39 \pm 74.54	131.40 \pm 88.17	0.190
Number of lymph nodes dissection	8.14 \pm 2.51	8.58 \pm 2.30	0.373
Peritoneal drainage tube indwelling time (d)	3.56 \pm 0.89	3.86 \pm 0.93	0.110
Peritoneal drainage volume (ml)	321.55 \pm 220.62	360.47 \pm 187.53	0.354
Postoperative ventilation time (d)	1.89 \pm 0.78	1.97 \pm 0.71	0.601
Postoperative hospital stay (d)	9.67 \pm 1.92	10.69 \pm 2.02	0.013
Complications			
Incision infection	2 (4.2%)	4 (8.3%)	0.399
Poor wound healing	2 (4.2%)	3 (6.3%)	0.646
Incisional hernia	0 (0%)	0 (0%)	1.000
Postoperative abdominal distention	2 (4.2%)	5 (10.4%)	0.239
Lower limb vein thrombosis	1 (2.1%)	3 (6.3%)	0.307

LESS: laparoendoscopic single-site surgery.

(3.56±0.89) d vs. (3.86±0.93) d, (321.55±220.62) mL vs. (360.47±187.53) mL, and (1.89±0.78) d vs. (1.97±0.71) d], showing no statistically significant differences ($p>0.05$). The LESS group had significantly shorter postoperative hospital stay than the Control group [(9.67±1.92) d vs. (10.69±2.02) d] ($p=0.013$). The patients in both groups mainly had complications such as incision infection, poor incision healing, postoperative abdominal distension, and lower extremity venous thrombosis, but no incision hernia, bladder dysfunction and organ injury. The incidence rate of incision infections was 4.2% (2/48) and 8.3% (4/48), that of poor incision healing was 4.2% (2/48) and 6.3% (3/48), that of postoperative abdominal distension was 4.2% (2/48) and 10.4% (5/48), and that of lower extremity venous thrombosis was 2.1% (1/48) and 6.3% (3/48), respectively, in the LESS group and the Control group ($p>0.05$) (Table 2).

Comparison of postoperative cosmetic satisfaction between the two groups of patients

A 1.5-3-cm-long incision at the natural umbilical depression was used as the approach of transumbilical LESS, and the incision was intradermally sutured using absorbable sutures after operation. The umbilical skin folds could conceal the incision to the largest extent, making the surgical incision quite beautiful. At 3 months after operation, the appearance of the umbilicus could basically recover to the preoperative state. The LESS group and the

Control group had 45 (93.8%) and 11 (22.9%) cases of being very satisfied with postoperative cosmetic outcomes, 1 (2.1%) and 34 (70.8%) cases of being satisfied with postoperative cosmetic outcomes, 1 (2.1%) and 1 (2.1%) cases of being neutral about postoperative cosmetic outcomes, and 1 (2.1%) and 1 (2.1%) case of being dissatisfied with postoperative cosmetic outcomes, respectively, showing statistically significant differences in the degree of satisfaction ($p<0.001$). The postoperative cosmetic satisfaction score in the LESS group was considerably higher than that in the Control group [(4.91±0.65) points vs. (4.14±0.73) points] ($p<0.001$) (Table 3).

Comparison of VAS score at 24 h after operation between the two groups of patients

The VAS score at 24h after operation was 0.09±0.28 points and 0.11±0.33 points in the lying position, 0.15±0.36 points and 0.27±0.56 points in the sitting position, and 0.71±0.57 points and 0.78±0.69 points in the standing position, respectively, in the LESS group and the Control group, with no statistically significant differences ($p=0.649$, $p=0.215$, $p=0.489$). The LESS group had a remarkably lower VAS score during walking at 24 h after operation than the Control group [(1.13±0.59) points vs. (1.34±0.63) points] ($p=0.045$) (Table 4).

Patient survival based on follow-up results

All patients were followed up for 6-36 months until May 2020, and the median follow-up time

Table 3. Comparison of postoperative cosmetic effect of the studied patients in the two groups

	LESS group (n=48)	Control group (n=48)	p value
Cosmetic effect, n (%)			0.001
Great satisfaction	45 (93.8)	11 (22.9)	
Satisfaction	1 (2.1)	34 (70.8)	
Good	1 (2.1)	1 (2.1)	
Dissatisfaction	1 (2.1)	1 (2.1)	
Great dissatisfaction	0 (0)	1 (2.1)	
Cosmetic satisfaction score	4.91±0.65	4.14±0.73	0.001

LESS: laparoendoscopic single-site surgery.

Table 4. Comparison of 24-h postoperative VAS score of the studied patients in two groups

	LESS group n=48	Control group n=48	p value
VAS score			
Lying position	0.09±0.28	0.11±0.33	0.649
Sitting position	0.15±0.36	0.27±0.56	0.215
Standing position	0.71±0.57	0.78±0.69	0.489
Walking	1.13±0.59	1.34±0.63	0.045

LESS: laparoendoscopic single-site surgery.

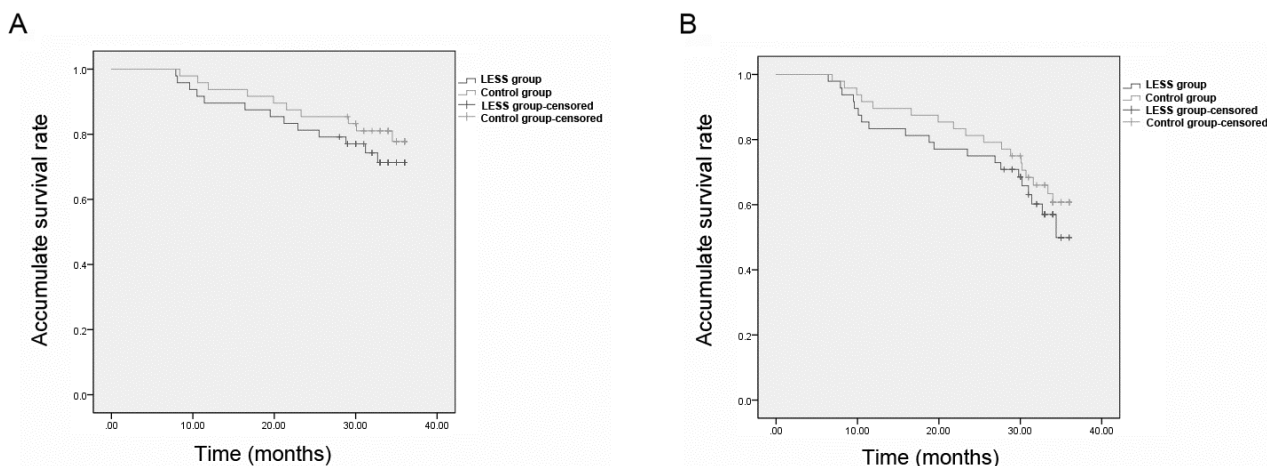


Figure 1. Kaplan-Meier survival curves of patients in LESS group and Control group. The difference between overall survival rate **(A)** and progression free survival rate **(B)** of patients in LESS group and Control group had no statistical significance ($p=0.381$, $p=0.406$).

was 29.6 months. The LESS group and the Control group had 1-year OS rates of 92.3% (60/65) and 95.4% (62/65), 2-year OS rates of 86.2% (56/65) and 89.2% (58/65), 3-year OS rates of 80.0% (52/65) and 84.6% (55/65), 1-year PFS rates of 87.7% (57/65) and 92.3% (60/65), 2-year PFS rates of 78.5% (51/65) and 86.2% (56/65), and 3-year PFS rates of 66.2% (43/65) and 72.3% (47/65), respectively. The survival curves of patients were plotted using the Kaplan-Meier method (Figure 1). The log-rank test results showed that the differences in the OS and PFS rates between the two groups were not statistically significant ($p=0.381$, $p=0.406$).

Discussion

The preferred treatment for endometrial cancer is total uterus and bilateral appendage resection, and whether extensive hysterectomy and dissection of pelvic and para-aortic lymph nodes are conducted depends on the surgical pathological stage [9]. As medical technologies continue to develop, and people have higher requirements for postoperative quality of life, laparoendoscopic surgery has become the first method for patients with endometrial cancer for small surgical incision, clear field of view, a small amount of blood loss, short hospital stay, quick recovery, fewer postoperative complications, mild postoperative pain, and favorable cosmetic outcome [10]. In recent years, LESS is gradually applied for the advantage of better cosmetic outcomes, and its application in the staging surgery for endometrial cancer plays an important role in the laparoendoscopic surgery for gynecologic tumors [11].

A comparison between LESS and traditional laparoendoscopic surgery in treating the early-

stage endometrial cancer was reported in an article in 2014. A total of 37 patients with endometrial cancer who were subjected to comprehensive staging surgery *via* LESS and 74 cases of traditional multi-site laparoendoscopic surgery were enrolled, and the operation time, intraoperative blood loss, intra- and post-operative complications, and duration of postoperative hospital stay, postoperative pain score, and scar satisfaction score were compared. It was concluded that LESS had comparable perioperative outcomes to traditional laparoendoscopic surgery, and reduced patients' postoperative pain and demand for analgesia and increased their cosmetic satisfaction [12]. Compared with traditional laparoendoscopic surgery, LESS needs fewer incisions, which is a fundamental advantage, thereby improving patients' cosmetic satisfaction [13]. Traditional laparoendoscopic surgery was performed through 3-4 1-2-cm-long incisions, and this surgical procedure has gradually become mature. LESS allows for the hiding of surgical incision at or around the umbilicus by means of the innate scars of humans, and only one 1.5-3-cm-long incision was made to place a multi-channel cannula, almost without leaving scars [14]. A recent study demonstrated that the pursuit for cosmesis and the recognition of LESS do not vary among different ages, and cosmesis is available not only for young women. Therefore, LESS should be also recommended for mid-aged women [15]. Besides, LESS has other advantages over traditional laparoendoscopic surgery, such as quick postoperative recovery, mild postoperative pain, and is less expensive [16]. According to the results of this research, there were no statistically significant differences in operation time, intraoperative blood loss, dissection of lymph nodes, postoperative peritoneal

drainage tube indwelling and postoperative bowel ventilation between the LESS and Control group ($p>0.05$). The mean hospital stay in the LESS group was significantly shorter than that in the Control group ($p=0.013$). The postoperative cosmetic satisfaction score in the LESS group was considerably higher than that in the Control group ($p<0.001$). The LESS group had a markedly lower VAS score during walking at 24 h after operation than the Control group ($p=0.045$).

Chambers et al [17] performed a retrospective study including 1,150 cases in 3 hospitals in 2019, so as to analyze the differences in PFS and OS among patients who received multi-site laparoendoscopic surgery, LESS and robot-assisted laparoendoscopic surgery as the staging surgery for endometrial cancer. After 31-33 months of postoperative follow-up, it was found that there is no marked difference among patients who separately received 3 different operations, verifying that the LESS is feasible for treating the early-stage endometrial cancer [17]. In the present study, the differences in OS and PFS rates were not statistically different between the two groups ($p=0.381$, $p=0.406$).

LESS has its potential merits in treating malignant tumors. First, the incision protector at the single-site approach platform prevents the trocar from bringing out tumor deposits when going in and out of the abdominal wall during operation. Moreover, if a larger tumor is taken out using a 10-mm trocar, the tumor will be cut up, and once the specimen bag has a crevasse, severe tumor dissemination will be caused. However, the incision for LESS (generally 2-3 mm long) can make it easier to remove the tumor. Then when a larger tumor is removed, the peritoneum and the anterior rectus sheath below the 10-mm incision are prone to damage, causing loose suture. If the patient is

obese, suture is more difficult. A previous paper showed that the LESS technique represents a novel approach for malignant tumor patients with body mass index ≥ 30 kg/m² [18,19]. Therefore, incision hernia is likely to occur when a large tumor is removed from a patient with obesity or emaciation, while a relatively large incision for the LESS can allow for the complete closing of the peritoneum and the anterior rectus sheath under direct view, thereby reducing the incidence incision hernia. A study also confirmed that the LESS does not increase the incidence of incision hernia [20]. The incision complications, such as injury to blood vessels and intestines below the incision, have low incidence rates, but they can cause severe consequences that can be avoided in the LESS since laparotomy can be conducted under direct view.

This retrospective study has certain limitations, including the limited number of patients enrolled, not unique chemotherapy regimen, failure to enroll the patients who had no response to neoadjuvant chemotherapy and experienced disease progression, and not comprehensive follow-up content. Multi-center large-scale prospective randomized studies need to be designed more rigorously in the future to verify the conclusion of the present study.

Conclusions

Transumbilical LESS is safe and feasible as the staging surgery for endometrial cancer and has advantages such as quick postoperative recovery, mild pain, good cosmetic outcomes, and short hospital stay, so it merits promotion.

Conflict of interests

The authors declare no conflict of interests.

References

- Braun MM, Overbeek-Wager EA, Grumbo RJ. Diagnosis and Management of Endometrial Cancer. *Am Fam Physician* 2016;93:468-74.
- Zhou L, Guo F, Li D, Qi J, Chan L, Yuan Y. Short- and long-term outcomes of laparoscopic surgery for elderly patients with clinical stage I endometrial cancer. *JBUON* 2020;25:764-71.
- Zouari M, Ben DM, Ammar S, Jallouli M, Mhiri R. Laparoendoscopic Single-Site (LESS) Surgery in Pediatric Urology: A 4-Year Experience. *Curr Urol* 2019;12: 153-7.
- Li M, Men X, Zhang X. Diagnostic value of carbohydrate antigen 72-4 combined with carbohydrate antigen 15.3 in ovarian cancer, cervical cancer and endometrial cancer. *JBUON* 2020;25:1918-27.
- Escobar PF, Starks DC, Fader AN, Barber M, Rojas-Espalliat L. Single-port risk-reducing salpingo-oophorectomy with and without hysterectomy: surgical outcomes and learning curve analysis. *Gynecol Oncol* 2010;119:43-7.
- Boruta DM. Laparoendoscopic single-site surgery in gynecologic oncology: An update. *Gynecol Oncol* 2016;141:616-23.
- Chen S, Qi X, Chen L et al. Laparoendoscopic Single-site Surgery for Comprehensive Staging of Early Ovarian Cancer. *J Minim Invasive Gynecol* 2019;26:806.

8. Fader AN, Cohen S, Escobar PF, Gunderson C. Laparoendoscopic single-site surgery in gynecology. *Curr Opin Obstet Gynecol* 2010;22:331-8.
9. Cai HH, Liu MB, He YL. Treatment of Early Stage Endometrial Cancer by Transumbilical Laparoendoscopic Single-Site Surgery Versus Traditional Laparoscopic Surgery: A Comparison Study. *Medicine (Baltimore)* 2016;95:e3211.
10. Moukarzel LA, Fader AN, Tanner EJ. Feasibility of Robotic-Assisted Laparoendoscopic Single-Site Surgery in the Gynecologic Oncology Setting. *J Minim Invasive Gynecol* 2017;24:258-63.
11. Fader AN, Escobar PF. Laparoendoscopic single-site surgery (LESS) in gynecologic oncology: technique and initial report. *Gynecol Oncol* 2009;114:157-61.
12. Park JY, Kim DY, Suh DS, Kim JH, Nam JH. Laparoendoscopic single-site versus conventional laparoscopic surgical staging for early-stage endometrial cancer. *Int J Gynecol Cancer* 2014;24:358-63.
13. Bogliolo S, Cassani C, Musacchi V, Babilonti L, Gardella B, Spinillo A. Robotic single-site surgery in management of obese patients with early-stage endometrial cancer. *J Minim Invasive Gynecol* 2015;22:697-9.
14. Moon HS, Shim JE, Lee SR, Jeong K. The Comparison of Robotic Single-Site Surgery to Single-Port Laparoendoscopic Surgery for the Treatment of Advanced-Stage Endometriosis. *J Laparoendosc Adv Surg Tech A* 2018;28:1483-8.
15. Moukarzel LA, Sinno AK, Fader AN, Tanner EJ. Comparing Single-Site and Multiport Robotic Hysterectomy with Sentinel Lymph Node Mapping for Endometrial Cancer: Surgical Outcomes and Cost Analysis. *J Minim Invasive Gynecol* 2017;24:977-83.
16. Bradford LS, Boruta DM. Laparoendoscopic single-site surgery in gynecology: a review of the literature, tools, and techniques. *Obstet Gynecol Surv* 2013;68:295-304.
17. Chambers LM, Carr C, Freeman L, Jernigan AM, Michener CM. Does surgical platform impact recurrence and survival? A study of utilization of multiport, single-port, and robotic-assisted laparoscopy in endometrial cancer surgery. *Am J Obstet Gynecol* 2019;221:241-5.
18. Lee CL, Wu KY, Su H, Ueng SH, Yen CF. Transvaginal natural-orifice transluminal endoscopic surgery (NOTES) in adnexal procedures. *J Minim Invasive Gynecol* 2012;19:509-13.
19. Mat E, Kale A, Gundogdu EC, Basol G, Yildiz G, Usta T. Transvaginal natural orifice endoscopic surgery for extremely obese patients with early-stage endometrial cancer. *J Obstet Gynaecol Res* 2021;47:262-9.
20. Abdel-Karim AM, Elhenawy IM, Eid AA, Yahia E, El-salmy SA. Laparoendoscopic single-site surgery for the treatment of different urological pathologies: Defining the learning curve of an experienced laparoscopist. *Arab J Urol* 2017;15:187-93.