

ORIGINAL ARTICLE

PD-L1 protein expression patterns in renal cell carcinoma based on conventional and digitized evaluation

Paraskevi Tziakou^{1*}, Grigorios Theodoropoulos^{2*}, Evangelos Tsiambas^{3,4*}, Gerasimos Kollaitis², Eirini Thymara⁴, Nikolaos Kavantzias⁴, Andreas C. Lazaris⁴

¹Department of Pathology, "Thriasio" General Hospital of Elefsina, Elefsina, Greece. ²Department of Urology, Athens General Hospital "Elpis", Athens, Greece. ³Department of Cytology, 417 VA (NIMTS), Athens, Greece. ⁴Department of Pathology, Medical School, National and Kapodistrian University of Athens, Athens, Greece.

*Authors equally contributed

Summary

Purpose: Programmed cell death ligand-1 (PD-L1), also known as CD274 (cytogenetic band: 9p24.1), is expressed predominantly in most hematopoietic cells and also in epithelial cells. Our aim was to evaluate PD-L1 protein expression in renal cell carcinoma (RCC) tissues by comparatively implementing conventional and also digitized assays.

Methods: We used 100 archival, for-malin-fixed and paraffin-embedded RCC tissue specimens, including 75 histologically confirmed clear cell RCC, 13 papillary RCCs, and 12 chromophobe RCC. Immunohistochemistry was performed implementing an anti- PD-L1 antibody. Conventional (Tumor Proportion Score (TPS)-qualitative) and also digital image analysis (DIA-quantitative) assays were applied for evaluating the corresponding protein expression levels.

Results: According to DIA, negative or loss of PD-L1 expres-

sion was observed in 92 cases (92%), in 2 (2%) of them moderate levels were detected, whereas 6 (6%) were characterized by strong (high) expression. Based on the TPS evaluation, 8 (8%) cases were characterized as positive, whereas the rest of them (92/92%) as negative. Interestingly, kappa analysis revealed a high level of overall correlation between qualitative and quantitative based assays (kappa=0.94).

Conclusions: PD-L1 overexpression is detected in low rates in RCC, especially in the clear cell carcinoma histological variety. Implementation of digitized (staining intensity) analytical methods provides an objective and accurate approach matching with the conventional protein expression evaluation and categorization as positive/negative cases.

Key words: renal carcinoma, PD-L1, protein, image analysis, immunotherapy

Introduction

In modern oncology, novel and sophisticated therapeutic strategies have been developed and adopted since last decade. Besides targeted therapies, which include monoclonal antibodies (mABs) and tyrosine-kinase inhibitors (TKIs) for disrupting signaling transduction pathways, immune checkpoint inhibitors that regulate immunomodulation by targeting specific pathways are considered very promising agents [1]. Programmed cell death-1 (PD-1) gene - located on chromosome 2 (gene locus:

2q37.3) - encodes a cell surface membrane protein of the immunoglobulin super-family. It acts as an immunoinhibitory receptor of the CD28 family, involved in tumor immune escape process [2]. PD-1 is expressed in pro-B-cells involved in their differentiation, whereas its role in apoptotic death process is under consideration. Concerning its downstream pathway, PD-1 interacts with two potential ligands, PD-L1 and PD-L2 trans-membrane proteins implicated in different levels of expression in specific

Corresponding author: Evangelos Tsiambas, MD, MSc, PhD. 17 Patriarchou Grigoriou E' Street, Ag. Paraskevi, 153 41 Athens, Greece.

Email: tsiambasecyto@yahoo.gr

Received: 23/12/2020; Accepted: 01/02/2021

functions regulation [3]. Programmed cell death ligand-1 (PD-L1), also known as CD274 (cytogenetic band: 9p24.1), is expressed predominantly in most hematopoietic cells and also in epithelial cells, including pancreatic islet cells and vascular endothelial cells. Additionally, PD-L1 is expressed on the thymic cortex, on thymocytes and in the thymic medulla. Also, dendritic cells express PD-L1 reducing the initial phase of activation and expansion of self-reactive T cells. Concerning PD-L2, also known as CD273, its expression is restricted to macrophages and dendritic cells. The PD-1/PD-L1 pathway delivers inhibitory signals that regulate both peripheral and central tolerance [4]. Its main role is the inhibition of T lymphocyte proliferation, survival and other functions (cytotoxicity, cytokine release). Furthermore, it causes apoptosis of tumor-specific T cells and also differentiation of CD4⁺ T, inducing resistance of tumor cells to cytotoxic T lymphocyte (CTL) lineage attack. Aberrant overexpression of PD-L1 enhances the inflammatory process and also allows cancers to evade the host immune system by suppressing T cell activation and inducing peripheral tolerance [5].

Renal cell carcinoma (RCC) comprises a variety of pathological entities that arise from the corresponding epithelia. Clear cell RCC covers a 60-70% of all RCCs, whereas papillary and chromophobe histopathologic sub-types are referred to the rest of them [6]. Concerning their aggressive or not biological behavior (increased localized and distant metastatic potential), some critical molecules have been found to be involved in the disorganization of the malignant epithelial mass [7]. In the current study, we focused on PD-L1 protein expression patterns in RCC comparing conventional and digital based analysis regarding its evaluation.

Methods

Study group

For the purposes of our study, we used 100 archival, formalin-fixed and paraffin-embedded (FFPE) RCC tissue specimens, including 75 histologically confirmed clear cell RCC, 13 papillary RCCs, and 12 chromophobe RCCs, respectively. Among patients, 63 were male, whereas the rest of them (n=37) female. The hospital ethics committee consented to the use of these tissues in the Department of Pathology, "Elpis" General Hospital, Athens, Greece for research purposes, according to World Medical Association Declaration of Helsinki. The tissue samples were fixed in neutral-buffered formalin. Hematoxylin and eosin (H&E)-stained slides of the corresponding samples were reviewed for confirmation of histopathologic diagnoses. All lesions were classified according to the histologic typing criteria of World Health Organization (WHO) [8].

Antibodies and immunohistochemistry assay (IHC)

Ready-to-use anti-PD-L1 (clone 223C3 Dako, North America Inc, CA, USA) monoclonal mouse antibody was applied in the corresponding RCC tissue sections. IHC for the selected antigen was carried out on 3 µm serial tissue microarray sections. The slides were deparaffinized and rehydrated. The EnVision FLEX Target Retrieval Solution, Low pH (50x) (Dako, North America Inc, CA, USA) combined with EnVision FLEX Wash Buffer (20x) was used. Blocking solution was applied to all slides for 10min, followed by incubation for 1 h using the corresponding monoclonal antibody at room temperature (25°C). Following incubation with the secondary antibody for 10 min, diaminobenzidine-tetrahydrochloride-DAB (substrate-Chromogen Solution -0.03%) containing 0.1% hydrogen peroxide was applied as a chromogen and incubated for 5min. Sections were counterstained and slides were counterstained for 5 min with Hematoxylin, dehydrated and cover-slipped. For negative control slides, the primary antibody was omitted. IHC protocol was performed using an automated staining system. Membranous predominantly and cytoplasmic staining was considered acceptable for the markers, according to manufacturers' data sheets. Colon cancer tissue sections expressing the protein and normal-appearing colon epithelia were used as control groups, respectively. A conventional (qualitative) assay for scoring the PD-L1 expression patterns was applied. According to the manufacturer's guidelines, Tumor Proportion Score (TPS) reflects the percentage of viable tumor cells showing partial or complete membrane staining at any intensity. PD-L1 score <1% is characterized as negative, whereas ≥1 is categorized as positive (overexpression of the marker).

Digital image analysis assay (DIA)

PD-L1 protein expression levels were evaluated quantitatively by calculating the corresponding staining intensity levels (densitometry evaluation) in the stained RCC malignant epithelia. We implemented DIA using a semi-automated system (hardware: Microscope CX-31, Olympus, Melville, NY, USA, Digital camera Sony, Tokyo, Japan; Windows XP/NIS-Elements Software AR v3.0, Nikon Corp, Tokyo, Japan). Areas of interest per tissue section were identified (5 optical fields at ×400 magnification) and filed in a digital database as snapshots. Measurements were performed by designing and applying a specific macro (mainly membranous and sub-membranous cytoplasmic expression for tumor cells, according to manufacturer's datasheet for monoclonal mouse anti-PD-L1, clone 223C3 Dako, North America Inc, CA, USA). Based on an algorithm, normal microscopically tissue sections (control) were measured independently and compared to the corresponding values in malignant tissue sections. A broad spectrum of continuous grey scale values (0-255) at the RedGreenBlue (RGB) analysis was available for discriminating different protein expression levels (Figure 1). Immunostaining intensity values decreasing to 0 represent a progressive overexpression of the marker, whereas values increasing to 255 show a progressive loss of its staining intensity. Total results DIA of values are demonstrated in Table 1.

Statistics

Statistical analysis was performed using IBM SPSS Statistics 21 (SPSS Inc, Chicago, IL, USA) software package for Windows. All of the reported p values were two-sided. Association between the two variables (conventional and digitized PD-L1 evaluation methods) was provided by kappa analysis. Total IHC results and correlation are described in Table 1.

Results

According to the DIA procedure, PD-L1 protein expression demonstrated differences in the examined RCC tissue specimens. Negative or loss of its expression was observed in 92

cases (92%), in 2 (2%) of them moderate levels were detected, whereas 6 (6%) were characterized by strong (high) expression. Based on the TPS evaluation, 8 (8%) cases were characterized as positive, whereas the rest of them 92 cases (92%) as negative. Interestingly, kappa analysis revealed a high level of overall correlation between qualitative and quantitative based assays (kappa=0.94). Based on their histological subtypes combined with TPS/DIA evaluation assays, clear cell carcinomas demonstrated PD-L1 positive/ high overexpression in 7/5 out of 75 cases, papillary carcinomas in 1/1 out of 13 cases, whereas chromophobe carcinomas 0/0 in out of 12 cases, respectively.

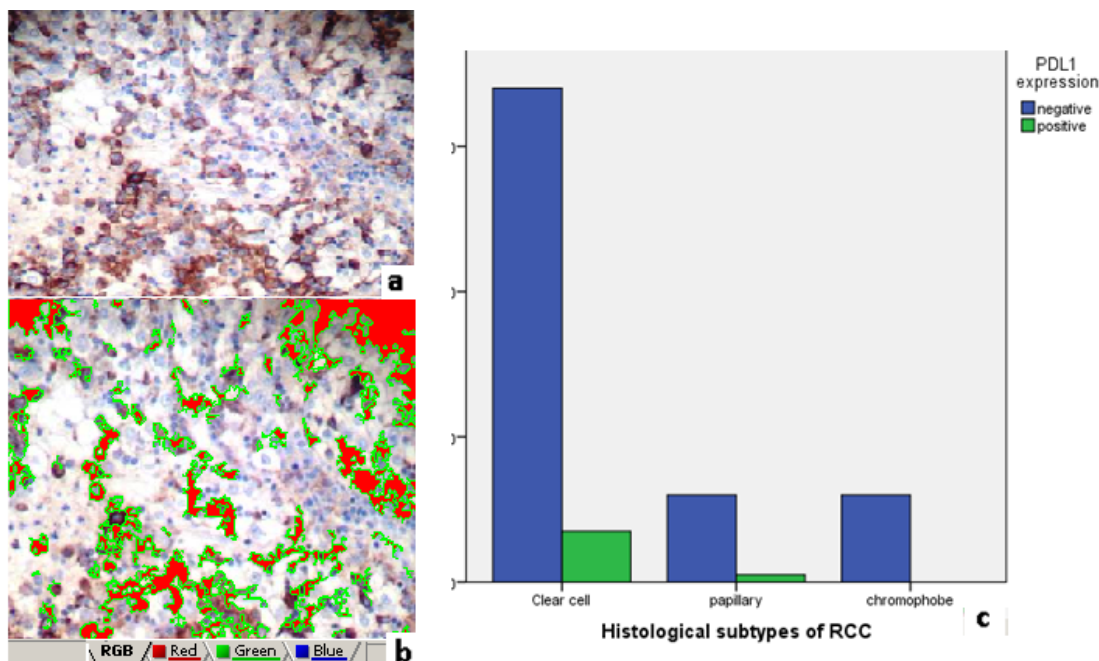


Figure 1. a: PD-L1 overexpression (positive) in a case of RCC according to tumor proportion score (TPS) conventional evaluation assay. **b:** The same case evaluated by digital image analysis (DIA) assay. Green signals and reddish areas represent different high protein levels (original magnification 100x, DAB stain). **c:** Histogram of PD-L1 protein expression classification by TPS/ DIA combined evaluation (negative to positive) based on histologic type categorization (clear cell RCC, papillary RCCs, chromophobe RCC).

Table 1. Comparative conventional and digitized total PD-L1 IHC results

RCC (n=100)	PD-L1 expression			Kappa value
	High*	Moderate*	Low-Negative**	
TPS	8/100 (8%)		92/100 (92%)	0.94
DIA*/**	6/100 (6%)	2/100 (2%)	92/100 (92%)	

RCC: renal cell carcinomas, TPS: tumor proportion score, DIA: digital image analysis.
 Moderate and High expression: staining intensity values ≤137 (spectrum between 109 and 137).
 Low/Negative expression (loss of expression): staining intensity values >140 (spectrum between 141 and 180).
 */** DIA High/Moderate correspond to TPS positive, Low/Negative correspond to TPS negative.
 kappa value: TPS vs DIA

Discussion

Besides targeted therapeutic strategies, novel immunotherapeutic regimens that motivate the immune system response to detect and destroy cancerous cells have been inserted in management of cancer patients. Nivolumab and pembrolizumab represent examples of anti-PD-1 antibodies [9]. These agents have been already tested experimentally or clinically in a broad spectrum of malignancies as first line PD-1/PD-L1 checkpoint blockade therapy including oral cancer, gastric cancer, hepatocellular carcinoma, RCC, esophageal cancer, pancreatic cancer, ovarian cancer, and bladder cancer [10-13]. Breast carcinoma, Merkel cell carcinoma, lung cancer, colorectal cancer, and melanoma are also histo-targets for immunotherapy. Different PD-L1 overexpression patterns are associated with altered response rates to mAbs and prognosis in the corresponding patients.

In the current study we analyzed PD-L1 protein in RCC. We observed that the majority of the examined malignant tissue sections demonstrated reduced or loss of their protein expression correlated to histological type (clear cell and also papillary variants). We also observed a fine correlation result comparing conventional and also digitized assays for categorizing PD-L1 protein expression levels in the examined malignancies. Concerning immunotherapeutic strategies in RCCs, a variety of agents has been applied and their efficacy is under investigation including nivolumab/ atezolizumab combined with cabozantinib (TKIs), ipilimumab (anti-cytotoxic T-lymphocyte) and also bevacizumab (anti-VEGF) agents [14]. Similarly, a clinical randomized phase 2 study based on atezolizumab single or combined with bevacizumab (anti-VEGF) versus sunitinib regimens in metastatic RCC patients revealed the impact of specific genetic signatures that modify their response rates [15]. Interestingly, another molecular study reported a strong correlation between cytotoxic T-cells/PD-L1 expressions

with poor survival rates. They also focused on the importance of positive expression for a successive response to immune checkpoint inhibitors-based therapy and their potential prognostic and predictive role in them [16]. Mixed regimens for experimental targeted therapy in RCC include anti-PD-1 agents combined also with anti-inflammatory proteins. A study based on a high dose interleukin-2 (HD IL-2) following treatment with PD-1 and PD-L1 inhibition showed a strong antitumor activity in metastatic melanoma and RCC patients as a promising combination for immune checkpoint blockade and cytokine therapy, respectively [17]. Concerning the correlation between histological features of RCCs and PD-L1 overexpression, some studies reported a strong association with advanced grade and stage in the corresponding patients [18]. Furthermore, an increased incidence of disease recurrence was also observed.

In the current study we implemented a DIA assay in order to compare the results of conventional PD-L1 scoring with the corresponding levels of its immunostaining intensity. We observed the benefits of DIA, as an innovative, accurate and fast technique in estimating objectively protein expression patterns in a variety of markers, according with our published experience [19].

In conclusion, the role of PD-L1 aberrant expression in RCCs seems to be crucial in order eligible patients for specific immunotherapies should be selected, although its overexpression is detected in low rates in RCC - especially in the clear RCC histological variety. Due to the increasing need for novel predictive/prognostic biomarkers detection in the malignancies including RCCs tumor mutational burden, profiles of tumor infiltrating lymphocytes, molecular subtypes, and PD-L2 combined with PD-L1 are a very promising approach [20].

Conflict of interests

The authors declare no conflict of interests.

References

1. Sunshine J, Taube JM. PD-1/PD-L1 inhibitors. *Curr Opin Pharmacol* 2015;23:32-8.
2. Sharpe AH, Wherry EJ, Ahmed R, Freeman GJ. The function of pro-programmed cell death 1 and its ligands in regulating autoimmunity and infection. *Nat Immunol* 2007;8:239-45.
3. Caldwell C Jr, Johnson CE, Balaji VN, Balaji GA, Hammer RD, Kannan R. Identification and Validation of a PD-L1 Binding Peptide for Determination of PDL1 Expression in Tumors. *Sci Rep* 2017;7:13682-7.
4. Okazaki T, Honjo T. PD-1 and PD-1 ligands: from discovery to clinical application. *Int Immunol* 2007;19:813-24.
5. Tumei PC, Harview CL, Yearley JH et al. PD-1 blockade induces responses by inhibiting adaptive immune resistance. *Nature* 2014;515:568-71.

6. Rini BI, Campbell SC, Escudier B. Renal cell carcinoma. *Lancet* 2009;373:1119-32.
7. Patard JJ, Pignot G, Escudier B et al. ICUD-EAU international consultation on kidney Cancer 2010: treatment of metastatic disease. *Eur Urol* 2011;60:684-90.
8. Moch H, Humphrey PA, Ulbright TM, Reuter VE. WHO Classification of Tumours of the Urinary System and Male Genital Organs. (4th Edition). Lyons, France: IARC. WHO Classification of Tumours 2016;8:14-43.
9. Xue SA, Stauss HJ. Enhancing immune response for cancer therapy. *Cell Mol Immunol* 2007;4:173-84.
10. Ragos V, Mastronikolis N, Tsiambas E, Fotiades P. PD-L1 in oral squamous cell carcinoma. *JBUON* 2018;23:835-6.
11. Wang X, Teng F, Kong L, Yu J. PD-L1 expression in human cancers and its association with clinical outcomes. *Onco Targets Ther* 2016;9:5023-39.
12. Topalian SL, Hodi FS, Brahmer JR et al. Safety, activity, and immune correlates of anti-PD-1 antibody in cancer. *N Engl J Med* 2012;366:2443-54.
13. Ochoa CE, Joseph RW. Nivolumab in renal cell carcinoma: current trends and future perspectives. *J Kidney Cancer VHL* 2018;5:15-8.
14. Atkins MB, Tannir NM. Current and emerging therapies for first-line treatment of metastatic clear cell renal cell carcinoma. *Cancer Treat Rev* 2018;70:127-37.
15. McDermott DF, Huseni MA, Atkins MB et al. Clinical activity and molecular correlates of response to atezolizumab alone or in combination with bevacizumab versus sunitinib in renal cell carcinoma. *Nat Med* 2018;24:749-57.
16. Stenzel PJ, Schindeldecker M, Tagscherer KE et al. Prognostic and Predictive Value of Tumor-infiltrating Leukocytes and of Immune Checkpoint Molecules PD1 and PDL1 in Clear Cell Renal Cell Carcinoma. *Transl Oncol* 2020;13:336-45.
17. Buchbinder EI, Dutcher JP, Daniels GA et al. Therapy with high-dose Interleukin-2 (HD IL-2) in metastatic melanoma and renal cell carcinoma following PD1 or PDL1 inhibition. *J Immunother Cancer* 2019;7:49-57.
18. Kumar B, Ghosh A, Datta C, Pal DK. Role of PDL1 as a prognostic marker in renal cell carcinoma: a prospective observational study in eastern India. *Ther Adv Urol* 2019;11: 1756287219868859.
19. Mastronikolis NS, Tsiambas E, Papadas TA et al. Deregulation of PTEN Expression in Laryngeal Squamous Cell Carcinoma Based on Tissue Microarray Digital Analysis. *Anticancer Res* 2017;37:5521-4.
20. Zhu J, Armstrong AJ, Friedlander TW et al. Biomarkers of immunotherapy in urothelial and renal cell carcinoma: PD-L1, tumor mutational burden, and beyond. *J Immunother Cancer* 2018;6:4-10.